

THE FUNDUS OCULI OF BIRDS

CASEY ALBERT WOOD

To
Professor Meynard M. Metcalf,
With the Compliments of
The Author.



THE FUNDUS OCULI
OF BIRDS

THE FUNDUS OCULI OF BIRDS
ESPECIALLY AS VIEWED BY THE
OPHTHALMOSCOPE

*A Study in
Comparative Anatomy and Physiology*

BY
CASEY ALBERT WOOD

*Illustrated by 145 drawings in the text; also by sixty-one
colored paintings prepared for this work by
ARTHUR W. HEAD, F. Z. S.
London*

CHICAGO
THE LAKESIDE PRESS
1917

COPYRIGHT, 1917, BY
CASEY ALBERT WOOD

TABLE OF CONTENTS

CHAPTER	PAGE
I. INTRODUCTION	5
II. SUMMARY OF CONCLUSIONS	7
III. COLLECTION, SELECTION AND PREPARATION OF MATERIAL BIBLIOGRAPHY	8
IV. A REVIEW OF THE ANATOMY AND PHYSIOLOGY OF THE ORGANS AND TISSUES SEEN IN THE FUNDUS OCULI OF THE BIRD	12
V. OPHTHALMOSCOPY, OR THE EXAMINATION THROUGH THE PUPILS, IN ANIMATE SPECIMENS, OF THE INTERIOR OF THE VERTEBRATE EYE BY MEANS OF THE OPHTHALMOSCOPE	26
VI. OPHTHALMOSCOPY OF THE FUNDUS IN LIVING BIRDS:	33
A. The Eye-ground in General	36
B. The Pecten and Optic Disc	38
C. The Macular Regions, Foveæ and other Areas of Acute Vision	38
D. The Fundal Bloodvessels, the Opaque Nerve Fibres, the Choroid and the Retina	38
E. Photography of the Fundus in Living Birds	44
VII. MACROSCOPIC APPEARANCES OF THE FUNDUS OCULI OF BIRDS IN PREPARED SPECIMENS	49
Photography of the Fundus in Prepared Eyeballs	61
VIII. EFFECTS OF DOMESTICATION ON THE FUNDUS OCULI OF WILD SPECIES OF BIRDS	62
IX. THE OPHTHALMOSCOPIC AND MACROSCOPIC APPEARANCES OF THE FUNDUS OCULI IN VARIOUS ORDERS OF BIRDS.	
A. Ratitæ	64
B. Carinatae	68
X. CLASSIFICATION OF THE OCULAR FUNDI OF BIRDS	112
XI. THE OCULAR FUNDUS OF BIRDS IN ITS RELATION TO A CLASSIFICATION OF AVES	114
XII. THE RELATIONS OF REPTILIAN TO AVIAN FUNDI	116
XIII. COLORED DRAWINGS OF THE FUNDUS OCULI OF BIRDS Colored Drawings of the Fundus Oculi of Reptiles	119 178

CHAPTER I

INTRODUCTION

ALTHOUGH the ophthalmoscopic and naked-eye appearances of the fundus oculi have been thoroughly described and depicted by other writers in many of the Mammals — especially in Man — yet very little attention has been paid to the remarkable and interesting eyegrounds of the animal that exhibits the highest and most varied types of vision — the Bird. The meagre accounts given by even modern writers of the appearances of the avian fundus are probably due either to their quoting the ill-formed opinions of early observers or to their ignorance of the proper use of the ophthalmoscope; facility in the employment of this instrument is acquired only after long practice, and it is not to be expected that every zoologist can make his own notes of fundus pictures.

The main purpose of this study is to furnish such a description of the intraocular appearances and the methods employed in viewing them as will enable other ophthalmologists and zoologists to further this study by examining the eyegrounds of Birds that come under their observation.

The eyes of some representative of (practically) all the Orders of Birds and most of their backgrounds have been examined by the writer; and are more or less fully described and illustrated in this Atlas. Moreover, some of the more important species were examined not only ophthalmoscopically before death but macroscopically afterwards. In addition to these methods of investigation extensive microscopic examinations of the tissues were carried on, especially in conjunction with Professor J. R. Slonaker.

That this research might have a broader and more useful application the writer has also ex-

amined the ocular fundi of a number of species of other vertebrate orders. A brief comparison will be made between a few of these findings and those discovered in the avian fundi.

The writer is much indebted to many colleagues and other friends for assistance in carrying out the present investigations, which he began more than ten years ago. Among these are the officials of the London Zoological Society, Mr. Chas. H. Hicks in particular; Professors James R. Slonaker and Frank W. Weymouth of Stanford University; Mr. C. W. Beebe, of the New York Zoological Park; Mr. Cy de Vry of Lincoln Park, Chicago, and the officers of the Golden Gate Park, San Francisco, California; and Mr. Arthur W. Head (the well-known artist) who has so ably depicted and reproduced in this work the avian fundi therein described. His thanks are also due to Mr. C. H. Kennedy, now of Cornell University, who has drawn so faithfully most of the black and white figures in Chapter VII, illustrating the macroscopic findings of preserved specimens. He is also under obligations to Mr. Douglas Fyfe, who made for him a collection of birds' heads in the United States of Colombia; to Lieut.-Col. J. W. Barrett of Melbourne, who performed the same service in Australasia, and to a number of Californians, among them Messrs. Van Rossem, Wright M. Pierce, R. H. Beck, Lieut. Casey Hayes (U. S. Army) and the Managers of the Cawston Ostrich Farm and Bentley Ostrich Farm, who furnished him with abundant material from the Pacific Coast. He also owes his thanks to Professor J. Grinnell for the loan of material from the Museum of Vertebrate Zoology of the University of California; to Dr. T. A. Woodruff

who assisted him in his earlier ophthalmoscopic studies of Birds, and to Professor Henry B. Ward of the University of Illinois for assistance in reading the proof sheets as they were passing through the press.

The systematic classification employed for the purposes of this work is that of Bowdler

Sharpe's Hand-List of Genera and Species (London, 1909), except that in mentioning North American Birds the specific names on the Check List of the American Ornithological Union (1910) has been used.

CASEY A. WOOD.

Chicago, 1917.

CHAPTER II

SUMMARY OF CONCLUSIONS

1. The examination of the eyes of Birds is a study of the most advanced and most varied apparatus for the highest expression of vision known to any vertebrate class.

2. The examination of the interior of the avian eye through the pupil of animate species (ophthalmoscopy) gives valuable information regarding the function of sight in general and of the eyesight of Birds in particular.

3. The fundus oculi, or background of the eye, is plainly seen in its normal relations when viewed during the life of the species, and in many respects this form of exploration is superior to methods carried out on prepared or preserved eyeballs.

4. The parts and organs visible by the ophthalmoscope in the eye of the Bird are in particular (*a*) the concavity or general chorio-retinal surface of the posterior half of the eye; (*b*) the pecten; (*c*) the optic nerve entrance; (*d*) the areas of acute vision; (*e*) the fundal bloodvessels; (*f*) opaque nerve fibres.

5. The appearances of these organs and tissues furnish entirely different, colored fundus pictures, and it is frequently possible to recognize a species by viewing its fundus oculi.

6. The fundus oculi of Birds exhibits a great variety of areas of distinct vision, and these correspond closely to the habits and habitat of these animals — especially their methods of obtaining food, of escape from enemies, of migration, of reproduction, etc.

7. In spite of recent advances in that direction, attempts to reproduce the colored (ophthalmoscopic) appearances of the fundus by photography have so far failed.

8. The macroscopic appearances of the ocular fundus resulting from an examination of preserved specimens have a value in this research all their own; for certain forms of examination it is inferior to ophthalmoscopy, for others superior; but it gives no indication of the color tones of the background so well shown by the ophthalmoscope.

9. As in ophthalmoscopy, attempts to reproduce the details of the eyeground of preserved specimens have so far given unsatisfactory results.

10. The use of the microscope in examining the avian eye, and especially serial sections of the parts, is occasionally required to settle anatomical questions that neither ophthalmoscopy nor macroscopy can elucidate.

11. Domestication or prolonged captivity brings about abnormal changes in the eyeground of Birds, so that only healthy, wild specimens should be utilized in this or a similar research.

12. As the colored pictures seen in the fundi of healthy wild birds are invariable in species these appearances may well furnish data for a classification of Aves ranking in importance with other taxonomic indications.

13. Ophthalmoscopy throws light on the origin of Birds, or at least on their relation to that Sauropsidian ancestry which they hold in common with Reptilia.

14. In future no report upon a particular avian species can be held complete that ignores the visual apparatus, and especially the appearances of the fundus oculi as shown by the ophthalmoscope.

CHAPTER III

COLLECTION, SELECTION AND PREPARATION OF MATERIAL BIBLIOGRAPHY

ALTHOUGH the eyes of many hundreds of species have been examined by the writer ophthalmoscopically and otherwise his purpose in this work is to describe as nearly as may be the conditions found in the fundi of such birds (especially of living birds) as are most likely to be useful in a study of comparative ophthalmology. To this end he has confined his attention to *normal wild species* and has studiously avoided domesticated, domestic or otherwise abnormal birds. It is in these more or less tame species that numerous variations from the normal eye-ground are seen; consequently it is quite impossible to deduce from fundus examinations of tame or diseased birds any physiological conclusions worthy the name. This choice of normal, wild birds has added somewhat to the difficulties of the task. Domesticated animals are the most accessible and the easiest to examine; but any one who has made a study of the matter will soon discover that, as in Man, specific variations of the fundus picture in domesticated species are so numerous as to render it impracticable for any one, even in a long lifetime, to make a complete investigation of the ocular background in more than a few of these animals. Even in an examination of the eyes of birds in a public aviary the length of time the individual has been held in captivity is of importance from the ophthalmoscopic standpoint; recently caught, healthy specimens are always preferable to birds that have been long confined and exposed to the unwonted surroundings of cage life.

In addition to such wild birds as are accessible in private collections or that are to be

found in every zoological garden or park, the field naturalist may himself, or by proxy, trap or shoot the specimens he needs. Many birds can be procured through collectors employed by Museums and Colleges, either as duplicates or in conjunction with the collectors' other work. The writer, armed with a proper license, has made several collecting trips of this kind and has in this way been able to examine the fundi of many disabled or recently killed birds.

A self-luminous ophthalmoscope (see page 30) and a large opaque, black umbrella are the most useful implements for field work. A few minutes before and after the death of the specimen one finds the pupil widely dilated, so that the ocular interior can be readily explored. Birds that are uninjured or merely "winged" are placed in a box or cage and carried to the laboratory or dark room, there to be examined ophthalmoscopically at greater leisure. See Chapter VI.

[For *macroscopic studies* of the fundus in prepared material the bird's head should be placed in a preserving fluid — preferably Perenyi's — a few minutes after death. In collecting specimens the following rules should be observed:

1. When possible, secure at least three heads of each species.
2. Immediately after death incise the skin about the neck well below the head and carefully remove the skin from the head by pulling it forward, wrong side out, over the head, cutting the thin membranes about the eyes (at the margin of the orbit) without injury to the eyeballs. If the eyes or their appendages are cut or injured in any way the specimen is rendered useless.

Diseased or injured eyes are also of no use in this investigation. 3. After skinning, sever the head from the body by decapitation close to the base of the skull. 4. Label the head by tying a string — to which a label is attached — securely through the nostrils on the beak. This label should bear, *written distinctly with a hard pencil*, both the common and zoological name of the bird, the date and locality of collection, as well as the name and address of the collector. Heads of the same species should be numbered serially (1, 2, 3, etc.). 5. The foregoing operations should occupy as brief a time as possible. The head should then be immersed in a quantity of fresh Perenyi's fluid equal to twenty times the volume of the head. Fruit jars are convenient containers for this purpose. Formula of Perenyi's Fluid: 10% nitric acid in clean water (10 acid to 90 water), 4 parts; 95% (commercial grain) alcohol, 3 parts; 0.5% chromic acid in clean water (grm. 0.50 acid to 100 cc. water, 3 parts. After a few minutes this mixture turns a violet color. It may be kept in bulk indefinitely if well corked. 6. Leave the heads in Perenyi's fluid until the hardest bones of the skull become soft and pliable when touched with a scalpel. The time required will depend upon the size of the head. The following periods of immersion will usually be sufficient: Small heads, as sparrow, robin, etc., 24 hours; medium sized heads, as the crow, 36 hours; large heads, as the owl, 48 hours; extra large heads, as the ostrich, 3 to 4 days. 7. After decalcification in Perenyi's fluid the heads should be treated with the following percentages of commercial grain alcohol. In each case use approximately 20 volumes of the alcohol solution to one volume of the head. The best results are obtained by using fresh alcohol solution for each head. *Leave the heads in each of these alcohols for the same period they were immersed in Perenyi's fluid.* 70% alcohol is made by mixing 70 volumes of 95% (commercial grain) alcohol with 25 volumes of clean water; 80% alcohol, made by mixing 80 volumes of 95% alcohol with 15 volumes of clean water; 95% (commercial grain) alcohol. 8. After treatment with the last alcohol solution

the heads may be packed in a fruit jar sufficiently large to hold them, covered with 95% alcohol and carefully sealed to prevent leakage.

Should the eyeball lose its rotundity, or "cave in" anywhere, the defect may be sometimes remedied by injecting 70% alcohol, by means of a hypodermic syringe, into the vitreous chamber.

Prepared in this way the bones of the skull and the sclerotic plates are so softened that sections of them can readily be made, while the walls of the eyeball are so hardened that they can be bisected at the equator with a sharp razor and the anterior segment removed, with the cornea, lens and vitreous. The parts behind, in the posterior half of the globe, constituting the *fundus oculi*, *eyeground* or *background of the eye*, remain *in situ* and can be readily examined.

Although *injection of the arteries of the avian fundus* is not as useful as in those eyes in which there are retinal vessels, yet occasionally the choroidal bloodvessels and (perhaps) the pecten are affected by it and thus rendered more visible. In that case preferably the gelatine-carmine mass of Ranvier is injected by way of the carotid arteries.

In examining *macroscopically* the posterior segment of the eyeball a magnifying lens of 10 cm. focus may sometimes be used but the unaided eye is generally satisfactory.

On removing the hardened vitreous (by means of a mounted needle) the grayish, translucent retina should lie smoothly on the choroid when the preparation is a success. Retinal wrinkling occurs not infrequently in some part of the eyeground, in which case it may give rise to errors in determining the presence or absence of some of the areas of distinct vision, etc. A well preserved eyeball furnishes satisfactory material for many years.

For *microscopic sections* a window is cut in the globe in the plane of the desired sections, the vitreous removed without injury to the choroid and retina and the cavity filled (by immersion) with celloidin. However, as the minutiae of this form of investigation is outside the scope of this work the writer must refer the reader to laboratory textbooks on the subject.

BIBLIOGRAPHY

In addition to the well-known manuals on ornithology, ophthalmology and biology the writer has had most help in this investigation from the following:

- ABELSDORFF, G., Über das Verhalten des Pektens bei der Akkommodation des Vogelauges. *Archiv f. Vergleichende Ophthalmologie*, 1 Jahrgang, III Heft, No. 3, pp. 290-292, 1910.
- ABELSDORFF-WESSELY., Vergleichend physiologische Untersuchung über den Flüssigkeits-Wechsel des Auges der Wirbelthierreihe. 1^{te}, Theil, Vögel, *Archiv für Augenheilkunde*, Vol. 64, pp. 65-124, 1909.
- AUDUBON, J. J., Ornithological Bibliography, Vol. 2, pp. 33-47, 1835.
- BAYER, JOS., Bildliche Darstellung des gesunden und kranken Auges unserer Haustiere, Wien, 1892.
- BEAUREGARDE, M., Note sur l'étude ophtalmoscopique du Peigne de l'oeil des Oiseaux, *Compt. Rend. et Mém. Soc. de Biologie*, Paris 6 ser., T. 2, pp. 132-136, 1875.
- BEDDARD, FRANK E., The Structure and Classification of Birds, London, 1898.
- BEEBE, C. WILLIAM, Bird Portraits, *Birds and Nature Magazine*, Vol. 1, No. 1, p. 12, May, 1907.
- BEER, THEODOR, Studien über die Akkommodation des Vogelauges, *Pflüger's Archiv*, LIII, pp. 175-237, 1893.
- BELOGOWY, J., Zur Entwicklung der Kopfnerven der Vögel, *Bull. Soc. Natural*, Moscou, p. 177, 1908.
- BERND, ADOLF HUGO, Die Entwicklung des Pecten im Auge des Hühnchens aus den Blättern der Augenblase. Inaugural-Dissertation, Bonn, 1905.
- BRUECKE, E., Über den Musculus Cramptonianus und über den Spannmuskel der Choroidea, *Mueller's Archiv f. Anat. u. Phys.*, p. 370, 1846.
- BRUHIN, TH. A., Die Iris der Vögel insbesondere der Raub, Sumpf und Schwimm Vögel der deutschen Fauna, als unterschiedenes Merkmal der Arten, des Alters und Geschlechts, *Zool. Garten*, p. 290, 1870.
- CAMERON, JOHN, On the development of the layers of the retina in the chick after the formation of the optic cup, *Proc. Royal Soc. of London*, Vol. 70, p. 84-86, 1902.
- CANFIELD, WILLIAM B., Vergleichende anatomische Studien über den Accommodationsapparat des Vogelauges, *Arch. mikr. Anat.*, Vol. 28, p. 121-70, 1886.
- CARPENTER, F. W., The Ciliary Ganglion of Birds, *Folia Neuro-Biologica*, Vol. 5, p. 738, 1911.
- CHIEVITZ, Über das Vorkommen der Area centralis retinae in den vier höheren Wirbeltierklassen, *Archiv für Anat. und Physiol. Anat.*, pp. 311-334, 1891.
- COLE, LEON J., Have all Eyes the Power of Forming Images? *American Academy of Arts and Sciences*, Vol. 42, No. 16, January, 1907.
- COLLIN, R., Premiers études du développement du muscle sphincter de l'iris chez les oiseaux, *Soc. Biol. Paris*, Vol. 55, p. 1055-56, 1903.
- COLLINS, E. TREACHER, The Anatomy and Pathology of the Eye, *Lancet*, Feb. 17 and 24, 1900.
- COUES, ELLIOTT, Bird's-Eye Views, *American Naturalist*, Vol. 2, No. 10, p. 505, Dec., 1868.
- DENNISSENKO, G., Über den Bau und die Funktion Kammes (Pecten) im Auge der Vögel, *Arch. f. mikrosk. Anat.*, Vol. 19, p. 733-41, 1881.
- DIXON, GEO. SLOAN, Stereoscopic macroscopical Eye specimens in glycerine jelly under glass, *Archives of Ophthalmology*, Vol. 37, p. 40, 1908.
- DOGIEL, A. S., Die Retina der Vögel, *Arch. mikr. Anat.*, Vol. 44, p. 622-48, 1895.
- EDINGER, L., A. WALLENBERG and G. M. HOLMES, Untersuchungen über die vergleichende Anatomie des Gehirnes, 5. *Untersuchungen über das Vorderhirn der Vögel*, 1903.
- EIGENMANN, Cave (Blind) Vertebrates of America, *Carnegie Institution of Washington*, 1909.
- FRANZ, V., Der Facher im Auge der Vögel, *Verh. Dtsch. Zool. Ges.*, 1908
- , Das Vogelauge, *Zool. Jahrb., Abt. f. Anat.*, Vol. 28, pp. 73-282, 1909
- , Bau des Eulenauges und Theorie des Teleskopauges, *Biol. Centralbl.*, XXVII, No. 9 and 10, p. 271. Leipzig, 1907.
- , Photographien mit ultraviolettem Lichte., *Archiv f. Vergleichende Ophthalmologie*, I, Part III, No. 3, pp. 283-289, 1910.
- FRITSCH, GUSTAV, (Berlin). Über Bau und Bedeutung des Area centralis des Menschen, Berlin, 1908.
- FRORIEP, AUGUST, Die Entwicklung des Auges der Wirbeltiere, p. 138.
- FÜRBRINGER, M., Untersuch. zur Morphol. und Systematik der Vögel, Parts I and II Amsterdam, 1888.
- GADOW, HANS, Vögel. Sechster Band, IV Abteilung, der H. G. Bronn'schen *Klassen und Ordnungen des Tier-Reichs*, Leipzig, 1912.
- GASKELL, W. H., The Origin of Vertebrates, London, 1908.
- GEGENBAUR, CARL, Vergleichende Anatomie der Wirbeltiere, Leipzig, 1898.
- GREENE, W. T., Parrots in Captivity, 3 Vols.
- HEINE, L., Physiologisch-Anatomische Untersuchungen über die Accommodation des Vogelauges. *Arch. f. Ophthalm.*, Vol. 45, pt. 3, p. 469. 1898.
- HERRICK, C. J., Illustrations of the surface anatomy of the brain of certain birds. *Jour. Comp. Neur. Psych.*, Vol. 3, 1893.
- HESS, C., Vergleichende Physiologie des Gesichtssinnes, 1912.
- HOFFMANN, F. W., Zur vergleichenden Anatomie der Lamina cribrosa nervi optici und einiger angrenzenden Verhältnisse. *Archiv für Ophthalmologie*, XXIX, 2, p. 45-72, 1883.

- ISCHREYT, C., Zur vergleichenden Morphologie des Entenauges, *Archiv f. Vergleichende Ophthalmologie*, III, No. 9, p. 39, 1912.
- JEGERON, J., Über den Einfluss des Sympathicus auf die Vogelpupille, *Arch. f. ges. Physiol.*, Vol. 41, part 7-8, 1887.
- JOHNSON, GEORGE LINDSAY, Contributions to the Comparative Anatomy of the Mammalian Eye, Chiefly based on ophthalmoscopic examination. *Phil. Trans. Royal Society of London*, 1901.
- KALT, M. E., Anatomie et Physiologie comparées, Section of the *Encyclopédie française d'ophtalmologie*, p. 585, Vol. 2, 1905.
- KRAUSE, W., Über die Retinazapfen der nächtlichen Tiere, *Archiv für mikroskopische Anatomie*, XIX, p. 309-314, 1881.
- LANGLEY, Z. N., and ANDERSON, H. K., The Action of Nicotin on the Ciliary Ganglion and on the Endings of the Third Cranial Nerve. *Jour. Physiol.*, Vol. 13, pp. 460-468, 1892.
- LENHOSSÉK, M., Das Ganglion Ciliare der Vögel, *Arch. f. Mikros. Anat. und Entwickl.*, Vol. 76, Part 4, pp. 745-769, 1911.
- LEPLAT, GEORGES, Contribution a l'étude de l'accommodation chez les oiseaux. *Annales d'oculistique*, p. 404, 1912.
- LEUCKART, RUDOLPH, Organologie des Auges; Vergleichende Anatomie, *Graefe-Saemisch Handbuch der Gesamten Augenheilkunde*, 1^{te} Edition, II, pp. 145-301, 1876.
- LOEWENTHAL, N., Beitrag zur Kenntnis der Harder'schen Drüse bei den Säugetieren. *Anatom. Anzeiger*, Vol. 7, pp. 546-556, 1892.
- MEVES, WILHELM, Die Grössen und Farben der Augen der Europäischen Vögel sowie der in der paläarktischen Region vorkommenden Arten in systematischer Ordnung nach Carl J. Sundevall's Versuch einer natürlichen Aufstellung der Vogelklasse. 2nd Edition, Jan., 1911.
- MEYER, H., Über einige pharmakologischen Reaktionen der Vogel und Reptilieniris. *Archiv f. experiment. Path. und Pharmakologie*, Vol. 32, 1893.
- MÜLLER, H., Ges. und hinterl. Schriften über das Verhandensein zweier Foveae in der Netzhaut vieler Vogelaugen, p. 142.
- NUSSBAUM, M., Die pars ciliaris retinae des Vogelauges. *Graefe-Saemisch Handbuch der Ges. Augenllk.* 2nd Edition; and *Archiv f. mik. Anat. und Entwicklungesch.*, Vol. 57, pp. 347-350, 1901.
- PARKER, W. K., On the Morphology of Birds, *Proceedings of the Royal Society of London*, 1887.
- PARREIDT, R., Beiträge zur Anatomie des Auges bei *Endyptes chrysocome* und zur Entwicklung des Pekten im Vogelauge, Inaugural Dissert., Leipzig, p. 28, 1901.
- PFLUGK, A. VON, Über die Accommodation des Auges der Taube, Dresden, 1912.
- PÜTTER, AUGUST, UND ANDERE. *Vergleichende Physiologie*, Jena, 1911.
- , Organologie des Auges. *Graefe-Saemisch Handbuch der Gesamten Augenheilkunde*, 1^{er} Teil, 2^{ter} Band, 10^{ter} Kapitel, 1908.
- RAMON Y CAJAL, and RICHARD GREEFF, Die Retina der Wirbelthiere. Untersuchungen mit der Golgi-Cajal'schen Chromsilbermethode und der Ehrlich'schen Methylenblaufärbung, 1894.
- SCHÄFER, G., Vergl. physiologische Untersuchungen über die Sehschärfe. *Pflüger's Archiv*, Vol. 119, p. 571, 1907.
- SHARPE, R. BOWDLER, A Hand-List of the Genera and Species of Birds. 5 Vols., Trustees of British Museum, London, 1909.
- SHUFELDT, R. W., Osteology of Birds, *Education Department Bulletin*, No. 447, University State of New York, 1909.
- SLONAKER, J. R., A comparative study of the areas of acute vision in vertebrates. *Jour. Morphology*, Vol. 13, pp. 445-502, 1897.
- TORNATOLA, Sulla membrana limitante interna della retina nei vertebrati. *Anat. Anzeiger*, Vol. 24, pp. 536-538. [1903.]
- TURNER, C. H., Morphology of the avian brain, *Jour. Comp. Neur. and Psych.*, Vol. 1, pp. 39-92, 1891.
- VIRCHOW, H., Fächer, Zapfen, Leiste, Polster, Gefässe im Glaskörperraum von Wirbelthieren sowie damit in Verbindung stehende Frage. *Merkel u. Bonnet's Ergeb. d. Anat. u. Entwicklungsgeschichte*, pp. 720-849, Vol. 10, 1900.
- WÄELCHLI, G., Zur Topographie der gefärbten Kugeln der Vogelnethzhaut, *Gräfe's Arch. für Ophthalm.*, Vol. 29, pp. 205-24, 1883.
- WAGNER, R., Beiträge zur Anatomie der Vögel, *Abhandl. bayer. Akad. Wiss. Math.-phys.*, Vol. 2, p. 270, 1837.
- WOLFF, H., [Photography of the Fundus.] *Klin. Monatsbl. f. Augenheilk.*, Oct.-Nov., p. 447, 1907.
- WOOD, CASEY A., The Eyes and Eyesight of Birds, with especial reference to the appearances of the fundus oculi; Preliminary paper, *Ophthalmology*, April, 1907.
- , Section on *Comparative Ophthalmology*; as well as section on *Birds, Eyes of*, [The former the more important] *American Encyclopedia of Ophthalmology*, pp. 2519-2763, Vol. 4, 1914; the second caption in Vol. 2, p. 979 of the same treatise.
- WYCHGRAM, E., Über das Ligamentum pectinatum im Vogelauge. *Archiv f. Vergleichende Ophthalmologie*, III, No. 9, I, p. 22, 1912.
- ZIEM, C., Geschichtliche Notiz ü. d. Fächer im Auge des Vogels. *Zeitsch. f. Psych. u. Phys. d. Sinnesorgane*, Vol. 6, p. 543.
- ZIETZSCHMANN, OTTO, Der Musculus dilatator pupillae des Vogels, *Archiv für Vergleichende Ophthalmologie*, Vol. 1, Part 1, pp. 9-19, 1909.
- , *Ellenberger's Handbuch der vergl. mikr. Anatomie der Haustiere*, p. 422, *Schorgan*; 1906.

CHAPTER IV

A REVIEW OF THE ANATOMY AND PHYSIOLOGY OF THE ORGANS AND TISSUES SEEN IN THE FUNDUS OCULI OF THE BIRD

A COMPARISON of the ocular structures in the vertebrate sub-classes shows that the posterior two-thirds of the eyeball contain practically the same organs in all, with, of course, numerous modifications of them to suit the visual requirements of a particular species.

In Vertebrates generally the fundus organs of especial interest are the *retinal and choroidal bloodvessels* (in some instances projected into the *vitreous humor*), the *choroid*, the *retina* and the *optic nerve entrance*, the last named otherwise known as the *optic disc*, *porus opticus*, *nerve-head* or *papilla*.

Although the retinal layers are generally transparent, and not visible during life, yet this is not true of all species; e.g., occasionally a certain number of translucent nerve-fibre sheaths (neurilemmata) are prolonged into the retina and variously distributed over the background of the eye, and, by means of the ophthalmoscope especially, are visible and have been described under the name medullated or "opaque" nerve fibres.

These organs and tissues will be considered in their order.

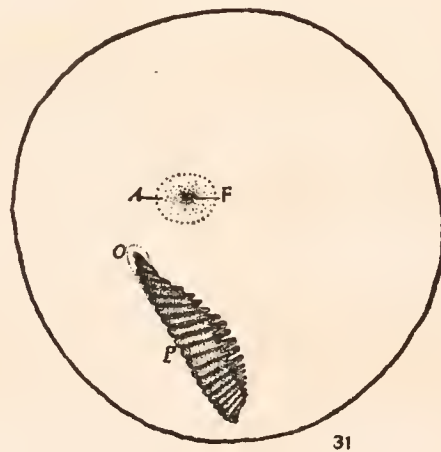


Fig. 1

The Relations of the Fundus Organs of a Young English Sparrow. A, area centralis; F, fovea; O, optic nerve entrance; P, pecten. The pecten stands almost vertical in this figure. (Wood and Slonaker.)

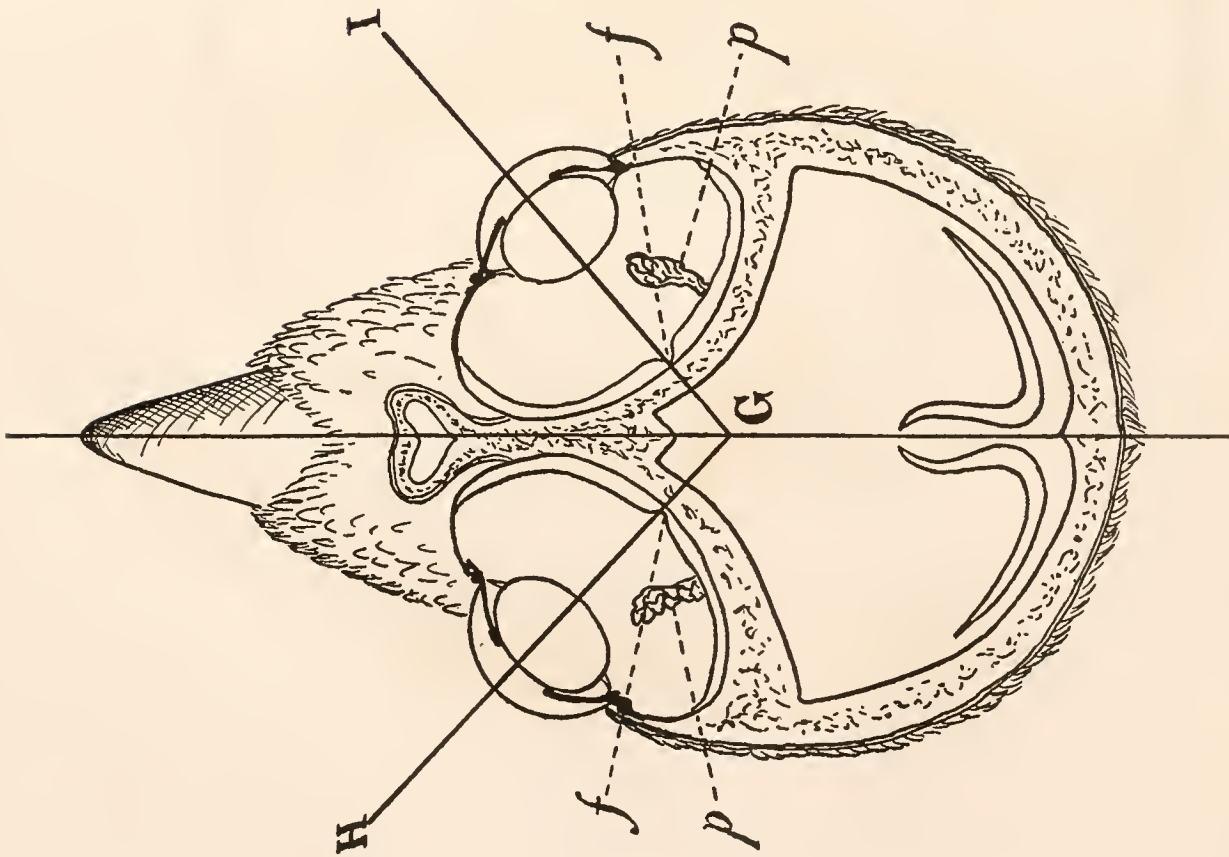


Fig. 2

The Nasal Monocular Fundus Oculi of the Chickadee—*Parus atricapillus*. (After Slonaker.) GH, GI, visual axes; *f*, fovea; *p*, pecten.

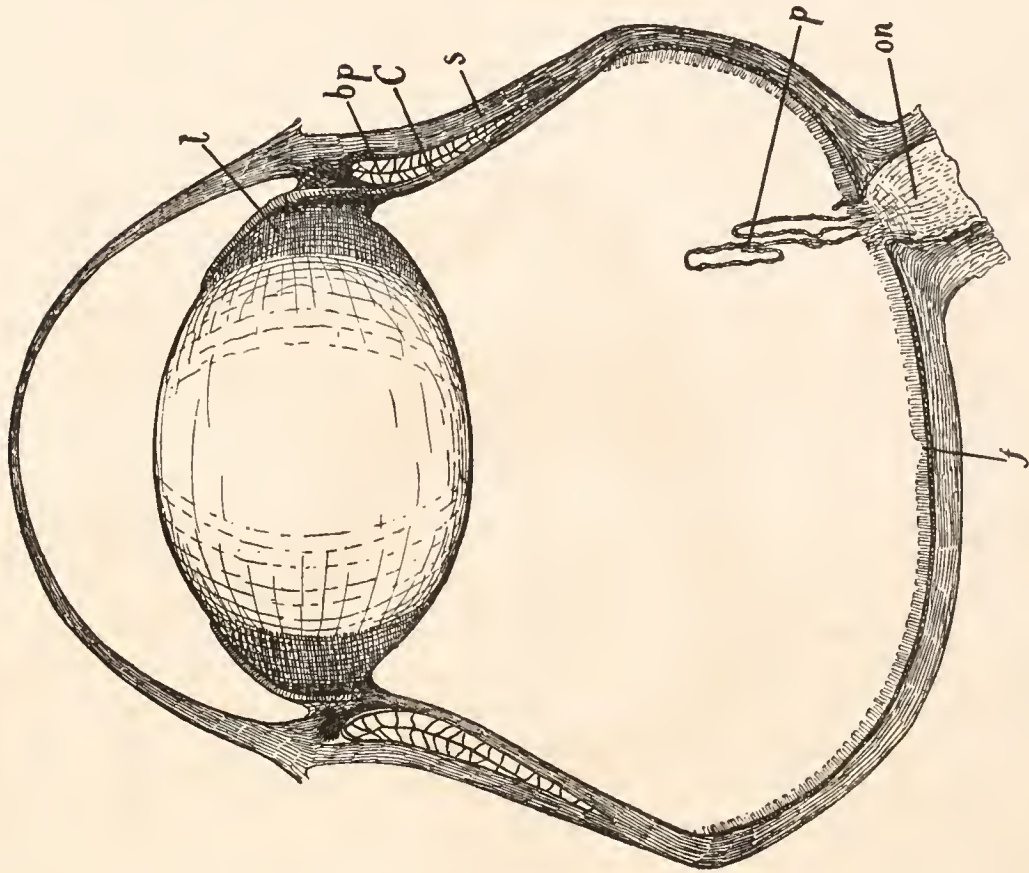


Fig. 3

Vertical Section of the Eye of the American Screech Owl—*Strix vel Megascops asio*. *l*, lens; *bp*, bony plates; *S*, sclera; *C*, Crampton's muscle; *p*, pecten; *ON*, optic nerve; *f*, macula and fovea.

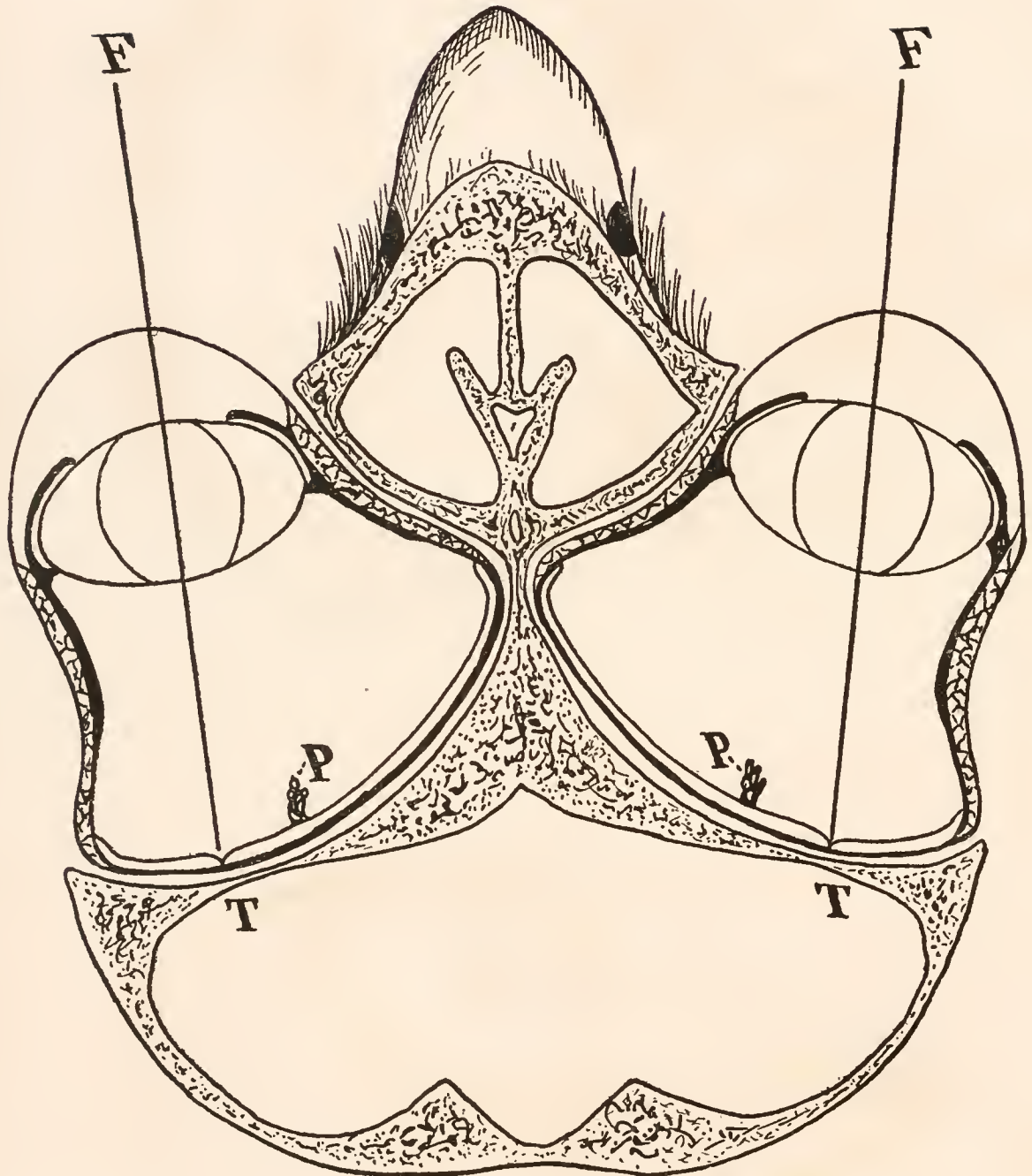


Fig. 4

The Temporal Monomacular Fundus of the Great Horned Owl—*Bubo virginianus*. (After Slonaker.)
FT, visual axis of the single, temporal fovea; P, pecten.

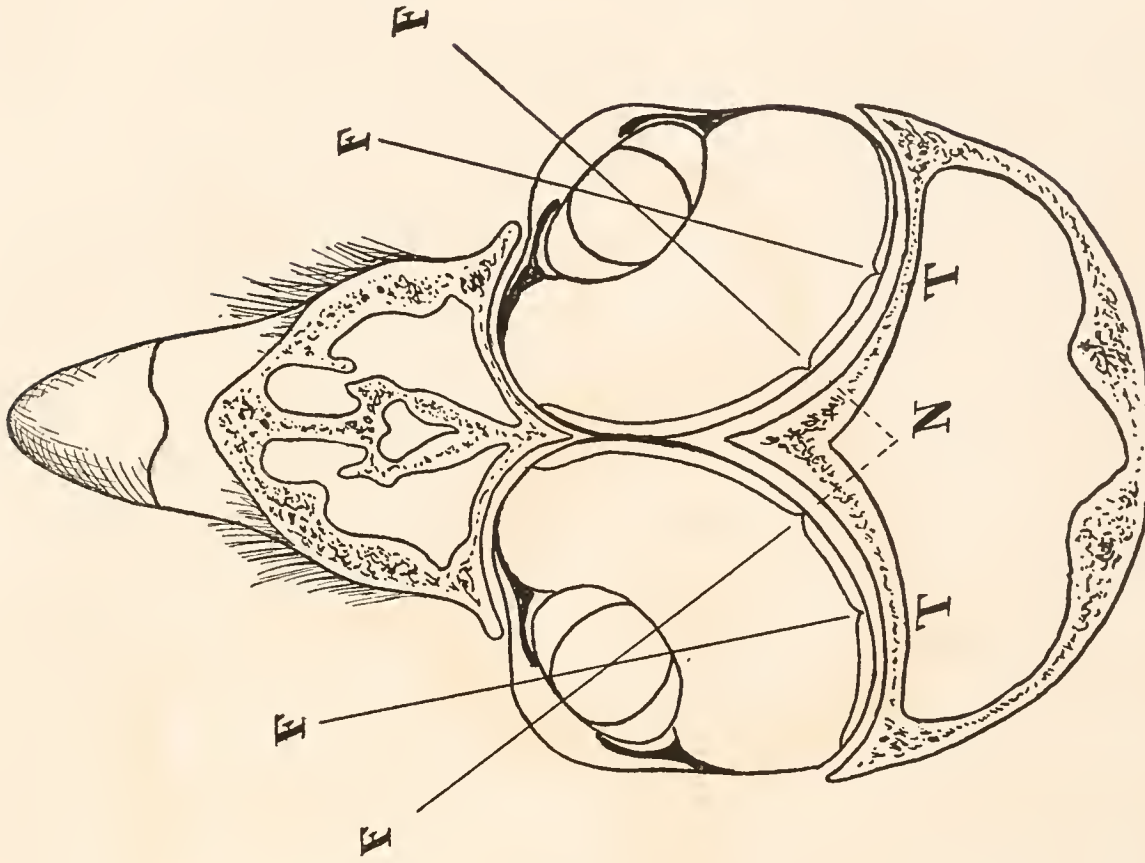


Fig. 6

The Bimacular Fundus of the Broad-winged Hawk—*Buteo latissimus*. (After Slonaker.) FT, Temporal fovea; FN, Nasal fovea.

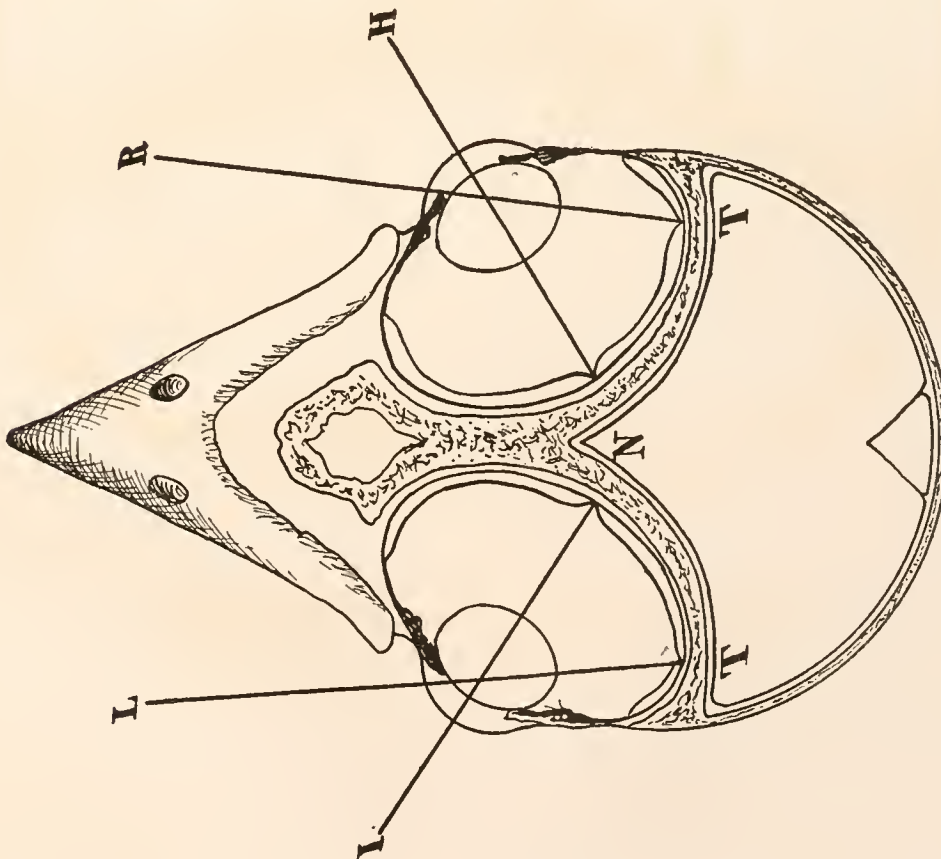


Fig. 5

The Bimacular Fundus of the White-bellied Swallow—*Tachycineta bicolor*. (After Slonaker.) NI, NH, Visual axes of the foveae nasales. TR, TL, visual axes of the foveae temporales.

The Avian Choroid

The choroid coat (*choroidea*) of Birds' eyes is always very thin, even in large eyeballs, but thicker than in the Mammal's eye. The vascular, capillary meshes (*choriocapillaris*) are of irregular size and rather narrow; in *Struthio* the capillaries are 0.01–0.02 mm. wide — broader than in other birds. The spaces between the capillaries are, according

is seen at its widest about the time of hatching (when differentiation takes place most actively) and becomes thinner and remains permanent when the bird is several months old.

A *tapetum* is absent in Birds, although the Nubian Ostrich has a glass-like layer in the choroid, of lamellated structure, capable of reflecting light and producing color inter-

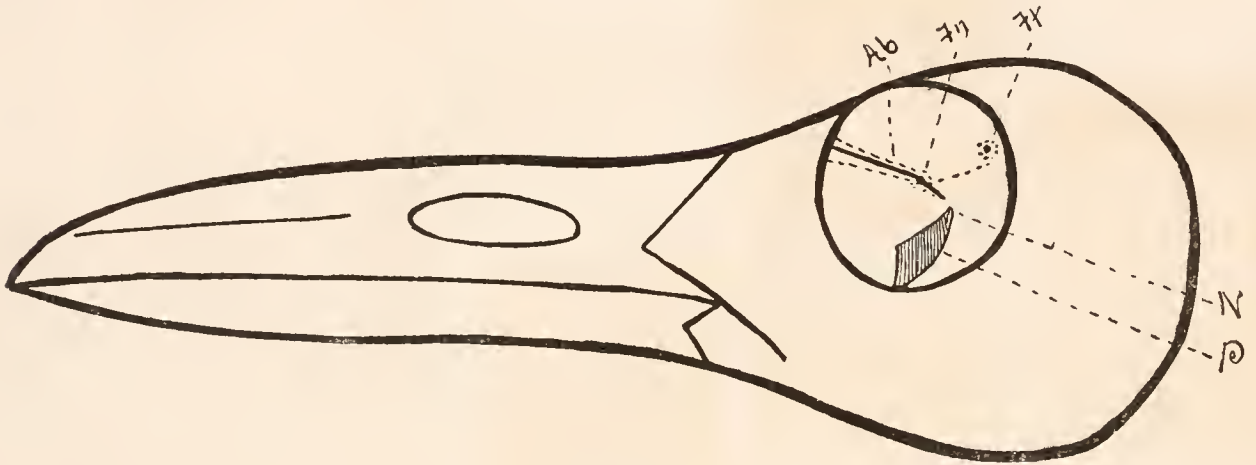


Fig. 7

Macroscopical, Postmortem Diagram of the Infulabimacular Fundus and Orbit of the Tern (*Sterna hirundo*). N, optic nerve entrance; P, pecten; Ft, fovea and area temporalis; Fn, fovea and area nasalis; Ab, band-like area. (After Slonaker.)

to Franz, completely free of cells and pigment. The amount of pigment in the external layer is subject to variation.

The thickness of this coat in *Passer domesticus* is about 200 microns. The vessels of the choriocapillaris measure from 10 to 20 microns in width; between them is a finely punctate substance. This layer is 7 to 8 microns thick. Externally there is an endothelial layer, then a net work of fine elastic fibres without cells or pigment; finally, a dense plexus of connecting cells.

The nerves run within the suprachoroidal space and send only fine filaments into trabeculae that form a cavernous system throughout the whole coat.

Slonaker found the choroid to be enlarged and most vascular (see Fig. 1, just opposite the fovea, especially in embryonal life and in newly-hatched individuals. It is in the former instance one of the indications of the spot where the fovea will eventually form; then it widens during the foveal formation,

ference effects. This arrangement, however, is only a retino-choroidal variation, and not a true tapetum.

The Retina of Birds

The acuteness of the eyesight in Birds is largely due to the fineness and close arrangement of the retinal elements. See Fig. 9.

Gustav Fritsch (*Archiv f. Mikroskop. Anatomie*, Vol. 78, p. 245, 1911) believes that true rods and cones are found in Birds, just as they are in Mammals, and they should be designated as such. In the region of the *fovea centralis* there is also a dwarfed, cone-like form. The colored, retinal droplets of Birds appear mostly in the rod elements, although they are sometimes seen in conjunction with cones. Among the central cones is also found, quite commonly, a body which is colored brown by osmic acid.

According to Franz (*Das Vogelauge*, 1911) the layers of the avian retina are more sharply defined than in any other vertebrate; even

more so than in Mammals. There are no separate bipolar or optical ganglion cells in Birds, while we find in Mammals isolated amacrine cells, and, in reptiles, bipolar cells.

All birds possess rods as well as cones, although in very different arrangements. H. Müller erroneously depicted the cones of the Pigeon with long cylindrical extremities,

layer, stretching out farther than the end of the cone. The rod in nocturnal birds ends in the external portion of the outer reticular layer with a nodosity — a little ball at the end without any branches.

Cajal differentiates three superimposed plexuses in the *external retinal layer*; the first, composed of the basal fibrils of the rods; the second, the end-threads of the straight cones; the third, fibrils which emanate from the oblique cones, that in every cell come in contact with the dendrites of certain bipolars and longitudinal ganglion cells.

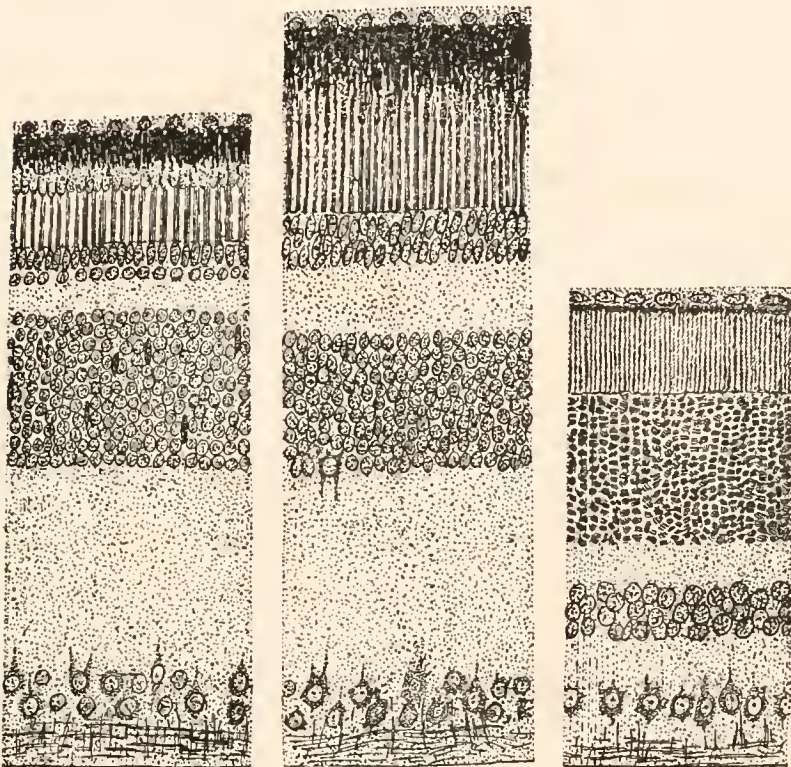
Just as in Reptiles, Schiefferdecker found in the Chicken, Crow and Goose, in the external reticular nuclear layer, concentric supporting cells without nuclei.

The inner nuclear layer of the retina. One finds on the extreme outer aspect horizontal ganglion cells and (a) brush-like cells of Cajal, with many projections and a long horizontal cylinder which, like the short projections, bends around the outer reticularis and ends there with an enlargement and branches; (b) star-like cells with somewhat longer dendrites and a short cylinder which first turns in and then out. Between, and further in than the cells, which Schiefferdecker calls nucleated cells, are found two kinds

of bipolars; first, outer bipolars with highly developed dendrites, and internal, small or thin bipolars with weaker dendrites. The thick bipolars seem to branch out in the fifth layer of the internal reticularis; the thin bipolars assume more the form of a layer in the inner reticularis.

As in all animals, the nuclei of the *supporting fibres of Müller* in the avian retina are situated in the internal nuclear layer.

In the inner portion of the internal nuclear layer are found, as ganglion cells, the layer of amacrine cells, which are divided, both in Birds and Reptilia, into (1) nervous and (2) proper amacrine cells.



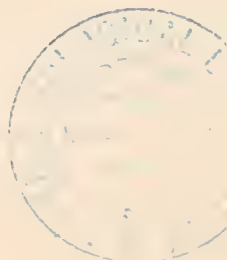Figs. 8, 9 and 10

The Retina of Various Vertebrates

Fig. 8, Lizard; Fig. 9, Bird (Common Crow); Fig. 10, Mammal (Dog). $\times 510$. (After P. Chiarini.)

when these really belong to the rods. The cones have each a single oil droplet, whose color varies. Cajal has differentiated (in Birds and in Reptiles) “straight” and “oblique” cones.

The nuclei of the cones usually lie inside the *membrana limitans externa of the retina*. Several “oblique” cones have an enlargement of the end inside the inner layer of nuclei. The “twin” cones, whose nuclei are not to be seen, lie near the *membrana limitans*; the smaller nucleus of the pair is in a facet of the larger. The rod nuclei are usually found in the internal half of the nuclear layer. Their small end branches in the outer reticular



The layer of ganglion cells. Cajal differentiates the following types of ganglion optical cells: (a) single-layered cells, spreading out over the internal reticular layer, partly multipolar, but mostly belonging to the reticularis; (b) many-layered, multipolar cells. The smallest are plentiful in the Passeriformes; i.e., the Sparrow, Chaffinch, Greenfinch, etc.

It should be noticed that Dogiel expressed the opinion that those cells which in form, size and character of branching of the protoplasmal and cylindrical processes, belong to a certain characteristic type, anastomose with each other, or form a "colony."

The relatively thick, *optic connective tissue* receives single, dissimilar, thick filaments, which, originating centrifugally from the optic nerve, intermingle with the internal plexiform tissue and end, according to Cajal, on the level of the amacrine cell-layer.

Specific differences in retinal elements. As in almost all of the sub-classes of vertebrates, there are differences in the retinae of Birds, especially in the tissues of the rods and cones.

The numerical proportion of rods to cones in different species is quite marked. Richest in cones are the diurnal Birds of Prey. Corresponding to these in Night Owls are "rod-retinae." M. Schultze thinks that while Owls have many long rods, they have few cones; Krause believes that the cones are invisible on account of the number and length of the rods, but that they are no less numerous in the Owl than in the Falcon.

Geese have, according to Krause, many long rods and stand in that respect midway between Owls and diurnal Birds of Prey. The Flamingo has the longest of all rod extremities. The Heron has many thick rods.

Krause seeks to weaken the force of the statement of Schultze, that Nocturnal Birds are distinguished by the preponderance of cones and a diminished number of rods, by pointing to the discovery of Heinemann that in (the nocturnal) *Nycticorax* the rods are scarce; that the Swallows, *Hirundo rustica* and *Chelidon urbica*, in the relative increase of their cones resemble the Owls, while *Athena noctua* possesses even more cones than

rods. According to Hess, the number of cones in the Owl's retina reaches 1 to 2½ millions.

However the teaching of Schultze has much in its favor; insofar as that the hypothesis supported by it, viz., that cones are really color-percipient organs (the rods perceiving light and form) finds proof in the fact that *rods alone* are found only in the retinae of deep-sea Fishes and Whales.

Regarding the possession of retinal *oil droplets, ellipsoids, paraboloids* and *hyperboloids*, there are, according to Krause, many differences in species. In *Cardinalis virginianus* and *Fringilla spinus*, he differentiated two kinds of cones; in the Hen three outer double cones. *Fringilla spinus* shows a blue oil droplet in many of its double cones.

The layer of nerve filaments receives in the Pigeon and a few other birds partly *medullated fibres*. Franz finds in many birds that the layer of nerve filaments in the vicinity of the optic foramen corresponds to what in Mammals are called "spider cells."

Pigment Movement in the Retina of Birds

Although this strange phenomenon probably occurs in most vertebrates, and to a slight extent in some invertebrates, yet it is in birds that it is best studied. As Kalt remarks, the retinal *pigmented epithelium* forms fringes which, under the influence of light, descend to the external limiting membrane. In the dark they do not move past (at least in the Pigeon) the middle of the rods and cones.

The purple of the retina is missing, according to Kühne, from the rods and cones of the Hen and Pigeon. It exists in large quantities, however, in the external segments of the rods of the Screech Owl, while the cones are devoid of it.

As Kühne points out, the cones have variable dimensions, and are single or double. At the end of the internal segment they have a single, oily, colored ball or droplet, which, however, is not found in the interior of the accessory cones. In a fresh retina the balls show immediately with their various tints.

As far as the *color of the retinal oil-droplet of Birds* in general is concerned, Schultze

differentiates mainly (a) colorless, (b) yellow to reddish-yellow and (c) red droplets. Again, he finds a difference between Day Birds and Owls in that the red are lacking in the latter while the pale yellow and colorless varieties are more plentiful.

According to Kalt, Waelchli distinguishes four varieties of colored oil droplets in the avian retina; red balls disseminated over the whole membrane; orange, or yellow balls, whose distribution is the same; greenish-yellow ones seen at the periphery; and uncolored ones spread in small quantities over all. Osmic acid colors all these balls black. The coloration is particularly intense in the macular region.

The locality in which the colored droplets are found varies with each tint. The green balls are situated nearest the external surface of the retina, the red come next, then the yellow, and finally the colorless balls.

A chemical examination of the colored globules in the cones of birds was made by Kühne. A hundred retinas of the Hen were treated with alcohol and ether. The fatty material thus dissolved (colored red) gave, with soda, a soap from which was extracted by petroleum ether a green coloring matter; by sulphuric ether an orange material; by turpentine a deep rose colorant; this last one is, however, insoluble in sulphide of carbon.

Kühne gave the names of *chlorophane*, *xanthophane* and *rhodophane* to these pigments.

The Areas of the Retina in Birds. Avian *areae centrales* are of greater variety — especially regions of distinct vision — and in greater number than in other Vertebratæ.

As described (see Chapter VII, page 59) and depicted elsewhere (Figs. 110 to 115 inclusive) the writer believes that there are at least six forms of these *areae* in Birds.

According to Chievitz (1891) and Slonaker (1897) there is at least one round macular region with a fovea in practically all Birds. This single area of monocular vision (see Figs. 110 and 111) is in most Birds situated somewhat centrally, slightly to the temporal or the nasal side.

In many species, diurnal Birds of Prey for example, besides a central fovea in the nasal

aspect of the retina, *fovea nasalis*, there is a *fovea temporalis*, which with the fovea temporalis of the opposite eye may serve for binocular vision.

The *area centralis retinae*, *macula lutea* or *macular region*, is found in all classes of Vertebrates and its presence is the rule, especially in Reptiles and Birds.

The terms commonly applied to the various parts of the macular region are as follows: the whole area is designated the *macula*, or *area centralis* or “yellow spot;” the more sensitive, smaller area, generally disposed in the geometrical center of the macula, is called the *fovea*. Not infrequently there is seen a still smaller point at the bottom of the foveal depression; this is termed the *foveola*. This is the terminology employed in human ophthalmology and there seems no good reason why it should not be applied to all vertebrate eyes.

When the macula is placed on the nasal aspect of the optic entrance it is called the *nasal macula* or *area nasalis*; on the temporal side, the temporal macula or *area temporalis*. In the same way, one speaks of the *area* or *fovea nasalis* and *fovea temporalis*.

The *area centralis* presents a thick portion of the retina, where the arrangement of the elements recalls that observed at the level of the “yellow spot” of the human retina. There is in this region an increase of ganglionic cells and of the receiving or percipient elements — the cones and rods.

The *depth of the foveæ* may be regarded as a measure of the sharpness of vision. Slonaker classifies foveæ as *deep*, *medium* and *shallow*. The round fovea is especially “deep” in swift Fliers and Birds of Prey; “medium” to “weak” in most other birds, except that it is “shallow” in the domestic Pigeon, and probably lacking in the Hen.

Krause is probably right in believing that domestication brings about the disappearance of the fovea.

Both foveæ in the bimaular fundi of diurnal Birds of Prey are structurally much alike, in that they have in them only cones, and only those with yellow droplets.

Besides this central area (with a fovea) there is often, in Birds, a *ribbon- or band-like*

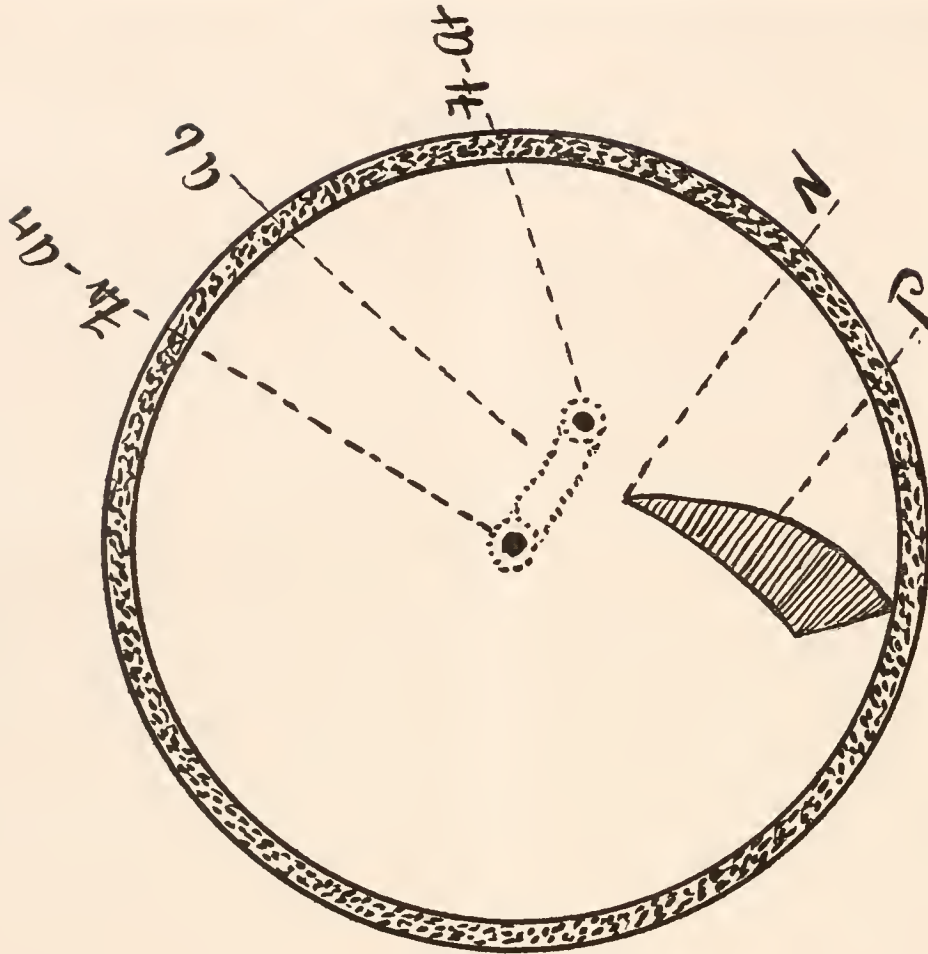


Fig. 12

Diagram of the Double Maculae, Double Foveae and Third Visual Area of the Red-tailed Buzzard (*Buteo borealis*). PN, optic nerve entrance; P, pecten; Ft, At, fovea temporalis and area temporalis; FN, AN, fovea and area nasalis; Ab, band-like area. (After Slonaker.)

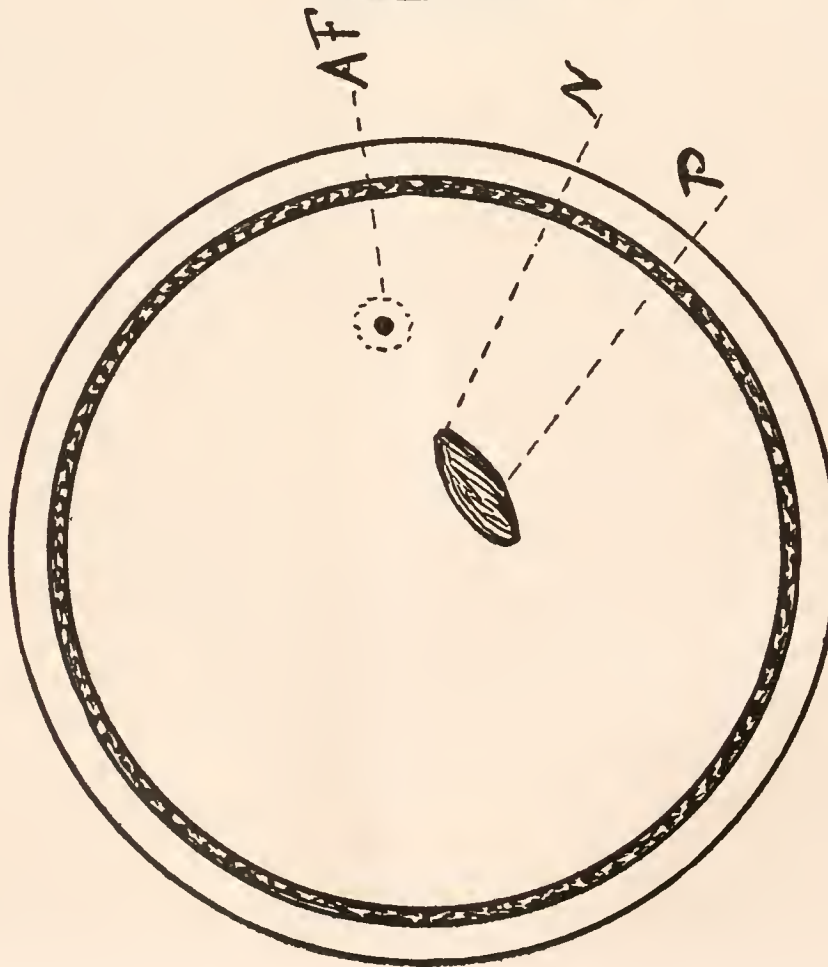


Fig. 11

Diagram of the Fundus (Macroscopic, Postmortem View) of the Barred Owl (*Syrnium nebulosum*). PN, optic nerve; P, pecten; AF, macula and central fovea. (After Slonaker.)

arrangement of retinal tissue that is generally found in the horizontal meridian. It is mostly seen in those birds that seek their food upon the ground, e.g., *Motocilla*, *Saxicola*, *Struthio*, *Totanus*, *Tringa*, *Larus*, *Squatarola*; also in the Goose, Flamingo and other Aquatic birds. See, for example, Figure 14.

Perhaps the retina manifests the greatest foveal development in swift-flying birds. For example, *Cypselas*, *Hirundo* and *Sterna* have three foveæ.

Slonaker has also noticed an important variation in the relative position of avian foveæ and has offered an explanation borne out by the results of this investigation; the fovea nasalis is almost invariably found in the same fundus area, but the locality of the temporal fovea depends upon the position of the eye in the head. As the eyes are turned more and more forward the fovea temporalis approaches the fovea nasalis. As binocular vision becomes more frequent both foveæ may become merged into one, generally deeper, pit. There is also a corresponding change to an asymmetrical form of the eyeball and to a peculiar position of the crystalline lens in birds with binocular vision.

In many such birds, the White-bellied Swallow (see Fig. 5) and the various Terns for example, the nasal fovea is deep and sharp, while the temporal fovea is quite shallow and the eyes are almost symmetrical; but in birds with more marked binocular vision, Hawks, for example, the temporal fovea has the greater depth and the eye becomes more asymmetrical. The climax is reached in Owls, whose eyes are most irregular in form, who have but one (deep) temporal macula and who see only binocularly.

As with other organs in their body the component parts of the visual apparatus of Birds are arranged and adjusted mainly to enable the Bird to obtain food and to escape his hereditary enemies. In a minor degree, too, we observe the influence of the necessity for swift locomotion. Other (occasional) taxonomic influences are apparent in certain special visual requirements, such as nocturnal vision, the use of the eyes under water, the employment of the eyes for vision both in air and

water, the visualization of minute objects close at hand, etc. This statement is true in full measure of the organs and tissues comprising the fundus oculi.

Stereoscopic, binocular, single vision in Birds with double foveæ — and this is the most acute, accurate and effective form of eyesight that these or any other animals know — is probably accomplished by the two temporal foveæ acting in cerebral unison. It is this form of sight, for example, that enables the Osprey and other Hawks first to locate from a distance and then to dart unerringly upon their prey.

The deep and evidently more acutely functioning nasal fovea is, in the writer's opinion, employed for monocular vision only, and there seems every reason to believe that Birds with double foveæ have exceptionally good eyesight with each eye separately; they are, by this effective combination, enabled not only to command a view of the highest efficiency over the whole horizon, but also have the power to concentrate it when needed upon particular objects invisible or indistinctly visible to other species not so provided.

It must, however, be acknowledged that the neurology of Birds, involved in these questions, is a sub-section of biology as yet in its infancy; only when the histology, pathology and experimental physiology of the avian cerebral organs and their connections have been worked out as they have been in Man shall we know how the paths pursued by "brain currents" involved in this switching from monocular single vision to binocular sight run and are controlled. As these questions now stand the only certain thing that can be said is that, with the possible exception of the Owls, they must be totally unlike the cerebral and spinal arrangements discovered in Man and the higher Apes.

Of the physiology and psychology involved in the *ribbon- or band-like area* we know still less. In all probability it is a device to enable swift-flying birds to take their prey on the wing, and other species to find their food on the ground while they themselves also stand on *terra firma*; in other words, birds with banded retina possess eyes that are chiefly employed

in food-searching in such a fashion that they are enabled to see *one object* very distinctly and *neighboring objects* (in a restricted field of vision) more distinctly than is permitted by the comparatively insensitive retina of the remaining fundal areas.

Infulapapillary angle. The relations, especially of fundal position, between the optic nerve entrance, the pecten, and the areas of distinct vision are, as we have already seen, of some biological importance. Upon the locality of the macular regions depend, in great measure, the quality and precision of the eyesight of each particular bird. That one may facilitate references to the location in the eyeground of the retinal band the writer proposes to measure what he has termed the *infulapapillary angle* (*infula*, a band, *papilla*, the optic disc), made by the junction of the major axis of the ovoid entrance of the optic nerve prolonged until it meets the retinal band on the nasal side of the point of contact. In the case of the Hudsonian Curlew (see Fig. 125) it is 50° .

The Optic Nerve of Birds

In all Vertebrates the optic nerve has the form of a cord, sometimes very short, as in Birds, and occasionally long, as in Man, which extends from the optic foramen to the posterior segment of the eyeball, where its expansion forms the retina.

In Birds, whose ocular movements displace the eyeball very little, the nerve takes the form of a short, almost rectilinear cord; while in animals with mobile eyes, such as the large Mammifers, the nerve is long, round and S-shaped, to follow the displacements of the posterior hemisphere without pulling or dragging. Its diameter greatly varies; it may reach 8 mm., as in the Whale. The rule is that it roughly corresponds in size and length to the volume of the eye-ball.

As Kalt says, the pia mater forms the neurilemma or sheath of the optic nerve. The multiple partitions which it sends into its substance, divide the nerve into bundles; the dissepiments anastomose with each other. This is the type well known among Mammals. Birds exhibit one peculiarity; at the inner

aspect of the nerve the pial partitions penetrate perpendicularly into the substance of the nerve and do not anastomose until they reach about half way into the thickness of the cord. Analogous perpendicular partitions, but very short, exist sometimes on the external side. The result is that the nerve has a foliated appearance, especially marked on the internal side.

The Pecten, Marsupium, Fan or Comb of Birds

By means of the ophthalmoscope and direct illumination there is seen, below and externally, in the fundus of every bird, a black mass of variable form. When the free edge of this organ is illuminated one notices a longitudinal strip with undulating edges. If one throws the light upon the base of this object — the *pecten* or *comb* — the papilla looks like a sparkling white area whose margins are edged with black, the center being occupied by the irregular, black mass.

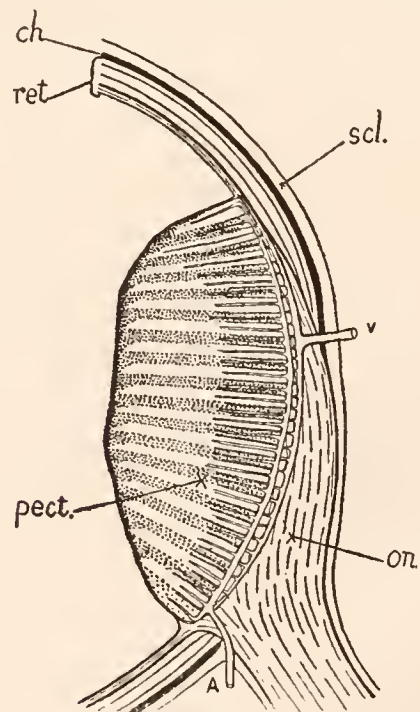


Fig. 13

Diagram Showing the Relations of the Optic Nerve Entrance to the Pecten and the Basilar Artery and Vein in the Sparrow. (Wood and Slonaker.) A, artery to pecten, which sends a branch along each fold; *ch*, choroid; *on*, optic nerve; *pect*, pecten; *ret*, retina; *scl*, sclerotic; *v*, vein from pecten, which receives a branch from each angle of the folds.

The pectinate image seems to be displaced by abrupt movements in the vitreous mass, disturbances due probably to contractions of the ocular muscles, external and internal.

As Kalt says, the pecten is a membranous organ covered by a black pigment attached to the optic nerve and projecting a variable distance into the vitreous body. This organ, studied and described for the first time by Perrault, in 1876, received later the name comb (*peigne*). The term "comb" is not exact since there are no separate teeth; perhaps "fan" better describes the appearance of this organ. German authors still call it the "fan" (Fächer).

Except in the Ostrich, where it has the form of a cone inserted into the optic nerve and divided into two parts by a sort of white partition, the pecten represents a triangular or rectangular pigmented lamina, whose plane is directed down and out.

Generally it does not extend into the vitreous beyond the intercalary zone of the sclerotic, and it is only exceptionally, as in the Goose, the Swan, the Stork, etc., that it reaches the crystalline lens. The comb is made up of a lamina folded upon itself and producing, in a transverse section, a markedly zig-zag effect. The number of plications varies from 5 to 30, averaging 16, as in birds of prey and Gallinaceæ. The writer and Slonaker counted 18 folds in the English Sparrow.

Among the Owls, the length of the comb is 5 mm. at the base; its height, 4 mm. In the Stork the base is 13 mm. long; it is 7 mm. high.

Kalt believes the pecten to be essentially a vascular organ. It is composed of a network of capillary vessels of unequal dimensions spread out in two or three superimposed planes, whose mesh may vary in form and dimensions. In the Goose the vessels are nearly all parallel; the anastomoses are rather rare and the meshes acquire great length. The thin connective tissue, which serves as a support, contains free pigment. The entire organ is enclosed in an envelope of endothelium.

Kalt further thinks that the pectinate blood-supply is derived from the external branch of the internal carotid, which, imme-

diately after leaving the temporal, forms a large plexus. The branches from this plexus cross the sclerotic and re-unite in a single trunk, which corresponds to the central artery of the retina in mammals. This trunk extends to the base of the comb, where it gives off several ascending vessels, that penetrate the latter and form a large capillary plexus. The venous blood is returned by a large choroidal vein which perforates the sclerotic a short distance towards the middle of the comb. Note, also, that it makes at the level of the ocular groove several variable anastomoses with the plexus of posterior ciliary arteries. See Figure 13.

According to Beauregarde the pecten is allied to the choroid; it appears after the fourth day in the embryo of the Hen.

The *function of the pecten* has from time to time been variously interpreted. It has been considered particularly as an erectile organ capable of displacing the crystalline lens and thus taking part in the accommodation of the eye. Beauregarde, using the ophthalmoscope, found displacements of the organ and rapid vibrations synchronous with the movements of the nictitating membrane. But he noticed, above all, that the comb is placed so as to intercept the rays coming from the front and from above; that is to say, those rays that reach the two eyes simultaneously. In catching them, the pecten is supposed to suppress momentarily, in this way, binocular vision, a condition which is necessary for the more perfect use of monocular vision.

No doubt the pecten occasionally serves as a screen to protect the retina against the rays of the sun. Observation of the attitude of the Hen's head, when exposed to the sun, is favorable to this supposition, as, also, the slight development of this organ among nocturnal birds.

Another hypothesis, which seems plausible, attributes to the comb the role of an organ of nutrition for the vitreous, and makes of it an appendage of the ciliary body. It has also been suggested that it is an organ of excretion, charged with maintaining the intraocular tension.

Franz does not believe that the fine structure of the bird's pecten has, as yet, been fully described. The structural arrangement in *Struthio* shows it to be different from other birds, where it springs as a sort of wrinkled leaf from the papilla and has an enlargement, which he terms the "bridge," which runs along the entire margin of the pecten. See Figure 24 and Plate I. The folds are welded together by this bridge, so that they can only be smoothed out by cutting away the latter.

The *histological structure of the Bird's pecten* has been investigated by Mihalkowics, Deniszenko, Bernd and others. Bernd claims that the pecten is not primarily of mesodermal origin and an appendix of the choroid, as was formerly held (by Kessler, for instance), but is really a derivative of the retina or of the optic nerve; in short, an offshoot of the central nervous system and, consequently, of the ectoderm.

Franz maintains that the pecten is a sense organ, assisting in the regulation of the intra-ocular pressure and the act of accommodation. On the upper surface of the pecten, that is on the "bridge," Franz found filaments that end there in club-shaped bodies, structurally between pigmented nuclei and cell nuclei, and he believes we may look upon the pecten primarily as a glia-structure, an opinion also held by Blockmann and v. Husen. Still, Franz will not say, nor does Blockmann, that there is to be found in the pecten any convincing evidence of the presence of true nerve filaments.

Franz and Hushke point out that the pecten is all the more developed the more the bird makes use of monocular, and less of binocular vision; that the pecten of Song-birds is large and rich in wave-like folds, while the much faster flying Swallow, with better accommodation, has a more poorly developed pecten. The Owls, also, with their small pecten, have binocular fixation.

Both in Birds and Reptiles there is a close connection between the pecten and the vitreous; in other words between that organ and the margins of the hyaloid canal, or slit, in which it is, as it were, inserted.

Franz does not feel certain about the vascular supply of the pecten of the Bird. He believes, however, that the bloodvessel that runs along the base of the pecten gives off branches to the folds (as shown in Fig. 13) and, to a less extent, to the pectinate bridge. The main vessel is to be regarded as the artery (afferent vessel) of the pecten.

We find glia-growths like those of the avian pecten emanating from the papilla in many Mammals and which present the same characters as these organs in Reptiles. In the eye of Amphibians and Fishes there are no such glia-growths.

After many dissections and much consideration of the finer anatomy of the organ Slonaker and the writer do not regard the avian pecten as anything more than a series of bloodvessels with a deeply pigmented framework of glia fibres and cells. So far we have been unable to find in numerous serial sections of the Sparrow's pecten (or in that of any other bird so far examined by us) definite ciliated structures, sensory buds, or any other appearance that would justify a belief other than that this organ, deeply pigmented to absorb the light rays, has any function apart from that of a carrier of nutritive pabulum, chiefly to the vitreous and anterior layers of the retina. It may change its position, actual or relative, during accommodation, but it has no other connection with the accommodative act. The covering of all its fan-like folds is continuous and identical with the hyaloid membrane or *membrana limitans* of the retina. We did not find in the Sparrow any anastomoses between the vessels of the pecten and the other ocular structures. The branch of the ophthalmic artery that enters the eyeball close to the optic nerve sheath (to penetrate the latter at the plane of the sclerotic coat) is the only afferent vessel-supply of the pecten that we were able to demonstrate, either by gross dissection or in serial microscopic sections of this region.

In the same way there appears to be only one efferent vein which may, however, have received other venules before its exit from the globe, several millimeters distant. These two latter observations are, however, based on an

incomplete dissection of the parts and may be modified later.

In this judgment, if we read him aright, Treacher Collins, to some extent, concurs. In his Erasmus Wilson Lectures on the Anatomy and Pathology of the Eye he remarks that "in other animals than Mammals and in the human fetal eye there are sources of nutrient supply to the intraocular structures in place of or in addition to the ciliary body." He adds that the pigmented, plicated structure of the bird's pecten "closely resembles the choroidal coat . . . having, however, a rather finer capillary plexus. Birds, therefore, not only possess well-formed ciliary processes but also a special vascular arrangement in the vitreous chamber."

According to O. Zietzschmann, also, the pecten is covered by a delicate membrane which is continuous with the inner limiting membrane of the retina. The bloodvessels, according to him, belong to the ciliary system and are branches of those supplied to the optic nerve. Leber believes the pectinate artery to be the homologue of the hyaloid artery.

Finally, it may be added that there are no bloodvessels in the Birds' retina and the vessels of the pecten do not, consequently, arise from a central artery of the optic nerve as in Mammals since that, too, is wanting.

This arrangement, inasmuch as the opaque vessels do not, as in most Mammals and other Vertebratæ, intercept the rays of light impinging on the percipient elements of the retina, makes for a more distinct and measurably clearer-cut image of the object visualized by the avian brain.

Comparative ophthalmoscopy of reptilian fundi. With the aid of Mr. Head's brush and by courtesy of Dr. Lindsay Johnson the writer is able to compare a few typical fundi of Reptiles with those of their ancestral cousins the Birds.

It requires only a glance at these pictures to feel assured that the eyes of that nocturnal reptile the Turkish Gecko (Plate LIX), whatever else may be said on the subject, are more decidedly avian or, rather, more ornithosaurian than are those of the Horned Toad (Plate LX), or Indian Cobra (Plate LXI), whose fundi belong more distinctly to other vertebrate types. These last-named possess definite retinal vessels (that issue from a circular optic papilla), and they have no pecten or at least the mere suggestion of one. Compare Plate LXI with Fig. 143; and Plate LX with Fig. 144, which show the resemblance between the Cobra fundus and that of the Hedge-Hog, while the eye-ground of the Horned Toad suggests that of the Virginian Opossum. For further comparison a diagram of an ichthyan fundus

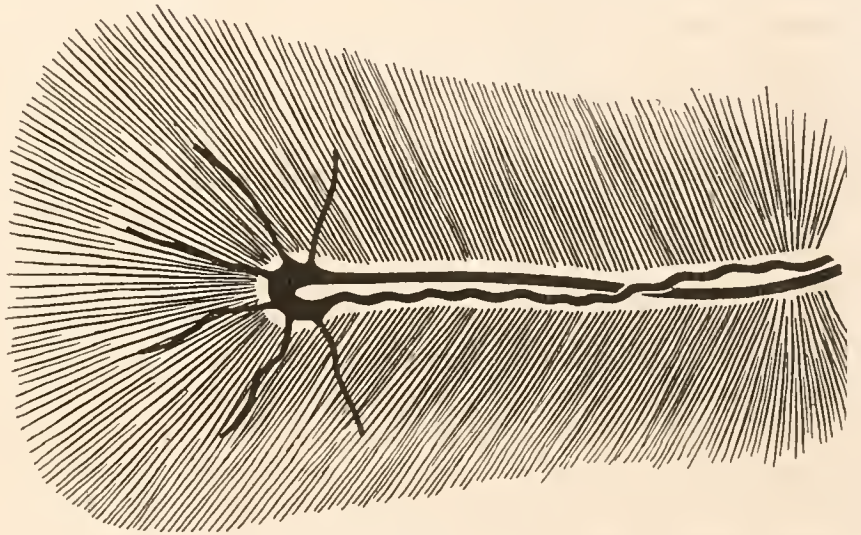


Fig. 14

Ophthalmoscopic View of the Fundus of the Fish *Gadus merlangus*. (After Beauregarde.) The processus falciformis (black) runs the whole length of the (white) optic nerve-head, at the periphery of which are seen six branches of the hyaloid artery.

oculi (Fig. 14) — that of *Gadus merlangus* — is shown.

If one may draw any conclusion from such sparse material and from such an incidental examination of the subject it is that whatever of common origin the avian and reptilian classes may have originally had the ornithological branch left the parent stem with a subdivision of the Lacertilia and not with the Ophidia.

CHAPTER V

OPHTHALMOSCOPY, OR THE EXAMINATION THROUGH THE PUPILS OF ANIMATE SPECIMENS OF THE INTERIOR OF THE VERTEBRATE EYE BY MEANS OF THE OPHTHALMOSCOPE

SINCE this subject, although familiar to ophthalmologists (oculists), is rarely understood by naturalists in general, and especially not by ornithologists, a brief review of ophthalmoscopy as practiced on the vertebrate eye may not be out of place in a work like this.

The ancients noticed that the eyes of some animals are, under certain conditions, brilliant in twilight or semi-darkness. Although he did not attempt to explain the phenomenon, Pliny remarks that the eyes of animals that see at night — cats, for example — are radiant and shining, and that the eyes of the she-goat and the wolf emit a light like fire. This fact continued to be noted through the succeeding centuries and was commented on more or less by other observers. Jean Méry of Paris, who in 1704 immersed a cat in water, beheld in all its glory the fundus of that animal's eye, including the optic nerve entrance, the retinal blood vessels, and the remarkable coloration of the retina and choroid. Méry did not give a proper explanation of this phenomenon, but five years later de la Hire showed that the refractive power of the cornea is neutralized by immersion of the animal's eyes in water, so that all rays of light reflected from a given point of the fundus emerge from the pupil not as parallel but as divergent rays; consequently the fundus images can be seen as if one were looking at them in the depths of the eye through air.

The Fundus Oculi or Background of the Internal Eye in Man. Glimpses of the human

ocular interior were obtained from time to time but it was not until the year 1847, when Babbage, an English mathematician, exhibited to Wharton Jones, a well-known oculist of his day, the model of an instrument by means of which the interior of the eye could be thoroughly examined. It consisted of a small, plane, glass mirror from whose centre a portion of the silvering had been removed. This device was not made known to the world until 1854, before which date the celebrated physicist, Hermann von Helmholtz, published, in 1851, a description of an ophthalmoscope which enables the observer to see with ease all the parts in the background of the eye.

The Ophthalmoscope. The original Helmholtz instrument consisted of four thin plates of glass carefully polished, screwed together, fastened at an angle of fifty-six degrees to a brass disk, and forming the hypotenuse of a right-angled triangular prism. The other sides of this hollow prism were made of metal, and all carefully blackened inside. The brass disk had a hole in its centre and an arrangement to place a concave lens over it; for normal eyes Helmholtz used a No. 10 (4 D.) glass. The light from a lamp falling on the glass plates was in part reflected into the observed eye, while the observer, looking through the concave lens and the opening in the brass disk, received the returning rays in his own eye, and was able to see the fundus, weakly illuminated, but still distinctly.

The instrument *now* in use for examining the interior of the eye more nearly resembles

the original ophthalmoscope of Babbage than that of Helmholtz.

It consists essentially of a concave mirror of about 25 cm. focus (mounted on a handle), with a small (3 mm.) hole in the center and so arranged that a series of concave and convex lenses may be presented to the opening for the purpose of neutralizing the refractive error of the observer's and the observed eye, thus giving a clear view of the fundus details.

There are numerous ophthalmoscopic models in the market today — improvements on the early inventions — but the instruments of Loring and Morton are, perhaps, the favorite forms now in use. Illustrations of these are given in the text. See Figs. 15 and 20.

As the *purpose of an ophthalmoscopic examination* is to see as much as possible of the interior of the eye under observation *it is desirable to dilate the pupil*;— in the case of mammals this is accomplished by instilling into the eye atropin, homatropin, euphthalmine or some other mydriatic.

Before the invention of the *self-luminous* or *electric* ophthalmoscope (Fig. 21) the source of illumination of the ocular interior was a gas jet or electric bulb — preferably an argand lamp — stationed in a darkened room, and placed on a level with the eye to the side of the head.

In examinations of the human eye the observer sits opposite the individual whose ocular interior is to be explored, and placing the mirror close to his own eye and about 40 or 50 cm. from the eye to be examined reflects the light upon the latter, while he looks at it through the small opening in the ophthalmoscopic mirror. In very short-sighted and very long-sighted eyes, but not in normal ones, the vessels of the retina, the entrance of the optic nerve, etc., can be more or less distinctly seen.

The *details* of the retina, choroid, etc. (or fundus), can be seen in two different ways. In the *indirect method*, as applied to Man and most other vertebrates, the observer, seated as shown in the cut (Fig. 16), holds a strong (16 D.) convex lens about 10 cm. from the eye under examination, and between it and his own, when a clear *real* image of part of

the fundus, *inverted* and magnified about four diameters, appears in the red light of the pupil.

In the *direct method* (Fig. 17) the observing eye must be placed as close to the observed as the intervention of the mirror will allow, when a *virtual* image of a still smaller part of

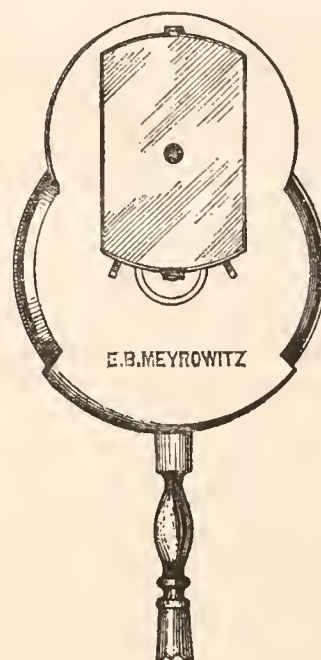


Fig. 15

Loring Ophthalmoscope

the fundus is seen, but *erect* and magnified about fourteen diameters.

Direct ophthalmoscopy, or the examination by the upright or erect image, is illustrated by means of Fig. 17. A side lamp (L) is used, the rays from which are focused by the perforated mirror of the ophthalmoscope (OO) and thrown into the observed eye through the dilated pupil (P). The rays of this pencil now cross about X and impinge on the retina and choroid at OO and cover the ocular background from B to B. Thence a sufficient number of efferent rays are reflected and refracted back through the ocular media of both the observing and observed eyes to the percipient elements of the former, at L.

Another illustration (Fig. 16) shows *indirect ophthalmoscopy*, or, as it is sometimes called, *the examination by the inverted image*. A divergent light pencil proceeds from the

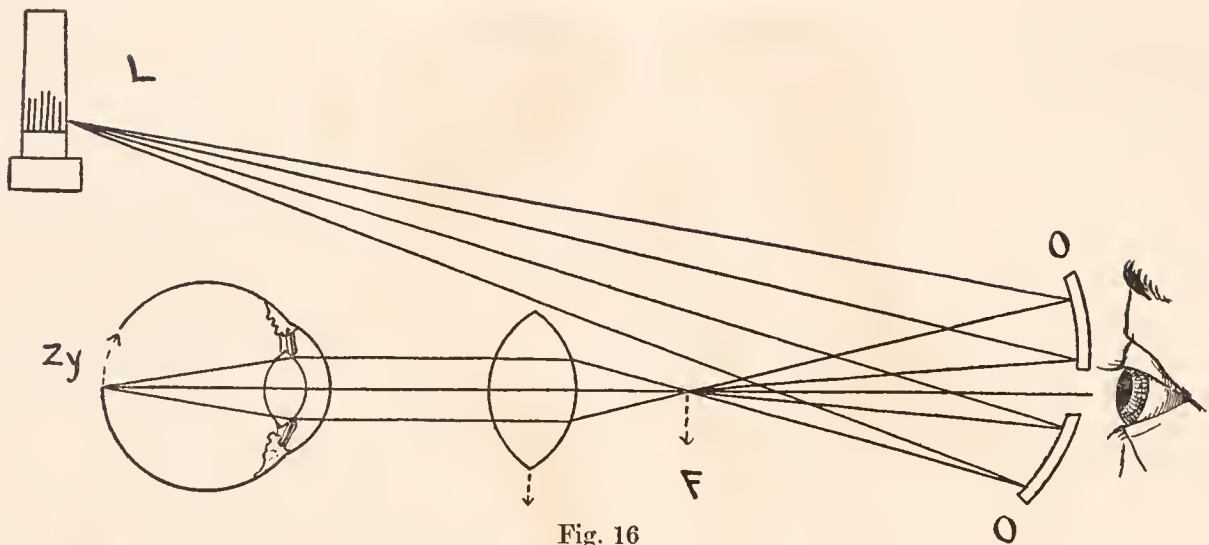


Fig. 16

Indirect Ophthalmoscopy

Diagram showing the course of the light rays from the lamp, L, to the ophthalmoscopic mirror, OO, whence they are reflected to a focus, at F, where they diverge, to be once more focused by the lens on to the retina at Zy, to be finally reflected to the eye of the observer at the opening in the centre of the mirror, OO.

lamp, L, to the ophthalmoscope mirror, OO, which focuses the rays at F. These subsequently divergent rays are now made parallel by the convex lens and are thus brought to a focus on the retina-choroid by the dioptric apparatus of the observed eye. Thence the reflected and emergent rays follow the same path and come to a focus, at X, in the eye of the examiner who will see an inverted aerial image of the observed fundus.

The *electric self-illuminating ophthalmoscope* differs from the types just pictured in that it carries its own light source — a bat-

tery in the handle. It is peculiarly adapted to the examination of the eyes of animals other than Man. One is enabled through this improvement not only to dispense with the cumbersome side light but to make satisfactory examinations of the fundus oculi in only partially darkened surroundings — serious considerations in doing field work with wild species. A picture of the latest model of the self-luminous ophthalmoscope is shown in Fig. 21.

The fact that a considerable portion of the light thrown into the interior of the eye

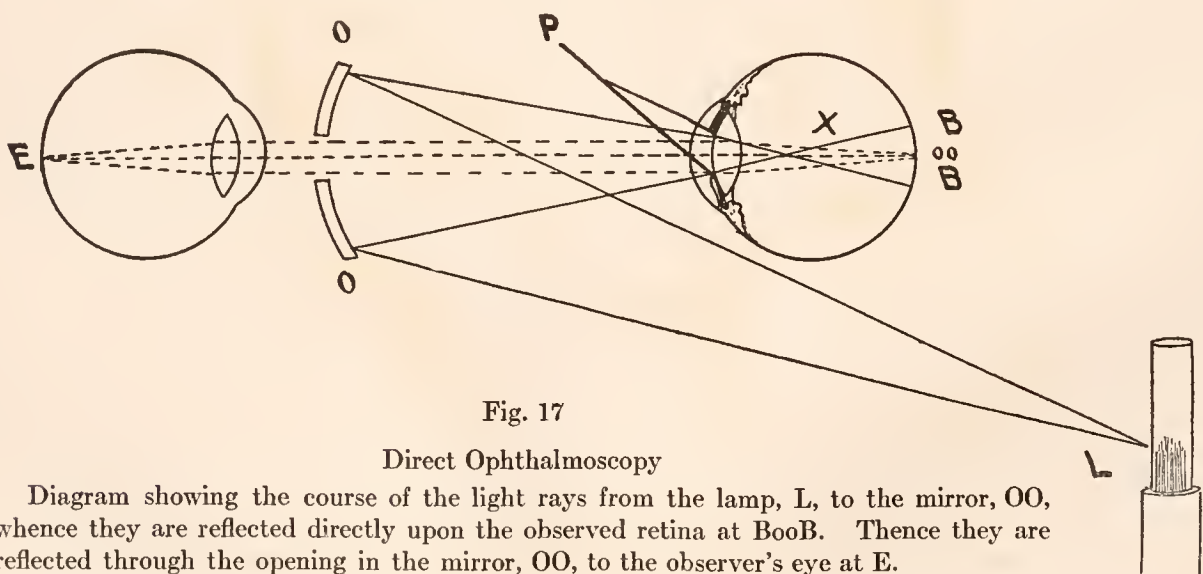


Fig. 17

Direct Ophthalmoscopy

Diagram showing the course of the light rays from the lamp, L, to the mirror, OO, whence they are reflected directly upon the observed retina at BooB. Thence they are reflected through the opening in the mirror, OO, to the observer's eye at E.

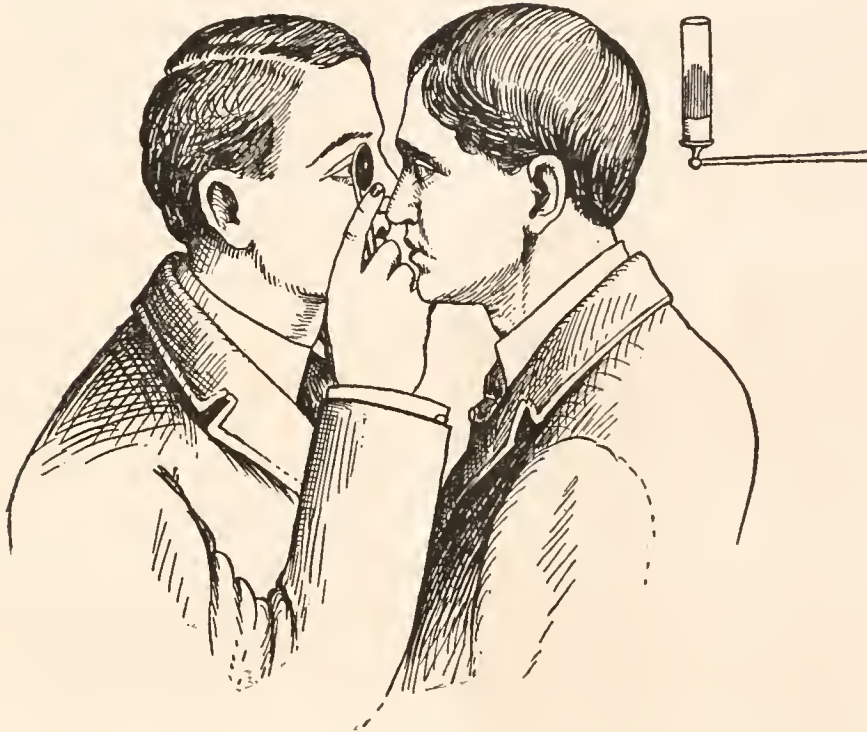

Fig. 18

Relative Position of Observer and Observed in Direct Ophthalmoscopy

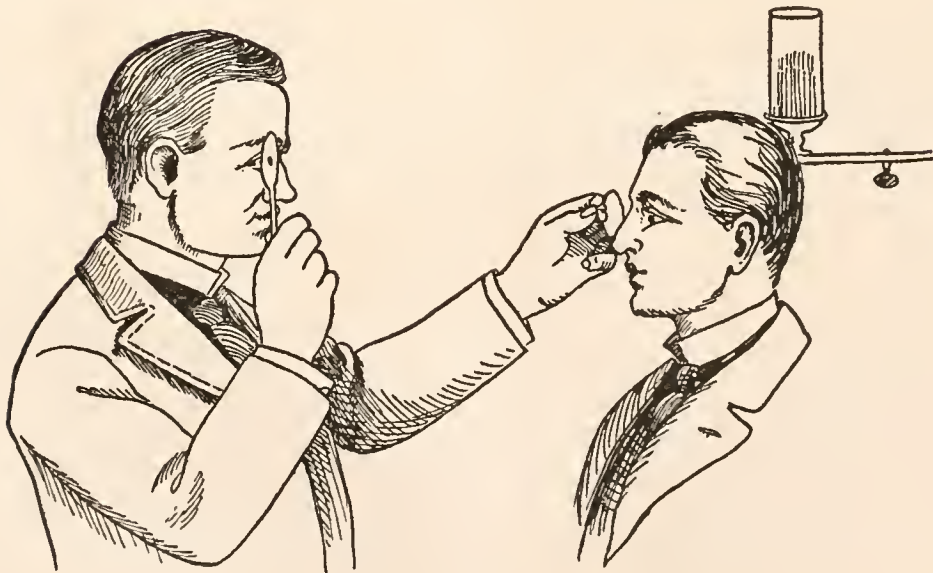


Fig. 19

Relative Positions of Examiner and Examined in Indirect Ophthalmoscopy

through the pupil is reflected by the structures of the background into the eye of the observer is the principle of the ophthalmoscope. Moreover, this reflection, or rather refraction, of the incident rays, modified by




Fig. 20

Morton Ophthalmoscope

the character of the media through which they pass furnish the wonderfully varied and colored pictures observed in the ocular backgrounds of all the vertebrates.

This brief account of the ophthalmoscope and its method of employment is offered for the benefit of those who have not used the instrument, but no description of ophthalmoscopy will much aid the zoologist in acquiring a practical knowledge of its application in the actual examination of animals' eyes even in the favorable surrounding of the darkened laboratory. Only a number of months spent in the exploration of the eyes of such domestic animals — including Man — as are most readily accessible and easily observed, followed by ophthalmoscopy of wild species obtained in field work, will make an expert of the student. While the writer will

not say that a practical knowledge of the ophthalmoscope is *essential* to the training of the scientific zoologist yet it is an instrument that furnishes precise and valuable information which the naturalist cannot afford to ignore.

A. *The Fundus Oculi or Background of the Internal Eye in Man.*

On account of the extensive literature on this subject and because the human fundus, normal and abnormal, has been carefully and thoroughly explored by many observers for over half a century no study of comparative ophthalmology is complete without at least a short account of the ophthalmoscopic findings in Man. In the writer's *Encyclopedia of Ophthalmology*, Vol. VII, p. 5315 *et seq.*, Moores Ball gives a good account of the beautifully colored ophthalmoscopic picture one sees in the depths of the human eye. The parts of chief interest in the human fundus are the optic disc, the blood-vessels, the macula lutea, and the choroid, and they furnish a satisfactory comparative study introductory to a consideration of avian fundi.

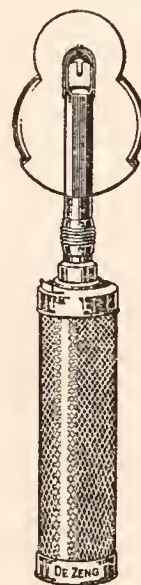

Fig. 21

Electric Self-luminous Ophthalmoscope (de Zeng).

The optic disc is situated about 3 mm. to the nasal side of the posterior pole of the eye, and is the point of entry of the optic nerve into the retina. It measures from 1.4 to 1.7 mm. in diameter and is generally circular or ellipsoidal in shape. Near its centre is a

depression, the physiologic excavation, which marks the divergence of nerve-fibres. The excavation is funnel-shaped, the base being anterior. A trace of the hyaloid artery of fetal life is occasionally seen here as a thread of connective tissue running from the papilla into the vitreous. Surrounding the papilla are two rings: an inner, due to exposure of

fibres, due to the fact that the medullary covering of the axis-cylinders exists in the fibre-layer of the retina. In such a case the fundus shows a patch of a brilliant white color extending out from the disc. Generally the white area is in contact with the disc. It rarely occurs that the opaque fibres are found at a great distance from the nerve-head or that they occupy a

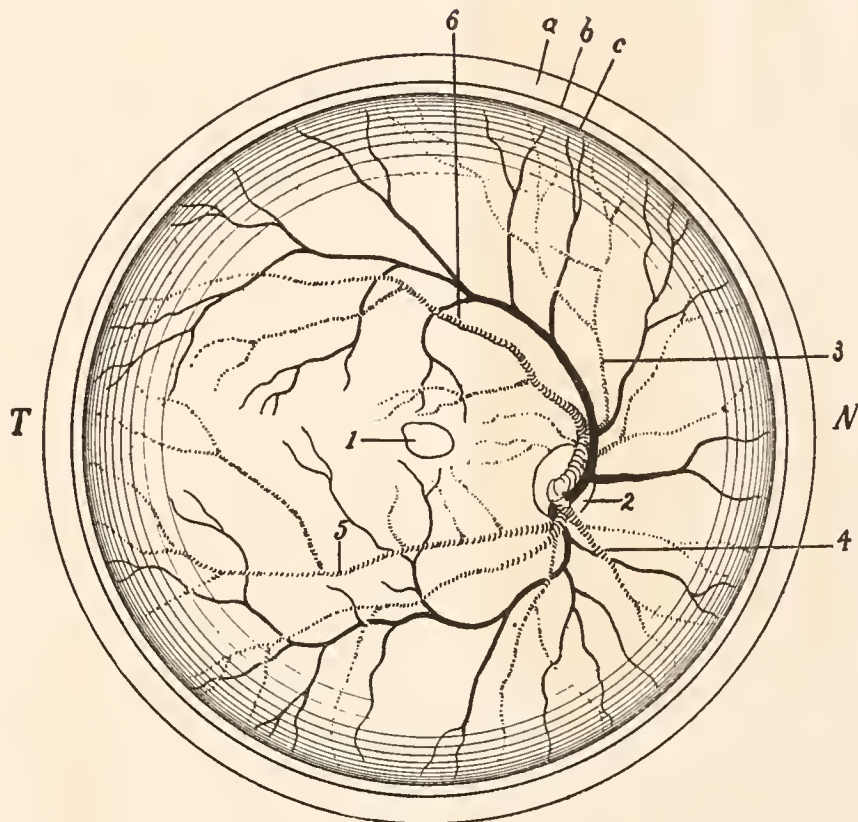


Fig. 22

Diagram Showing the Relations of the Parts in the Human Fundus Oculi. *a*, sclera; *b*, choroid; *c*, retina; *1*, macular region; *2*, optic disc; *3*, superior nasal artery; *4*, inferior nasal artery; *5*, inferior temporal artery; *6*, superior temporal artery; *T*, temporal side; *N*, nasal side.

the sclera, is whitish, and is called the scleral ring; and an outer one, due to the showing of choroidal pigment, is named the choroidal ring. At the bottom of the excavation a few dark spots are seen, from the gray stippling of the lamina cribrosa. In color the papilla is grayish-pink or reddish, and stands out in marked contrast to the reddish-yellow of the remaining parts of the fundus. The color of the papilla varies with the age and complexion of the individual, the color of the surrounding parts of the fundus, and with the illumination used. A common anomaly is the presence or persistence of opaque nerve-

large area of the fundus. The physiologic cup or depression may occupy a large part of the nerve-head, but never extends to the scleral ring. Under normal conditions many variations are seen in the size and depth of the cup and in the arrangement of the blood-vessels.

The *blood-vessels* are the central artery and vein of the retina. They run in the nerve-fibre layer of the retina, and often present variations of distribution. The middle of the *fovea centralis* has no blood-vessels.

While it is often stated that the retinal vessels can be seen on ophthalmoscopic examination, as a fact it is the column of blood

and not the vessel-wall, which is visible. In the larger retinal vessels the blood-column in the arteries is brighter than that in the veins. In the smaller branches this difference is less marked. The brighter color of the arteries is due to the presence of a central streak of light, which is less marked in the veins. The cause of this light-streak is not definitely known. The retinal artery, under normal conditions, rarely pulsates, but venous pulsation occurs spontaneously in from 60 to 75 per cent of normal eyes.

Besides the blood-vessels enumerated above, it is necessary to mention the *cilio-retinal vessels*. These are commonly small, solitary vessels which arise from the circle of Haller, and emerge at the temporal border of the disc. Such a vessel may come from the central vessel in the substance of the nerve, and may be of larger size. Generally it supplies blood to a small area between the disc and macula. Cilio-retinal vessels are present in from 10 to 16 per cent of normal eyes.

The macula lutea ("yellow spot" of Soemering) is situated about 3 mm. to the outer side of the optic-nerve head, and slightly below the horizontal meridian. It is a spot darker than the surrounding retina and apparently devoid of blood-vessels. It is the area of greatest visual acuity. The centre of the macula presents the foveal reflex, while the periphery shows a whitish, glistening ring, or halo, known as the macular reflex. Differences in the appearance of the macula in individuals are doubtless due to several (mostly domestic) causes: to the difference in methods of examination; to differences in the age, complexion, race, and refraction, as well as to variations in the distribution of pigment.

There are several forms of (ophthalmoscopically visible) *macular rings*. Lindsay Johnson states that the most common is a bright, scintillating reflex resembling shot-silk, very marked in dark eyes, scarcely visible in fair ones, and best seen with feeble illumination. This ring is supposed to be due partly to reflection from Müller's fibres, where they expand into the internal limiting membrane, and partly to the fibrous sheaths of the vessels which lift up the retina over-lying them.

The *foveal reflex* is found in the centre of the macula as a very small ring, or as a circular or horseshoe-shaped spot of light, or as a "comet-flare." It is due to reflection of the edge of the fovea.

The choroid. While each ocular tunic contributes something to the highly colored ophthalmoscopic picture, the chief part must be credited to the choroid. Light reflected from the mirror of the ophthalmoscope passes through the transparent part of the retina to the pigment epithelium, and is partly absorbed, partly reflected. Although the pigment layer belongs embryologically to the retina, it generally adheres to the retinal surface of the choroid, and is accredited ophthalmoscopically to the latter tunic. The brightness of the fundus picture depends on the amount of pigment. The greater the pigment, the greater the absorption of light and the darker the fundus picture. In the negro and the native of India the fundus is of a brownish, brown-red, or slate color, while in the Anglo-Saxon, and particularly in blondes, it is of a bright-red color. If the pigment layer is very thin, the choroidal vessels are correspondingly exposed and are seen as a network of large, flat vessels, without a light-streak, between which are spaces of light or dark color. They are seen best in albinos. It is generally impossible to differentiate between the choroidal arteries and veins, although at the equatorial region the latter converge to form the *venæ vorticosæ*. In brunettes the vessels appear as "light streams separated by dark islands," because the spaces are more deeply colored than the vessels.

The sclera, which may be spoken of as the panel on which the fundus picture is painted, is commonly invisible, being covered by the nearly opaque choroid. Yet it is probable that in all eyes some light passes through the choroid, and thus the sclera has some influence on the ophthalmoscopic picture, serving to make it lighter. In albinos the sclera appears as a white surface between the choroidal vessels. It is best seen where the choroid is absent, as in coloboma, or pathologically as a result of destruction of the retina and choroid.

CHAPTER VI

OPHTHALMOSCOPY OF THE FUNDUS IN LIVING BIRDS

THE method employed by the writer in examining the background of the eye in living Birds does not much differ from that of the physician in his examination of human eyes as described in the previous chapter.

For a proper exploration of the vertebrate fundus it is, as previously stated, highly desirable that the pupil be widely dilated. This is accomplished in Man and other Mammals by such mydriatics as atropin, homatropin, euphthalmin, etc., which bring about an enlarged pupil mainly by inhibiting the action of the non-striated sphincter muscle fibres of the iris. In Birds, however, these agents have little *direct* effect on the striated, voluntary, sphincter musculature of the iris; hence they are of little value in an ophthalmoscopic examination of most Birds. One is obliged, therefore, to resort to such agents as galvanism, nicotine, strophanthin, curare, stipticin, etc., and to such drugs (eserin, atropia) as render the bird unconscious without actually killing it.

In collecting the heads of birds for macroscopical and histological studies the writer found that satisfactory ophthalmoscopic views of the fundi can be had a few minutes before and after the death of the specimen, during which period the pupil not only dilates *ad maximum* but the bird does not use his third eyelid. Many of the appended reports were gathered in this way.

Owing to the peculiar arrangement of their lacrimal apparatus (see the writer's work on this subject) fluids instilled into the eye (conjunctival sac) of Birds run immediately into the throat and gullet, there to be absorbed and to produce precisely the same systemic effects as if they were poured directly down

the throat of the animal. Great care should be used, therefore, in using eye drops for their expected effect upon the visual apparatus; if poisonous for the bird they may cause his death in short order, and rare and valuable specimens may be sacrificed to the ignorance of the observer. The writer has not the least doubt but that some of the so-called mydriatics or pupil-dilating drugs recommended for an examination of the ocular interior of the Bird act as systemic intoxicants and not specifically upon the iris muscles, as is the case with the mammalian eye.

As an example of this action of the so-called mydriatics on the eyes of birds the writer once fell into the same error as other still earlier observers in attempting to dilate by atropia the pupils of a Yellow Parakeet (*Melopsittacus undulatus*). This bird was an adult individual, sex unknown, in captivity for six months. In dull light the pupils were 2.5 mm. wide, contracting irregularly to 1.5 mm. A single drop of a 1% solution of atropia sulphate put into the eyes apparently dilated the pupils *ad max* (3 mm.) in 12 hours, but as the bird was taken ill a few hours following the instillation (stupor, vertigo, quick, weak heart and final unconsciousness) and died 30 hours after the use of the drops, it is quite likely that its death was due to the poison that ran into its throat from the conjunctival sac. The writer had a similar experience with a number of other birds.

The following notes were made of experimentation intended to determine the best mydriatic for the Bird's eye, especially for field work.

Laboratory Notes of Experiments on the Pupils of Passer domesticus. One drop of

a 1% mixture of *curare* put into left eye of three adult English Sparrows, two ♂, one ♀, at 11 A. M. Thursday, March 28, 1912. Result negative at twelve o'clock.

April 1, 1912. Put one drop of ½% *nicotin* into the left eye of two Sparrows, adults, one ♀, one ♂, at 9:35 A. M. Pupils in each case — half light — were 2 mm. in diameter before the instillation. 10:15 A. M., no effect as to dilation or reflex to light in ♂, so then put in one drop of 1% *nicotin*. Bird became slightly "groggy" in 4 minutes. 10:20 A. M. ♀, left pupil barely dilated more than right, instilled 1 drop 1% solution *nicotin*: no general effect in 5 min. 10:25, ditto ♂. 11:30, very slight, if any difference in pupils. 2:25 P. M., same day, put a drop of 2% into left eye of same ♀ and ♂ sparrows. They both became quite "groggy" in one minute but recovered in five minutes so as to sit up and fly easily about the cage. At 2:40 P. M. no change in pupil. 3:10 P. M., both birds quite lively and both left pupils dilated to 3 mm. At 4:30 ♂'s pupil dilated; ♀ normal. Both birds normal.

April 4, 1912. Put one drop of 2% *nicotin* into left eye of ♀ at 10:40 A. M. Bird intoxicated in 2 min. but revived in 5 min. Second drop at 10:50: bird very "groggy" in 2 min.; lay on its back in 3 min. breathing with difficulty, dead in 4 min.; widely dilated pupil left; semi-dilated right.

March 30, 1912, 3:30 P. M. Put one drop of 1% *nicotin* into the left eye of three adult ♀. All became more or less "wobbly" in two minutes, recovering almost entirely in 15 minutes. At 4 P. M. the pupils, left, were all three dilated *ad max.*, although when exposed to the diffuse light of a north room they contracted; almost to normal in a very bright light. At 4:30 P. M. the pupils were all normal except one, left, pupil which was slightly and continuously dilated, and not much affected by strong light. Put one drop of a two per cent solution of *nicotin* into left eye of two adult ♀ at 12 o'clock. One died in 15 minutes, under complete collapse. The other became very stupid and laid on her stomach for ½ hour, after which she revived but was not as lively as before. At 2 P. M.

the left pupil of living Sparrow was dilated *ad max.*, and but slightly affected by light. Right pupil unaffected at 4 P. M.; both pupils normal at 4 P. M.

March 26, 1912. Examined pupils in one ♂ and two ♀ 1½ to 2½ mm. in diameter. They contract promptly in light to 1 mm. *Nicotin*, both 1% and 2%, seems to "daze" the birds. One drop of each solution, put into the right eye caused paresis of lower lid but not of nictating membrane; dilation of pupil in 20 min. to 4 to 5 mm., which remained in this condition for at least 1½ hours. Left eye as before. In 2½ hours pupils normal again. Bright light focused on dilated pupil caused a contraction to 3 mm. which instantly recovered to 5 mm. on medium illumination. After 1½ hours 2% *nicotin* dilated right eye of ♀ to 6 mm. and it was then only slightly affected by bright light. One drop of a 2% *pilocarpin hydrochloride* put into left eye of 3 adult English Sparrows, two ♀ and one ♂, at 11:25 A. M., March 28, 1912. Negative results at 12:00.

In other words, one per cent solution of *nicotin* brings about a dilation of the avian pupil that persists for several hours, and is probably the best agent one can use for the purpose.

Experience has proved that the *self-luminous, electric ophthalmoscope* having a small eyehole in a "split" mirror is the best instrument for exploring the avian fundus. Such an instrument is described in Chapter V, and there depicted as Fig. 21.

After a careful inspection of the anterior parts of the eye, both without and with a lens (to make sure that there is in the observed eye no obstruction to an examination) the observer should seat himself on a chair in a dark room. Then, holding the instrument against his own eyebrow with one hand and a +20D. glass with the other hand, focus the light from the ophthalmoscope, held at a distance of about 40 cm., or 18 inches, from the bird's eye, through the dilated pupil and upon the fundus of the bird, firmly held by an assistant seated opposite.

In *field work* both the observer and his assistant may kneel on the earth under a

large, black umbrella, or make the examination in a darkened tent; in public or private aviaries the examination can often be made after sundown.

A four dioptré convex lens must be placed in front of the eyehole of the mirror. This

species that present invariable ophthalmoscopic pictures. It will be found that after two or three generations of inbreeding, confinement and domestication, changes occur in the ocular apparatus coincident with variations in other parts of the organism.

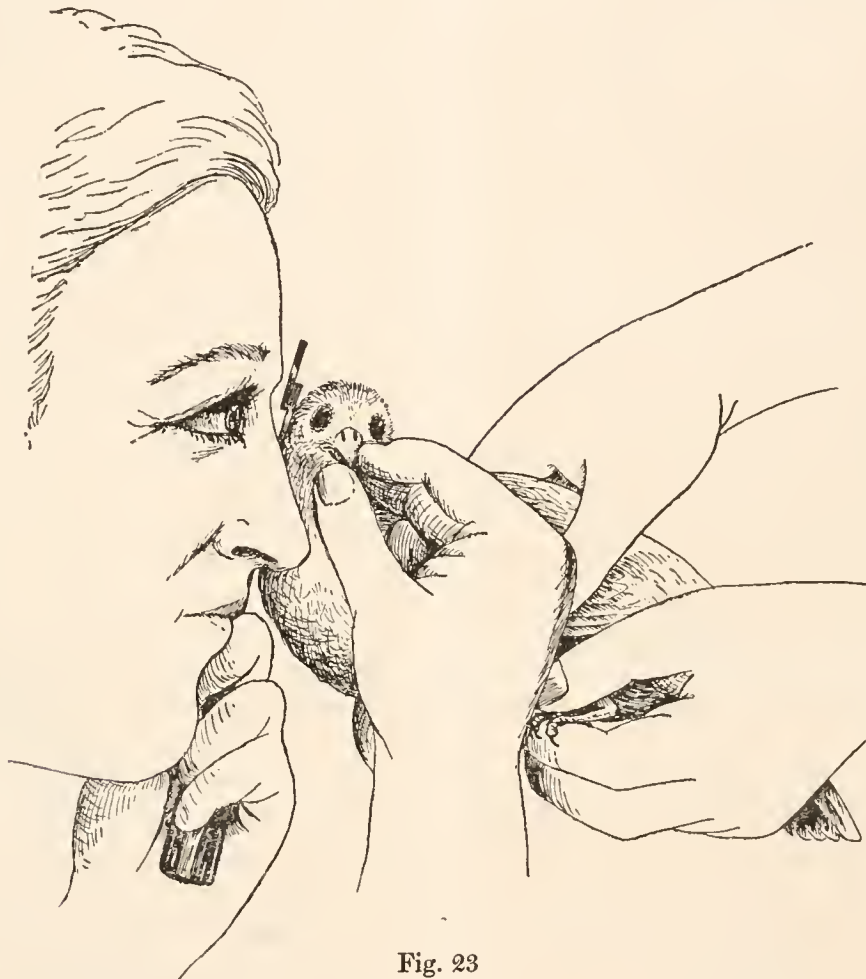

Fig. 23

Method of Examining the Bird's Eye with the Self-luminous Electric Ophthalmoscope.

“*indirect*” method (see, also, page 29) gives a comparatively small, inverted image of the ocular fundus. It corresponds to the low power lens which one uses in the preliminary examination of a microscopical section.

The *examination by the erect image* will, on the whole, be found the most satisfactory method, although, as in viewing the human fundus, it is advisable to use the indirect plan at the outset. The self-luminous ophthalmoscope is quite satisfactory for both these purposes.

In making an examination of the avian fundus it must be remembered that it is *wild*

The facility (or otherwise) with which the ophthalmoscope can be used depends, in a large measure, upon the conduct of the bird under examination. For instance, it is important that the macular region be carefully explored and it can generally be seen, but throwing the light on this very sensitive area often makes the animal restless and the greatest gentleness should be observed to keep it quiet if a complete examination is to be made. Most specimens, not excepting the Eagles, Hawks, Vultures and other large birds can be hypnotized and so quieted for the period of an ophthalmoscopic examination.

To this end the assistant must, at first, quietly but firmly hold the mandibles with one (gloved) hand, the other pressing claws and wings against his chest. In a few minutes the bird ceases to struggle; the assistant's grasp of the bird is then slowly relaxed; the bird relaxes its muscles, no longer resists the attempt to examine it and the head can usually be turned in any desired direction to suit the observer. See Fig. 23.

There is sometimes difficulty in seeing the fundus of the bird because of frequent winking of the bird's nictitating membrane (rarely through shutting of the true lids) and because of occasional contractions of the pupil (unless it is artificially dilated) but these difficulties are, with time and patience, surely overcome — and almost always without damage to the bird, the observer or his assistant. Some birds, Cormorants, for instance, resist attempts to quiet them and become wild and restless when the light from the ophthalmoscope falls on the macular region; others, like the Raven, remain quiet for irregular periods during the examination but intelligently await an opportunity to use bill and claw on the captor.

As an extended study of the eyes of living birds is not without its dangers, both the student and his assistant should wear leather gloves during the ophthalmoscopic examination and should especially be on guard against facial bites, stabs and scratches — from the mandibles and talons of Raptores and Parrots in particular. In addition to these accidents, one of the writer's assistants was severely bitten by a European Raven, another was badly kicked by an Ostrich, while the writer himself barely escaped the loss of an eye from a stab on the margin of the orbit inflicted by the pointed beak of a Little White Heron.

Reference is elsewhere made to the possibility of quieting or even of hypnotizing birds for the purpose of making an ophthalmoscopic examination. In some cases flashing the light of the ophthalmoscope into the animal's eyes produces a quieting effect.

The writer has had many such experiences but he here relates only one. Assisted by Head-Keeper Pitts of Bentley's California

Ostrich Farm and several San Diego colleagues he examined, in 1912, a young, adult ostrich, six feet high, healthy and very vigorous. The bird resisted capture and was thrown only after a struggle. A keeper sat on his prostrate body; another held his head and neck. After the light of a self-luminous skiascope had played over his dilated pupils in a darkened room for about five minutes he acted as if he were in a trance; he remained in the prone position without being held and a complete examination of his pupil reflexes, static refraction, fundus appearances, etc., was made without difficulty. Finally, after about 20 minutes or half an hour (when this inquiry was completed) the bird refused to move or rise — and had to be pushed to his feet — after which he became his lively self again.

The small pupils of Wrens, Nuthatches, the smaller Warblers, Hummingbirds, etc., even when fully dilated, make it extremely difficult to view the fundus during the life of the bird and tax the perseverance of the observer to the utmost. It is, perhaps, well not to attempt such tasks until the ophthalmoscopist has had a year or two of experience. Annoying, also, are the fugitive reflections and "shot-silk" colors that play over the retinal areas in some birds, but even these fail to obscure the fundus picture after some months of practice.

The task of *picturing the avian background for the purpose of conveying an intelligent idea of its appearance* is a serious one; indeed, with all the work done upon the eyes of Birds, this method has been almost entirely neglected. The ophthalmologist may be a good observer but a poor artist; conversely, an expert in the use of brush and pencil may not be sufficiently conversant with normal and pathological, human and comparative ophthalmoscopy and ophthalmology to enable him to make an intelligent use of his artistic talents. These difficulties have been, in this research, largely met by an arrangement with Mr. Arthur Head, F. Z. S., the well-known London artist, who for some 20 years past has been painting both human and animal fundi for confreres here and abroad. This artist and the writer have together examined and discussed in the

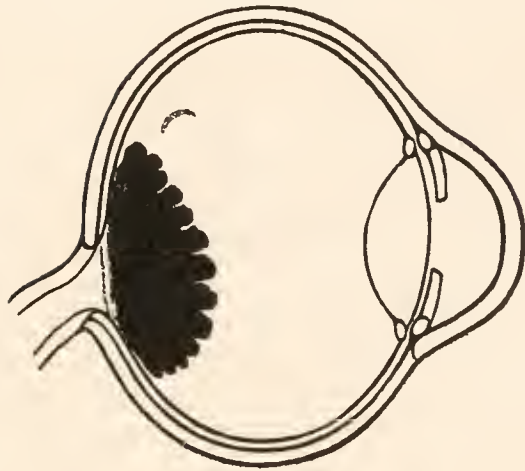


Fig. 24.

Nubian Ostrich (*Struthio camelus*).

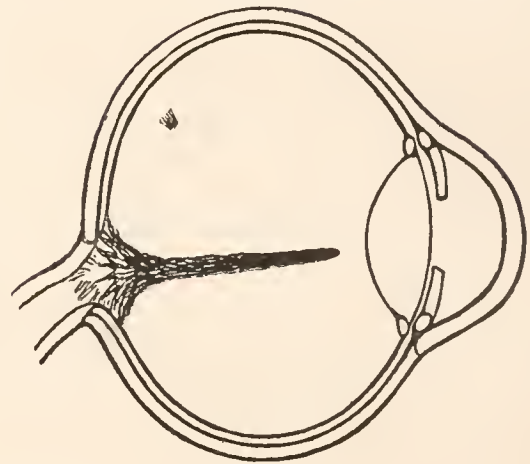


Fig. 27.

Kiwi or Apteryx (*Apteryx mantelli*).

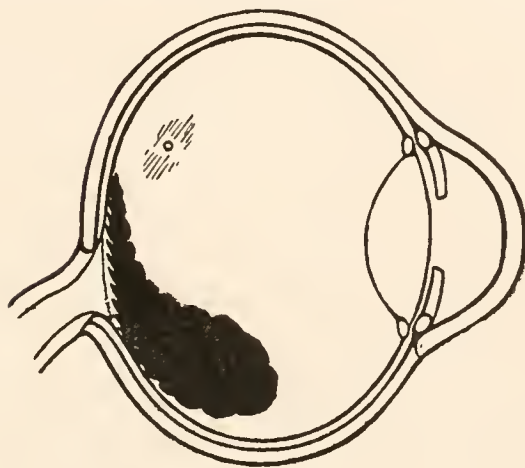


Fig. 25.

American Ostrich (*Rhea americana*).

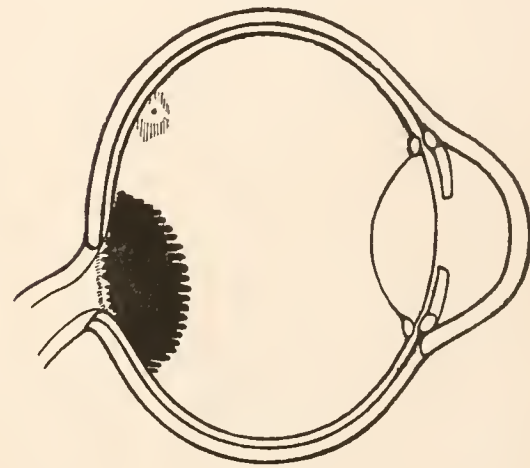


Fig. 28.

Martineta Tinamou (*Calodromas elegans*).

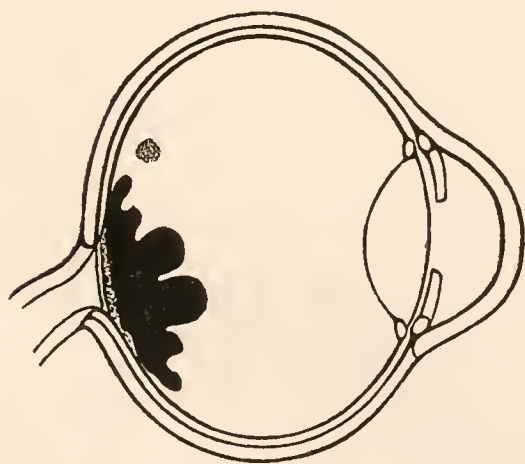


Fig. 26.

Westerman's Cassowary (*Casuaris occipitalis*).

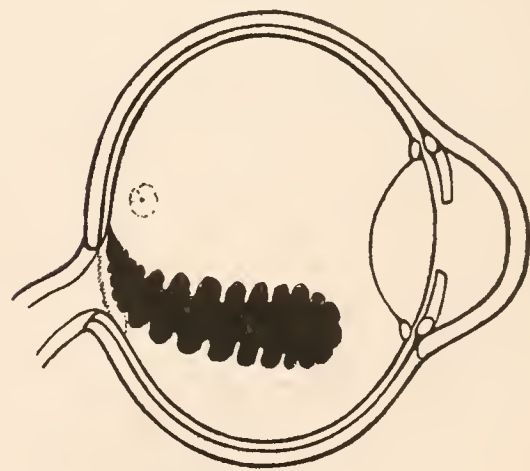


Fig. 29.

Brazilian Seriema (*Cariama cristata*).

Diagrams of the Pecten as seen by the Ophthalmoscope in Various Species of Birds.

Gardens of the London Zoological society the ophthalmoscopic appearances of several hundred avian and other eyes. The details of these fundus views, as revealed by the ophthalmoscope in many species, are described and depicted in Chapter X and elsewhere.

A. *The Avian Eyeground in General.*

The average eyeground or fundus oculi of most Day Birds resembles, as much as anything, the texture of the so-called "scotch mixtures" in smooth finished cloth — usually light brown, gray, gray-blue, blue mixed with striate rays, or fine concentric marking of lighter gray or white. Scattered over this background are numerous yellowish, yellow-white, brown or gray points of pigment. Although this matter has not yet been satisfactorily determined yet these punctate deposits are, in part at least, the colored oil droplets described in Chapter IV.

Nocturnal Birds have, almost invariably, yellow-red, orange, orange-red or reddish brown fundi, with the choroidal vessels plainly visible through the semitransparent retina. Some of the Owls present almost a scarlet vermilion eyeground, and this intensity of colors appears to be peculiar to Strigiformes. For this reason alone might say with confidence that the New Zealand Owl Parrot (*Stringops habroptilus*) belongs to this order and not to Psittaciformes or to Cuculiformes in one of which he is commonly placed.

Ophthalmoscopy of the areas of distinct vision in Birds supplements the macroscopic and microscopic examination. In many instances it affords a better idea of the relations of these areas than does any other means of observation; at least this is true of most avian fundi explored by the writer. As a rule the deep, single fovea and its surrounding macular region are, other conditions being favorable, readily observed by means of the mirror, and their locality, comparative size, component parts, coloration, etc., easily depicted. Contrariwise, a shallow or organically ill-defined "yellow spot" is not so readily made out. Band-like areas are also better defined by the aid of a magnifying glass and in prepared half-eyes, although in the fundus of the Secretary Bird (Plate XXXI), of the White-

bellied Sea Eagle (Plate XXXIV) and of a number of other bimacular species the ribbon of tissue is well shown by the mirror.

With, perhaps, this exception the macroscopic description of the areas centrales given not only in the lists of Chievitz and Slonaker but in Chapter VII corresponds in a remarkable fashion with the ophthalmoscopic findings described and depicted in this work. Nothing has been discovered in this study of the avian fundus by the aid of the mirror that is likely to add to or subtract from the classification of the types of central vision suggested by the writer in the same Chapter.

The Pecten and Optic Disc

Viewed ophthalmoscopically the avian mar-supium or pecten exhibits three fairly definite varieties which may be classified as follows:

I. *Those pectens whose mass uniformly springs from and equally covers the optic disc.* Such pectinate bodies do not extend into the vitreous cavity farther than the length (often less) of their widest segment, and they are sessile on the face of the papilla. Examples of this form of pecten are seen in *Nycticorax nycticorax* (Fig. 45), *Haliaëtus leucocephalus* (Fig. 56), *Caprimulgus europæus* (Fig. 65), *Strix flammea* (Fig. 59), *Serpentarius* (Fig. 52), *Struthio camelus* (Fig. 24), *Cancroma cochlearia* (Fig. 46), *Casuarus occipitalis* (Fig. 26), *Spheniscus demersus* (Fig. 37), *Tinnunculus alaudarius* (Fig. 55), *Calodromas elegans* (Fig. 28) and *Syrnium aluco* (Fig. 58). This method of arranging the pectinate tissues makes provision for a blood reservoir large enough to supply nutritional needs but so placed that it does not materially obstruct visual or light rays. Such a disposition and configuration of the fundal organs meet the needs of many species, among them Eagles and Owls, who require (and have) very acute vision.

II. *Some pectens, while they originate from the whole surface of the optic disc, immediately slope away from the visual axis, approach the bulbar wall and terminate without projecting far into the vitreous.* In this type there is generally a disc-length or more between the free terminal of the pecten and the posterior surface of the crystalline lens.

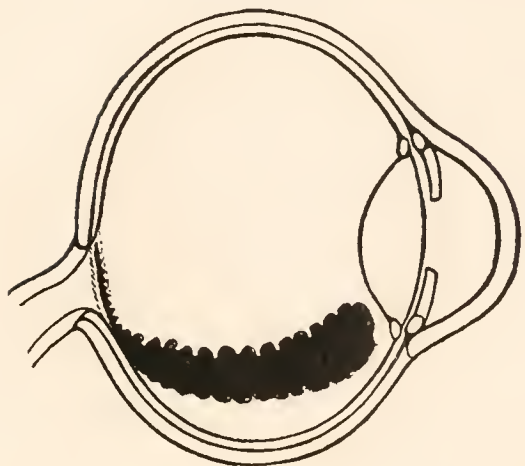


Fig. 30.

Harlequin Quail (*Coturnix histrionica*).

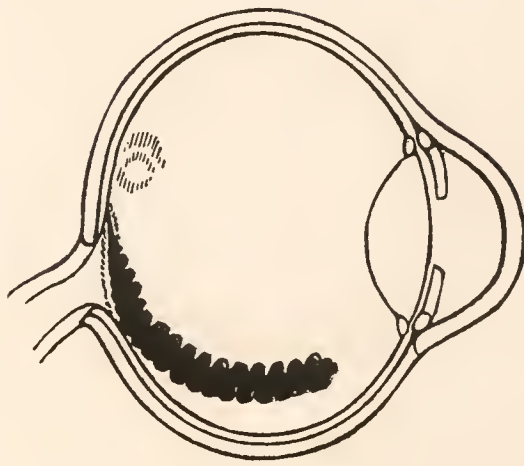


Fig. 33.

Common Wood Pigeon (*Columba palumbus*).

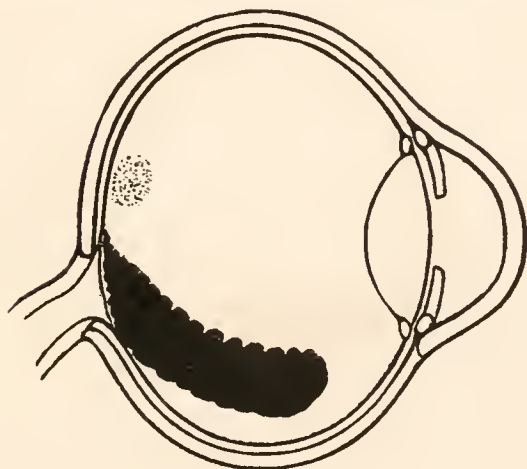


Fig. 31.

Brush Turkey (*Cathartus lathami*).

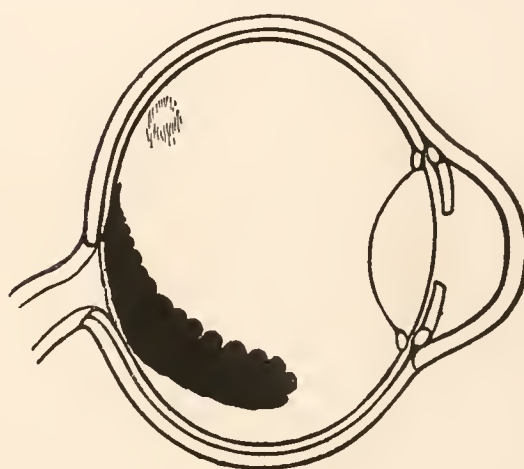


Fig. 34.

Victoria Crowned Pigeon (*Goura victoria*).

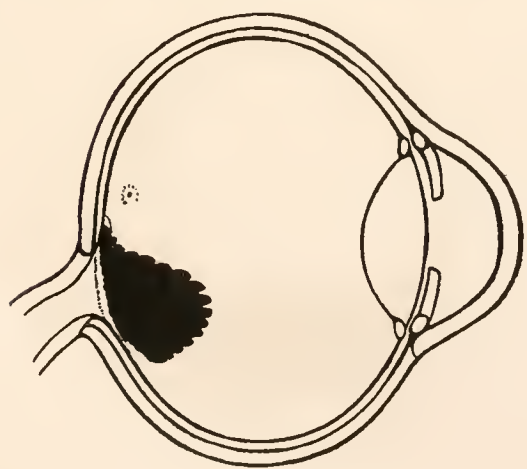


Fig. 32.

Yarrell's Curassow (*Crax globosa*).

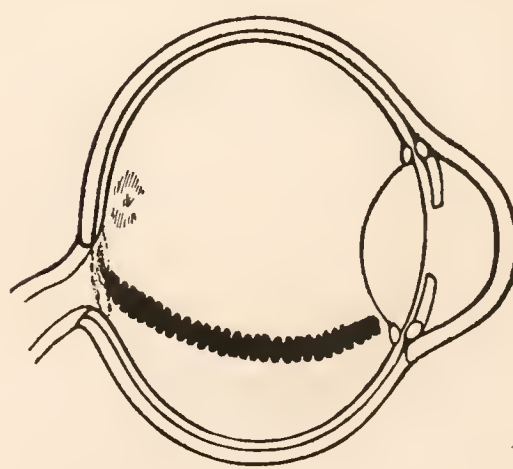


Fig. 35.

Wonga Wonga Dove (*Leucosarcia picata*).

Diagrams of the Pecten as seen by the Ophthalmoscope in Various Species of Birds.

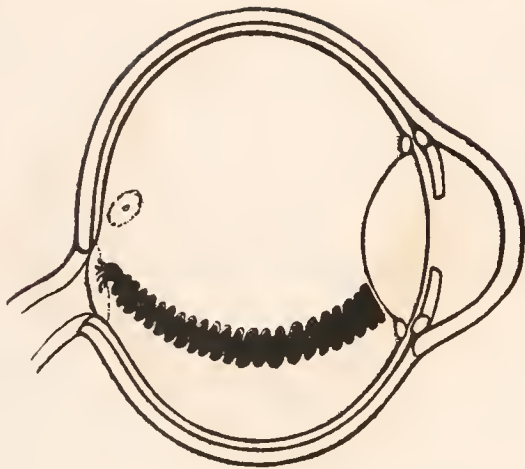


Fig. 36.

Ipecaha Rail (*Aramides ipecaha*).

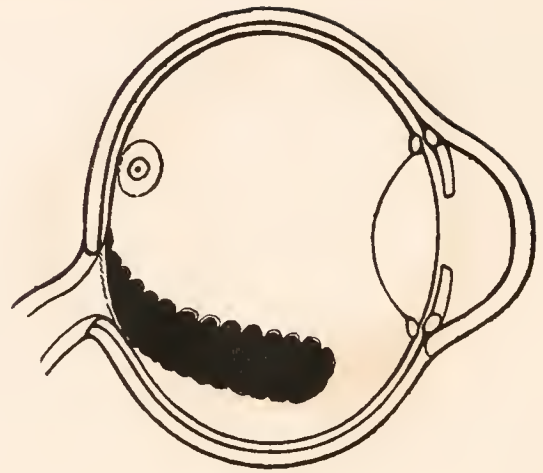


Fig. 39.

Herring Gull (*Larus argentatus*).

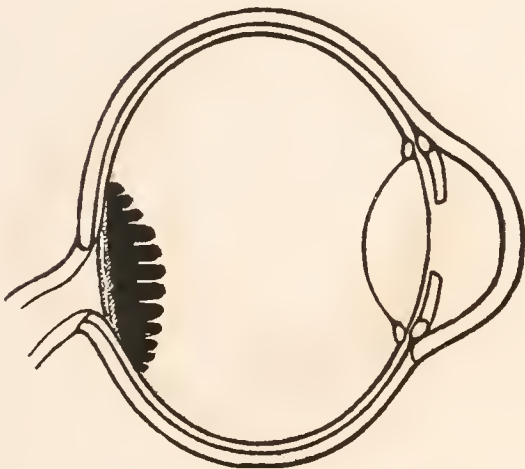


Fig. 37.

Black-footed Penguin (*Spheniscus demersus*).

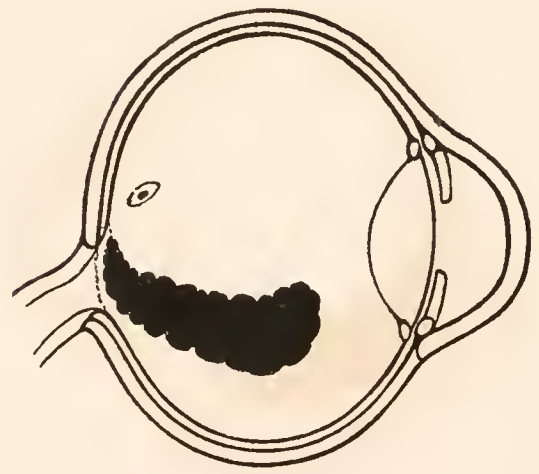


Fig. 40.

Great Black-backed Gull (*Larus marinus*).

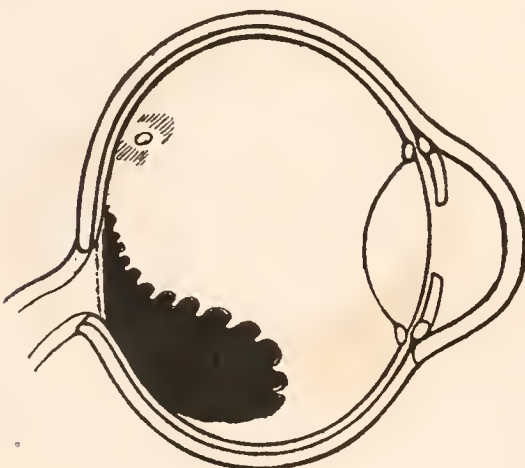


Fig. 38.

Puffin (*Fratercula arctica*).

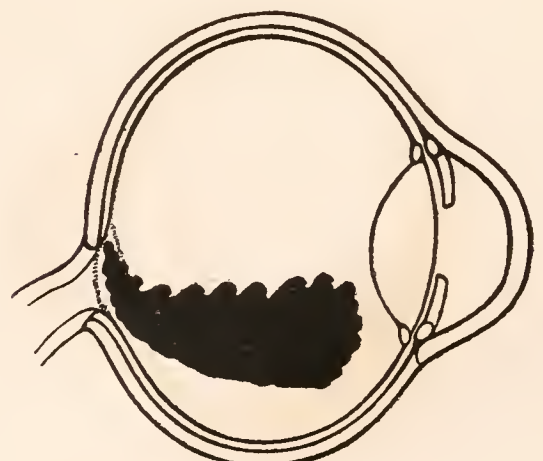


Fig. 41.

Stone Plover (*Oedinenus scolopax*).

Diagrams of the Pecten as seen by the Ophthalmoscope in Various Species of Birds.

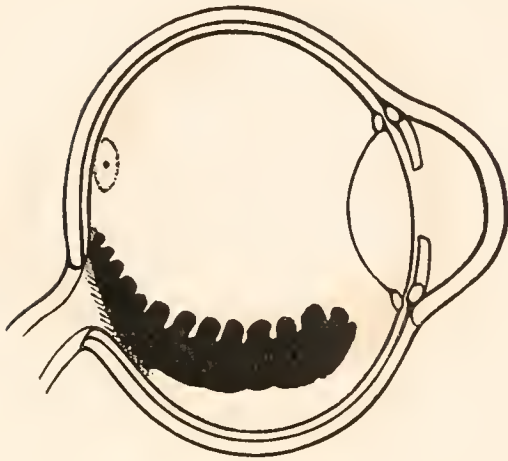


Fig. 42.

Little Bustard (*Tetrax tetrax*).

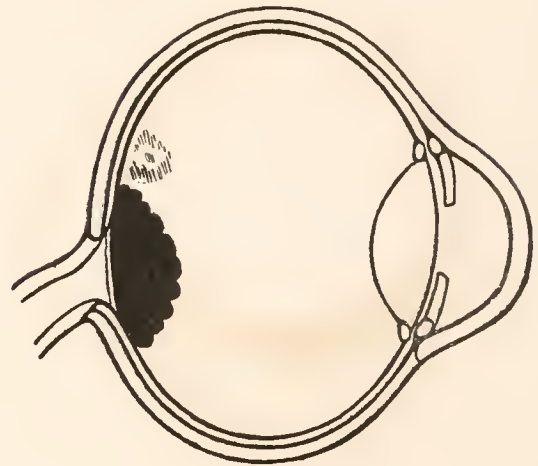


Fig. 45.

Night Heron (*Nycticorax nycticorax*).

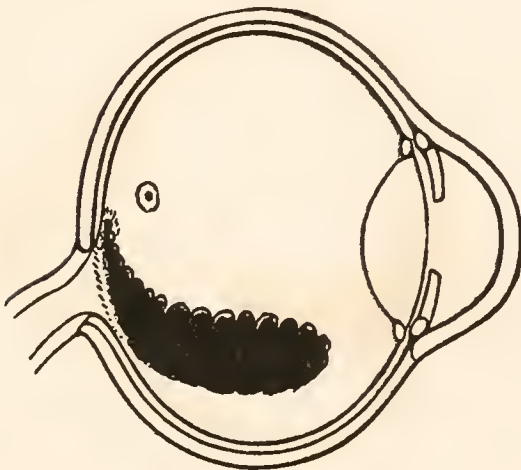


Fig. 43.

Kagu (*Rhinochetus jubatus*).

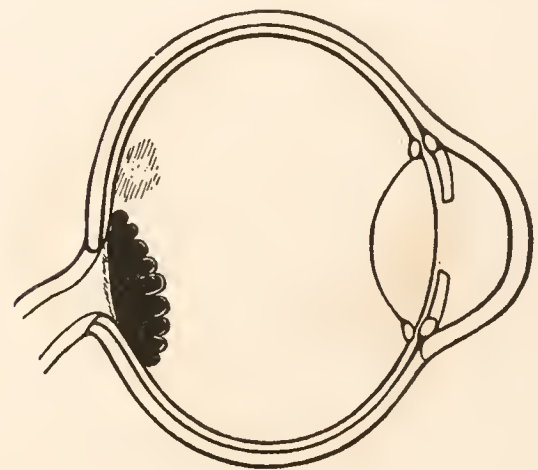


Fig. 46.

Boat-billed Night-Heron (*Cancroma cochlearia*).

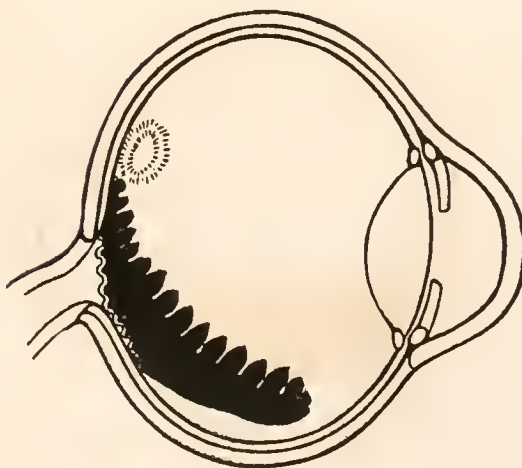


Fig. 44.

European Bittern (*Botaurus stellaris*).

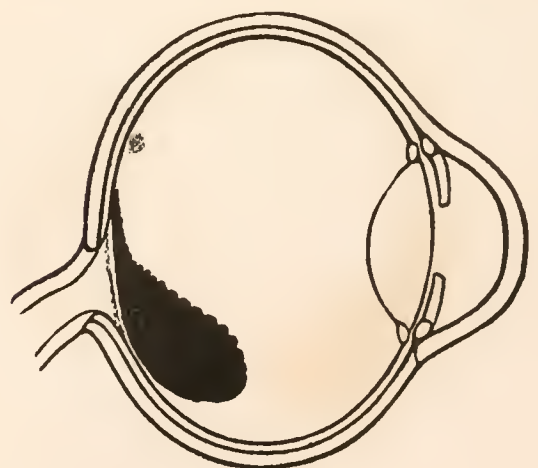


Fig. 47.

American Jabiru (*Mycteria americana*).

Diagrams of the Pecten as seen by the Ophthalmoscope in Various Species of Birds.

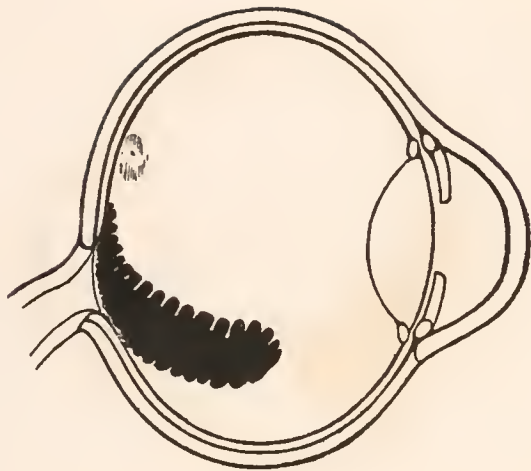


Fig. 48.

Blue Snow Goose (*Chen caerulescens*).

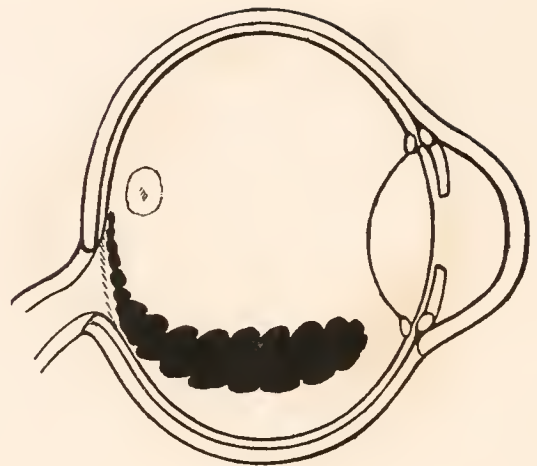


Fig. 51.

Cormorant (*Phalacrocorax carbo*).

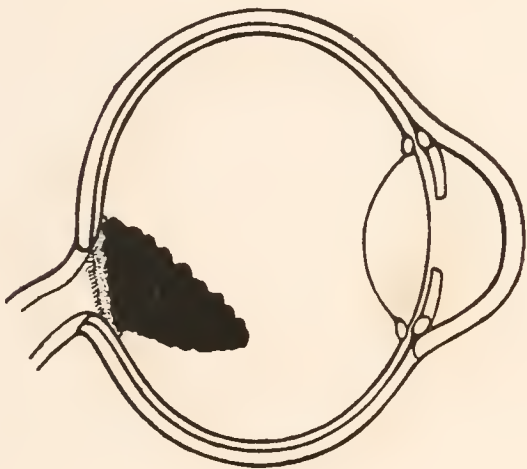


Fig. 49.

Red-billed Tree Duck (*Dendrocygna autumnalis discolor*).

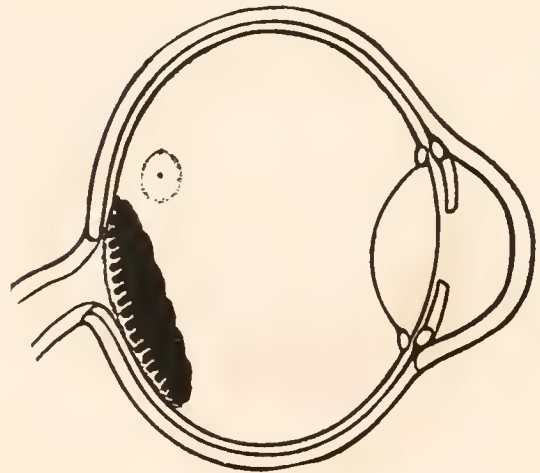


Fig. 52.

Secretary Bird (*Serpentarius cristatus*).

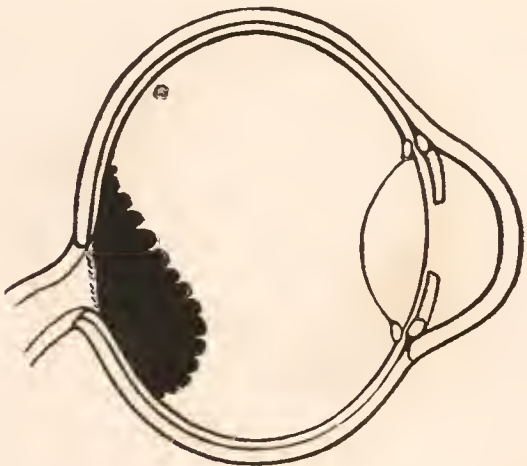


Fig. 50.

Gannet (*Sula bassana*).

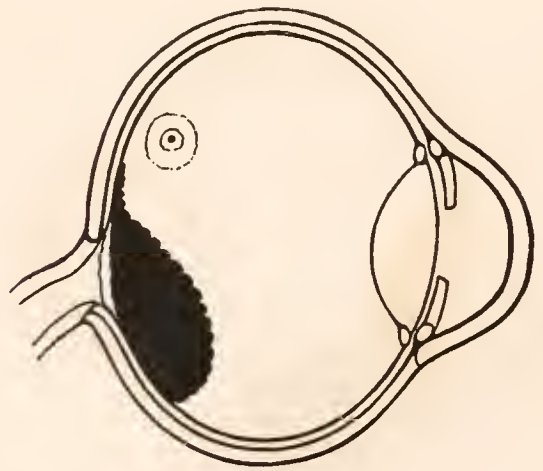


Fig. 53.

Lämmergeier (*Gypaëtus barbatus*).

Diagrams of the Pecten as seen by the Ophthalmoscope in Various Species of Birds.

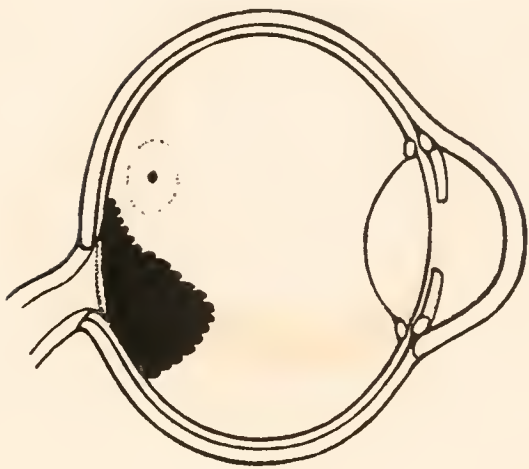


Fig. 54.

White-bellied Sea Eagle (*Haliaeetus leucogaster*).

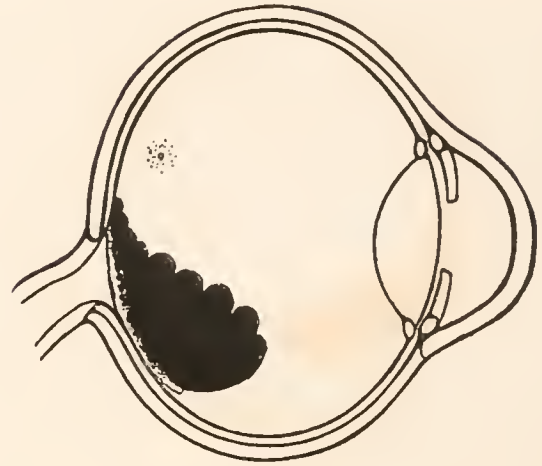


Fig. 57.

Burrowing Owl (*Speotyto cunicularia*).

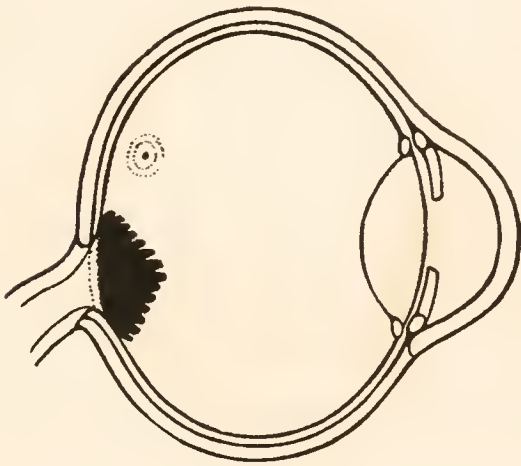


Fig. 55.

Common Kestrel (*Tinnunculus alaudarius*).

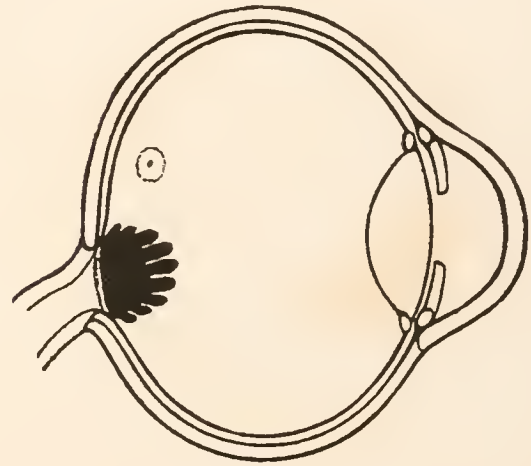


Fig. 58.

Tawny Owl (*Syrnium aluco*).

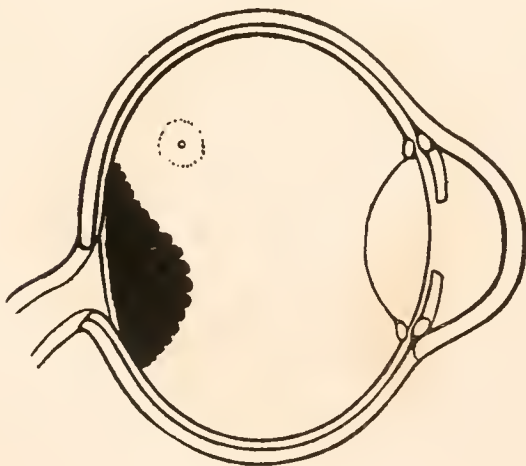


Fig. 56.

American Bald Eagle (*Haliaeetus leucocephalus*).

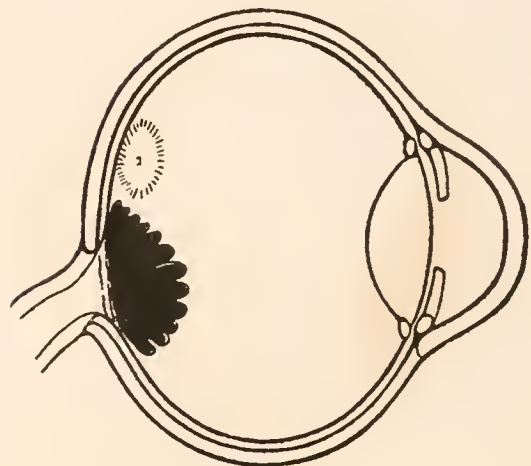


Fig. 59.

British Screech-Owl (*Strix flammea*).

Diagrams of the Pecten as seen by the Ophthalmoscope in Various Species of Birds.

One finds examples of this form in *Columba palumbus* (Fig. 33), *Cuculus canorus* (Fig. 66), *Cathartus lathamii* (Fig. 31), *Larus argentatus* (Fig. 39), *L. marinus* (Fig. 40), *Rhinocetus jubatus* (Fig. 43), *Goura victoria* (Fig. 34), *Chen cerulescens* (Fig. 48), *Mycteria americana* (Fig. 47), *Speotyto cunicularia* (Fig. 57), *Stringops habroptilus* (Fig. 62), *Chrysotis amazona* (Fig. 60), *Rhea americana* (Fig. 25), *Sula bassana* (Fig. 50), *Haliaëtus leucogaster* (Fig. 54), *Cacatua galerita* (Fig. 61), *Dendroma autumnalis discolor* (Fig. 49), *Crax globosa* (Fig. 32), *Fratercula arctica* (Fig. 38), *Dacelo gigas* (Fig. 63), and *Botaurus stellaris* (Fig. 44).

III. This class includes those pectens (usually of slender proportions) that arise from the whole surface of the optic papilla and, then, either curve towards and follow the concave wall of the eyeball or they proceed in a straighter line until they touch (or nearly reach) the posterior surface of the lens, generally near its equator. In most instances there is less than a disc length between the pecten terminal and the lens capsule. To this class belong the pectens of *Hirundo rustica* (Fig. 71), *Leucosarcia picata* (Fig. 35), *Cyanospiza versicolor* (Fig. 73), *Mimus polyglottos* (Fig. 72), *Spagolobus adratus* (Fig. 64), *Xanthura cyanocitta* (Fig. 75), *Aramides ipecaha* (Fig. 36), *Apteryx mantelli* (Fig. 27) and *Coturnix histrionica* (Fig. 30).

These are many species whose pectens occupy a position intermediate between Class II and Class III, and which are consequently, not easy to place. Of those that are figured in the text may be mentioned *Rhamphastus laematus* (Fig. 67), *Otis tetrax* (Fig. 42), *Dendrocopus major* (Fig. 68), *Phalacrocorax carbo* (Fig. 51), *Corvus corax* (Fig. 76), *Centurus uropygialis* (Fig. 69), *Pitangus derbianus* (Fig. 70) and *Cariama cristata* (Fig. 29).

Opaque nerve-fibres. As previously stated, the neurilemma, or nerve-sheath, of the opticus is in many Birds, as occasionally in Man, continued into the retinal substance. These nerve-fibres are easily seen in the avian fundus when viewed with the ophthalmoscope, although in preserved eyeballs they are invisible to the naked eye.

In some instances they radiate from the nerve-head as whitish, thread-like rays, in such a fashion as to cover the whole of a wide area about the optic entrance. This condition is well shown in *Turdus merula* (Plate LVII), *Spagolobus adratus* (Plate XLIII), *Rhamphastus laematus* (Plate XLVI), *Plegadis falcinellus* (Plate XXIII), and *Tinnunculus alaudarius* (Plate XXXV).

As a rule, however, the avian fundus is free of these nerve elements; in all probability they interfere to some slight extent with general retinal vision and are consequently absent in those genera requiring the most acute visual powers. They are few in number or are entirely absent in Night Birds, and in such representative species as *Gypaëtus barbatus* (Plate), XXXII *Casuaris occipitalis* (Plate III), *Haliaëtus leucocephalus* (Plate XXXIII) and *Rhinocetus jubatus* (Plate XVIII).

They are short or inconspicuous in all the acarinate birds, so far examined, including the Tinamou (Plate V) as well as in *Nycticorax nycticorax* (Plate XX), *Crax globosa* (Plate VI), *Coturnix histrionica* (Plate VIII) and *Phalacrocorax carbo* (Plate XXVIII).

E. Photography of the Fundus Oculi in Living Birds

Many attempts have been made to photograph the fundus oculi through the pupil in living subjects—to combine, as it were, photography with ophthalmoscopy. If this scheme is ever put into practical operation, especially if it be found possible to photograph the eyeground in its natural colors so that the negative can be reproduced and published, a great advance will be made over the restricted (because slow and expensive) plan per force adopted by the writer. Photography of the colored details of the fundus would render unnecessary either the expert ophthalmologist or the trained artist, while the number of avian backgrounds explored by such exact methods would soon be counted by hundreds where they are now registered by units. Moreover, as the ophthalmoscopic picture is to a certain extent differently interpreted, and correspondingly described and

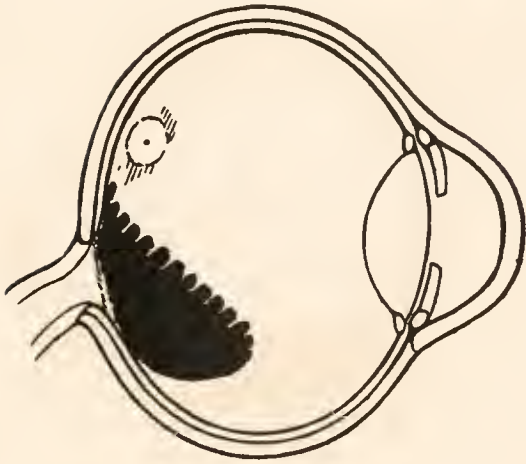


Fig. 60.

Amazon Parrot (*Chrysotis amazonica*).

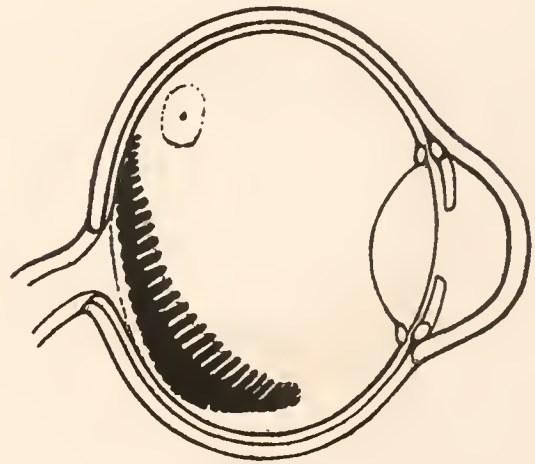


Fig. 63.

Laughing Kingfisher (*Dacelo gigas*).

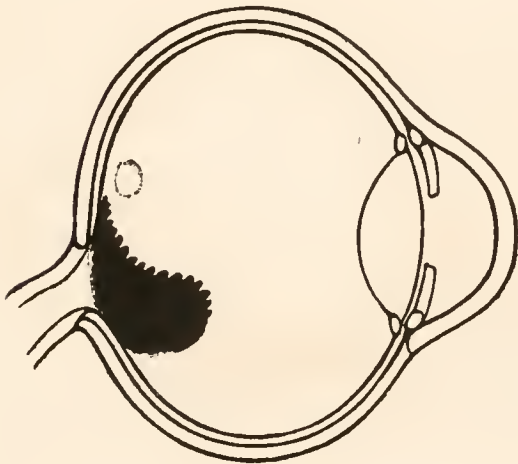


Fig. 61.

Lesser Sulphur-crested Cockatoo (*Cacatua galerita*).

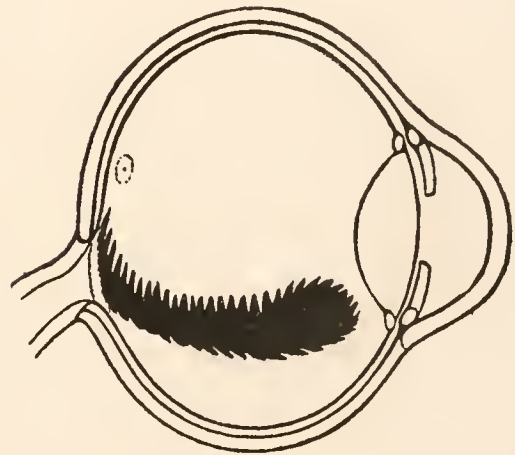


Fig. 64.

Black Hornbill (*Spagolobus adratus*).

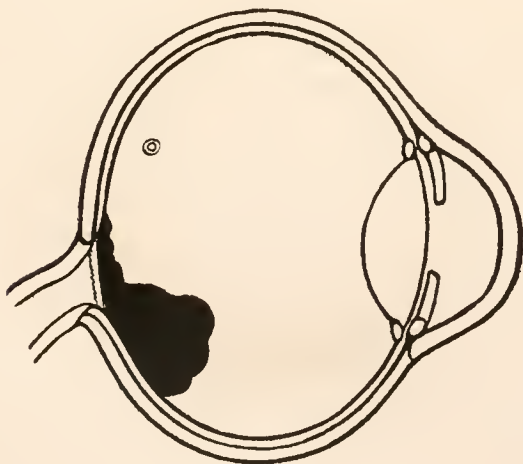


Fig. 62.

Kakapo or Owl Parrot (*Stringops habroptilus*).

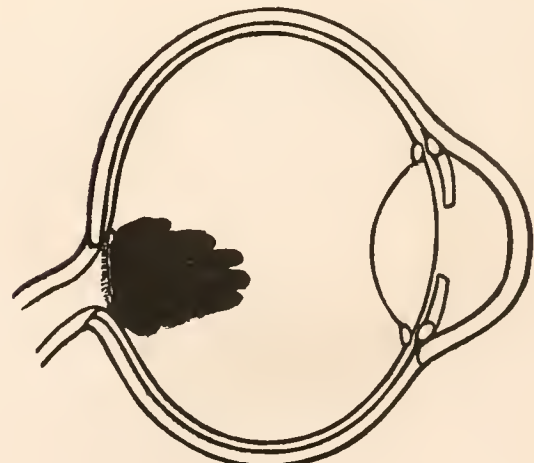


Fig. 65.

Nightjar (*Caprimulgus europaeus*).

Diagrams of the Pecten as seen by the Ophthalmoscope in Various Species of Birds.

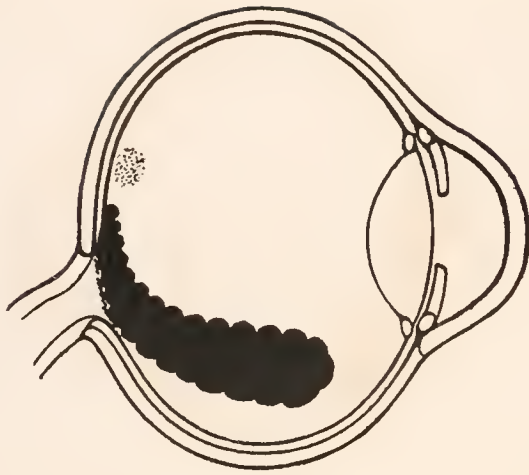


Fig. 66.

European Cuckoo (*Cuculus canorus*).

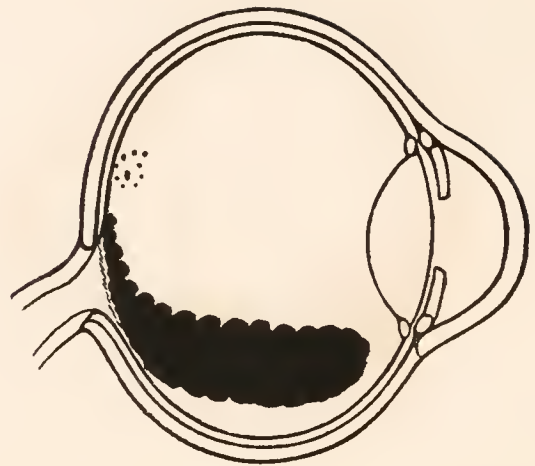


Fig. 69.

Gila Woodpecker [*Centurus (Melanerpes) uropygialis*].

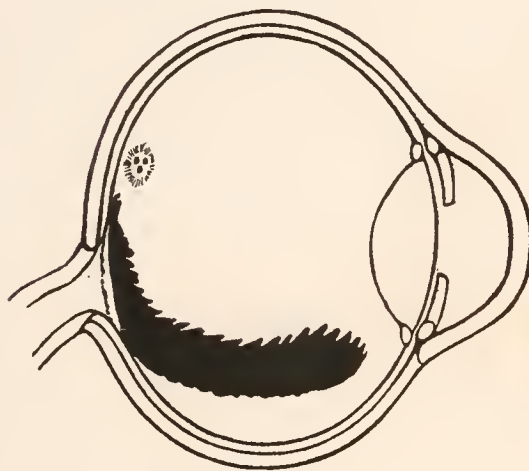


Fig. 67.

Sulphur-breasted Toucan (*Rhamphastus laematus*).

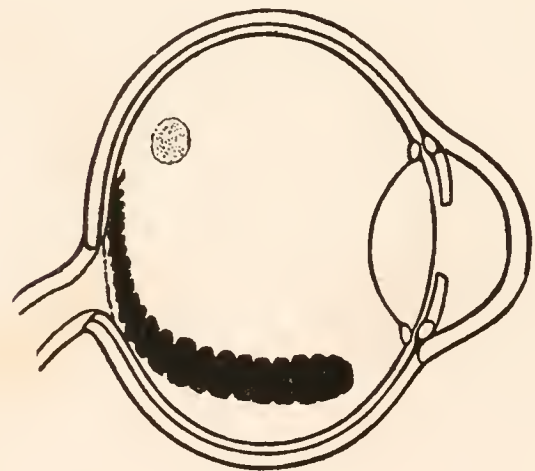


Fig. 70.

Derby Tyrant (*Pitangus derbianus*).




Fig. 68.

Great Spotted Woodpecker (*Dendrocopus major*).

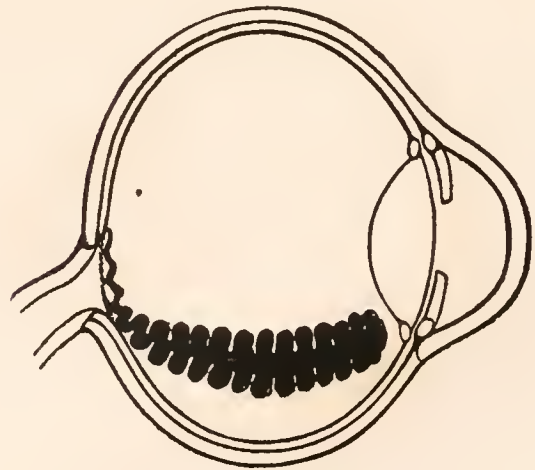


Fig. 71.

Chimney Swallow (*Hirundo rustica*).

Diagrams of the Pecten as seen by the Ophthalmoscope in Various Species of Birds.

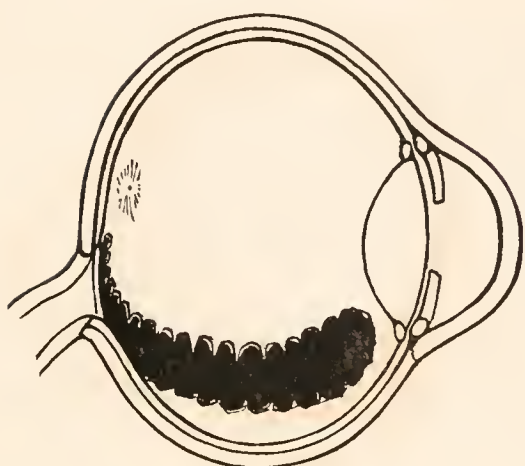


Fig. 72.

American Mocking Bird (*Mimus polyglottos*).

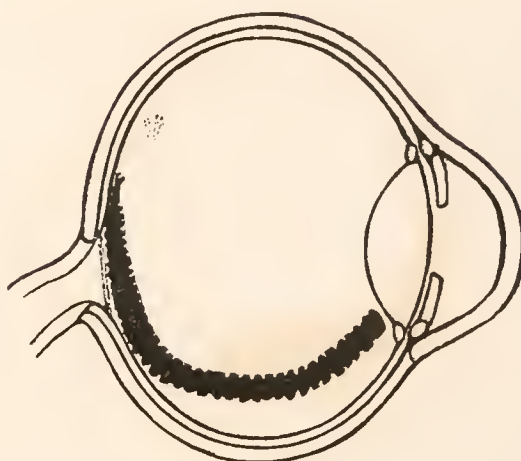


Fig. 75.

Blue Jay (*Cyanocitta cristata*).

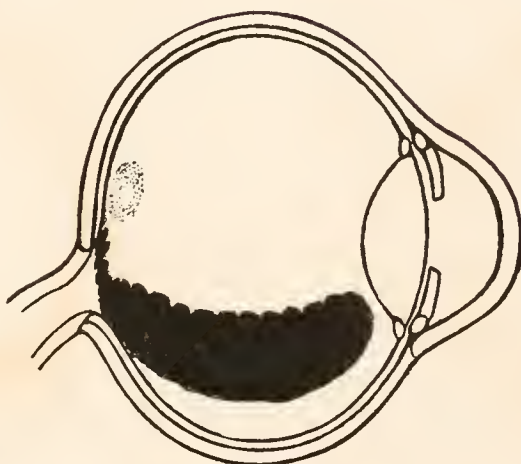


Fig. 73.

American Bunting (*Cyanospiza versicolor*).

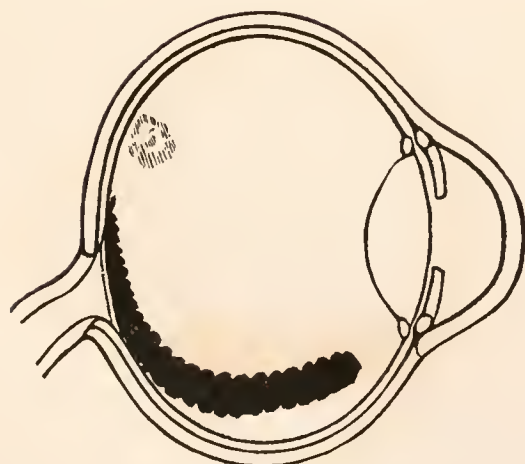


Fig. 74.

Law Bird of Paradise (*Parotia lawii*).

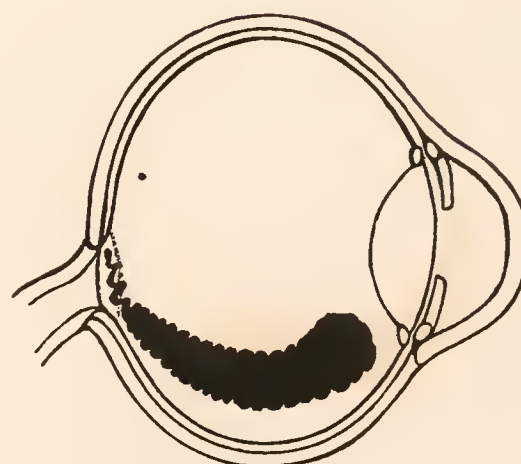


Fig. 76.

European Raven (*Corvus corax*).

Diagrams of the Pecten as seen by the Ophthalmoscope in Various Species of Birds.

pictured by different observers, an accurate photographic reproduction is much to be desired.

Probably the inventor who has come nearest this ideal is Wolff (*Monatsbl. f. Augenhelk.*, p. 447, Oct., Nov., 1907) of Berlin, who has done much in the photography of the human fundus. He made use of the light furnished by the Zeiss projection apparatus, the efferent rays being reflected into the eye, through half the pupil, by a specially contrived mirror. The efferent rays passed out through the other half of the pupil and were focussed in a photographic camera. A circle of the fundus about 10 mm. is thus illuminated at one time and the resulting picture — of course in gray tones — is magnified from three to four diameters. The required exposure is less than one-thirtieth of a second. The prints showed the optic entrance, the retinal vessels

and other gross details of the eye-ground but lacked that definition without which fundus reproductions are of little practical value.

Stimulated by these experiments of Wolff and by the experience of Dimmer, Thorner and Neuhaus, the writer, in conjunction with Dr. Earl Brown of Chicago and other experts, has endeavored to solve the problem both of ordinary and chromo-photography of the avian fundus. It must be confessed that nothing satisfactory has come of these efforts, nor of the corresponding attempts, referred to on p. 61, to photograph the eyeground of prepared specimens. The main difficulty (without entering into the details of the failures) in all these instances lies in the present impossibility of focussing *clearly* at the same instant all the points on such a concavity as the interior of the eyeball presents, either in its *post mortem* or its living state.

CHAPTER VII

MACROSCOPIC APPEARANCES OF THE FUNDUS OCULI OF BIRDS IN PREPARED SPECIMENS

THIS subject has to some extent been discussed in Chapters IV and IX. As previously stated, the actual appearance, arrangement and relations of the organs in the Bird's fundus — pecten, retina, optic nerve, choroid and choroidal bloodvessels, macular regions (areas of distinct vision)—can be readily perceived in properly preserved eyeballs. Immersed in Perenyi's fluid and a series of alcohols and otherwise carefully prepared, an equatorial section of an avian globe furnishes material for a satisfactory macroscopic study of many of the parts in the interior of the eye. The gross relations of these parts in typical birds are seen in Figs. 1, 5, 6, 7, and 11.

The *Pecten* is probably always somewhat shrunken and more or less displaced even in the freshest and best preserved specimens; so that allowance must be made (in examining prepared material) for that fact. This is the reason, perhaps, that *Apteryx* was for several generations credited with absence of a pecten, until Lindsay Johnson proved its presence in that bird. The peculiar construction of the small marsupium in the Kiwi not only made it easy of reduction in volume but it was also decidedly bleached by the alcohol in which the (old) material was immersed for a long period before it was made the subject of that naked-eye examination that led to the original error of observation.

The pecten varies in shape and size, as well as in the number and the character of the folds of tissue that compose it, according to the genus to which the bird belongs. Indeed, such a striking and varied picture does the pecten exhibit, both when seen with the ophthalmoscope during life and in prepared mac-

roscopical and microscopical specimens after death, that one might almost recognize the species by studying this organ and its relations to other parts of a bird's fundus. In the accompanying text are a number of drawings of the avian pecten as seen in prepared eyeballs.

That the *human hyaloid artery of fetal life* is a vestigial pecten seems almost self-evident. No one who has examined a persistent hyaloid artery and its branches, particularly if he has been fortunate enough to see the vessels carrying blood to and from their termination in the vitreous, can fail to be reminded of the structures that occur normally in some mammalian, most reptilian, and all avian eyes. This arrangement surely carries us back in fetal evolution to those sauropsidian ancestors who have left their mark on our embryology.

Attention may be especially drawn to the pecten of the American Coot (*Fulica americana*), consisting of 15 double folds. It shows in a remarkable and unusual fashion their fan-like arrangement, especially at the free, upper margin of the organ; it is there firmly attached to the fine vitreous processes and the hyaloid membrane. See Fig. 84.

In Gadow's contribution to Bronn's *Tier-Reich* a list of the number of convolutions in certain Birds is given, and reference is made to an attempted classification of Aves based upon it.

The *optic disc*, viewed macroscopically, is generally seen as an oval, ovoid, sometimes almost round, white or yellowish-white area largely obscured by its union with the base of the pecten. Its long diameter is generally from two to three times its width.

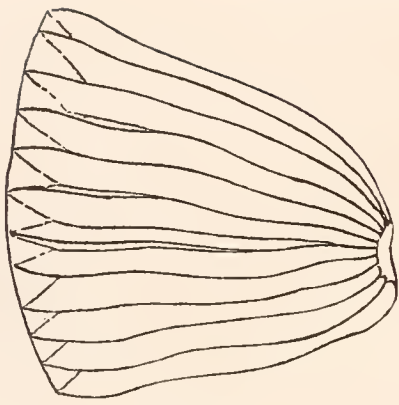


Fig. 77.
Nubian Ostrich
(*Struthio camelus*) ×3.

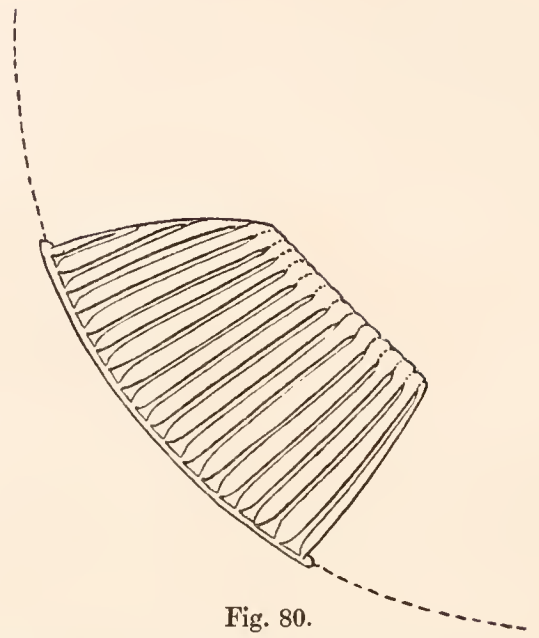


Fig. 80.
British Wood Pigeon (*Columba palumbus*) ×10.

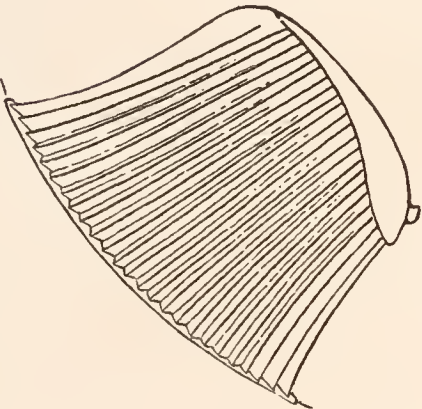


Fig. 78.
Martineta Tinamou
(*Rhynchotus rufescens*) ×10.

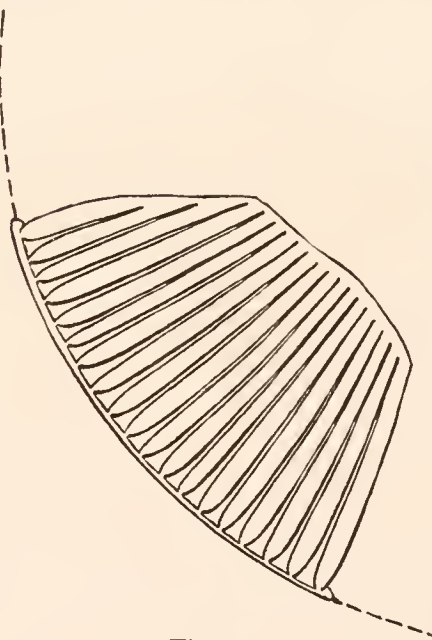


Fig. 81.
Wonga Wonga Dove (*Leucosarcia picata*) ×10.

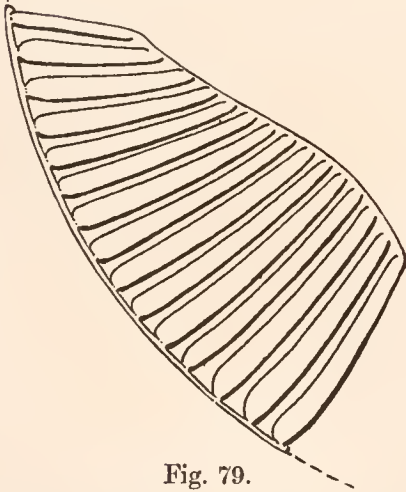


Fig. 79.
Valley Partridge or Quail (*Lophortyx californicus*
vallicola) ×16.

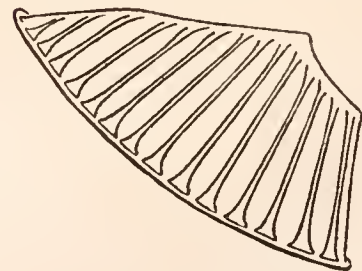


Fig. 82.
Pigeon Guillemot (*Cepphus columba*) ×9.

Lateral View of the Pecten in the Prepared Eyes of Certain Species of Birds.

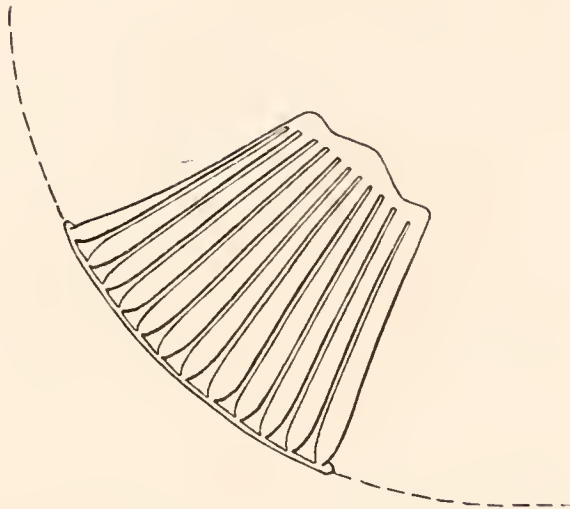


Fig. 83.

European Crested Grebe (*Podiceps cristatus*) $\times 12$.

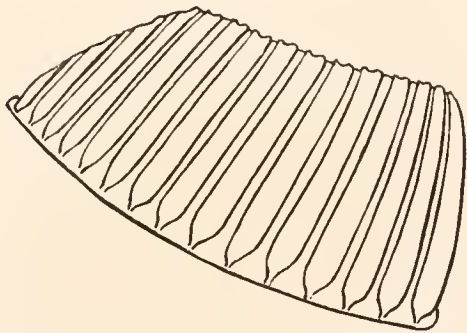


Fig. 84.

American Coot (*Fulica americana*) $\times 12$.

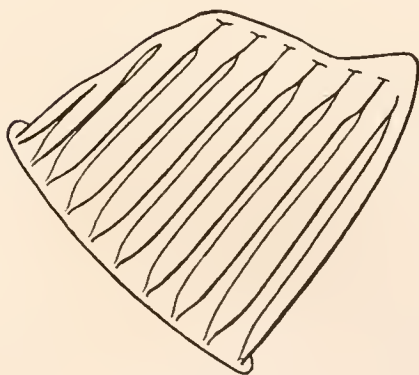


Fig. 85.

Dark-bodied Shear-water (*Puffinus griseus*) $\times 9$.

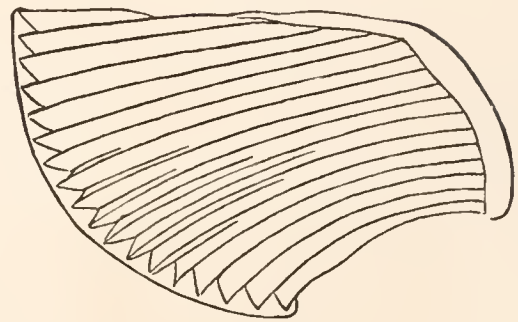


Fig. 86.

Herring Gull (*Larus argentatus*) $\times 7.5$.

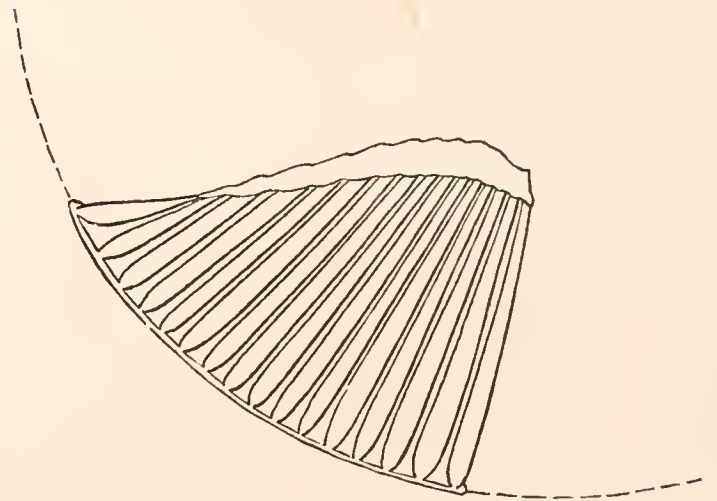


Fig. 87.

Greater Yellow Legs (*Totanus melanoleucus*) $\times 11$.

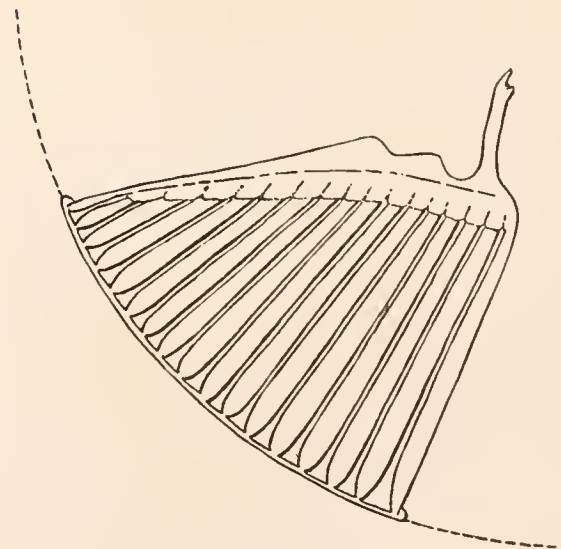


Fig. 88.

Hudsonian Curlew (*Numenius hudsonicus*) $\times 12$.

Lateral View of the Pecten in the Prepared Eyes of Certain Species of Birds.

THE FUNDUS OCULI OF BIRDS

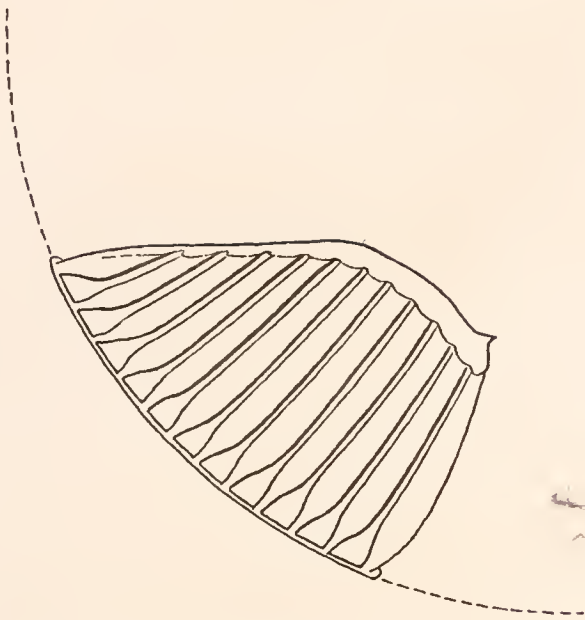


Fig. 89.

Black-bellied Plover (*Squatarola squatarola*) ×9.

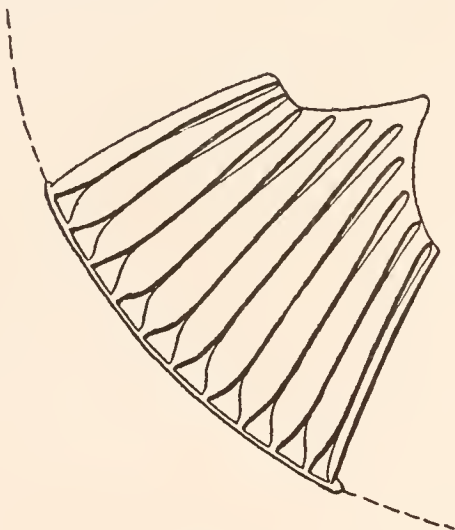


Fig. 90.

Great Bustard (*Otis tarda*) ×5½.

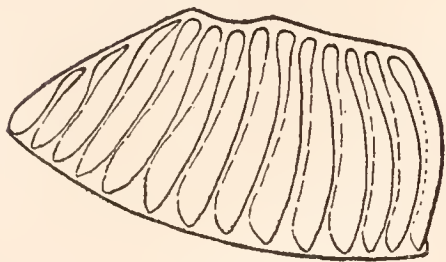


Fig. 91.

American Bittern (*Botaurus lentiginosus*) ×8.

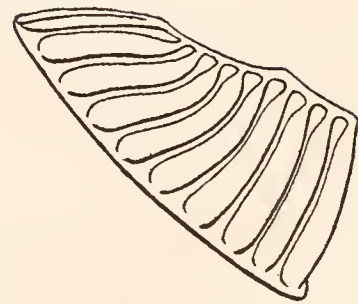


Fig. 92.

Black-crowned Night Heron (*Nycticorax nycticorax naevius*) ×6.

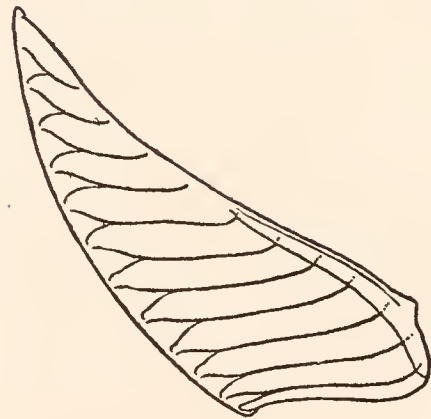

Fig. 93.

Lesser Snow Goose (*Chen hyperboreus*) ×9.

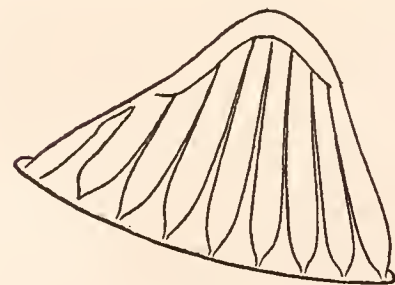


Fig. 94.

Common (Old World) Flamingo (*Phoenicopterus roseus*) ×8.

Lateral View of the Pecten in the Prepared Eyes of Certain Species of Birds.

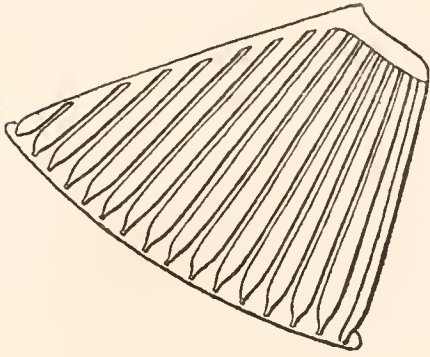


Fig. 95.

Brandt Cormorant (*Phalacrocorax penicillatus*) $\times 9$.

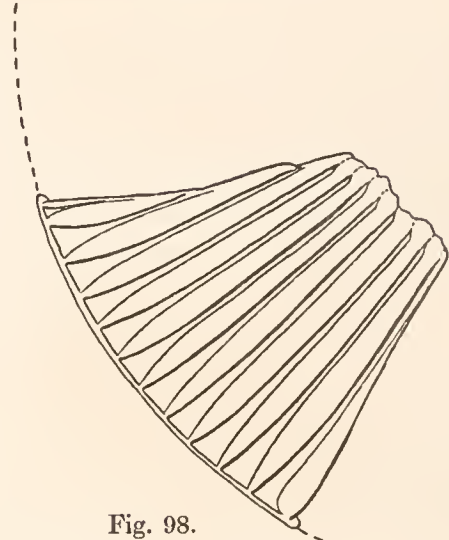


Fig. 98.

Greater Sulphur-crested
Cockatoo (*Cacatua galerita*) $\times 9$.

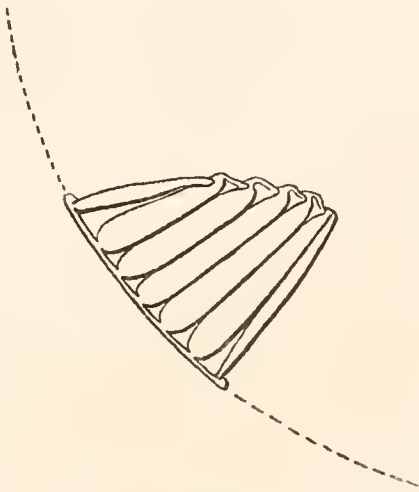


Fig. 96.

Tawny Owl (*Syrnium aluco*) $\times 7$.

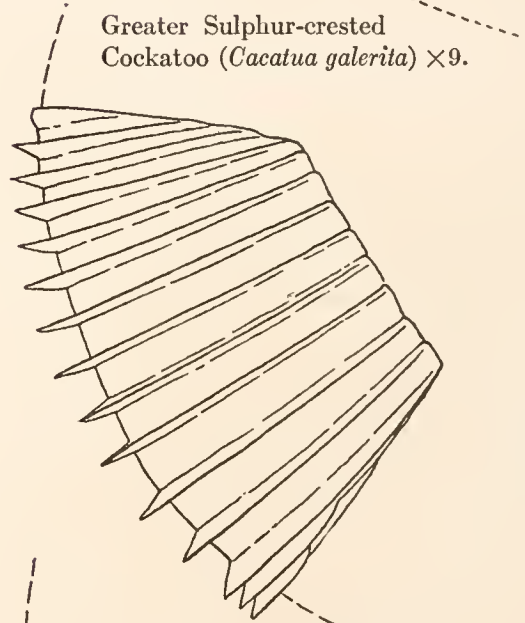


Fig. 99.

Common (British) Kingfisher
(*Alcedo ispida*) $\times 18$.

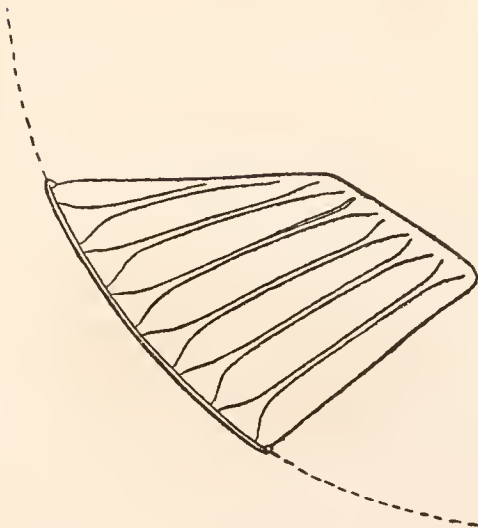


Fig. 97.

European Barn Owl (*Strix flammea*) $\times 9$.

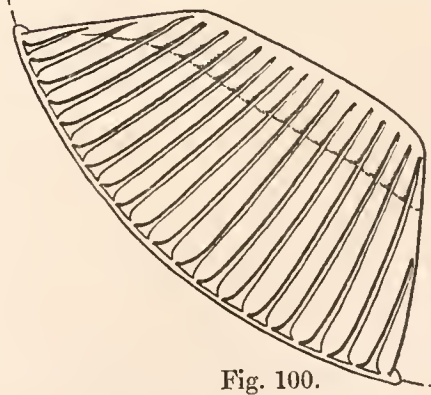
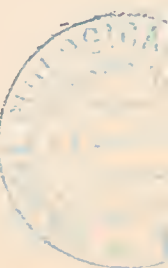

Fig. 100.

Common Hoopoe (*Upupa epops*).

Lateral View of the Pecten in the Prepared Eyes of Certain Species of Birds.



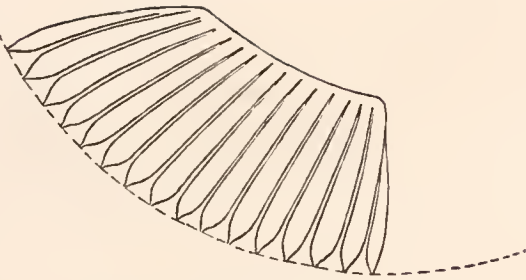


Fig. 101.
Anna Hummingbird (*Calypte annæ*) ×31.

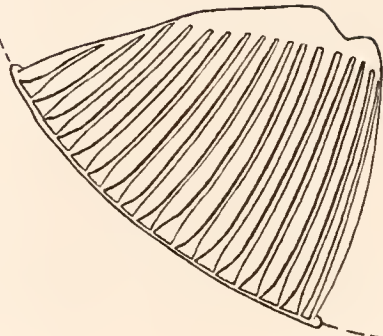


Fig. 104.
Red-shafted Flicker (*Colaptes mexicanus*).

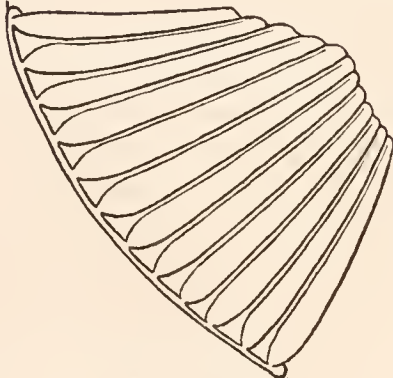


Fig. 102.
Yellow-billed Cuckoo
(*Coccyzus americanus*) ×12.

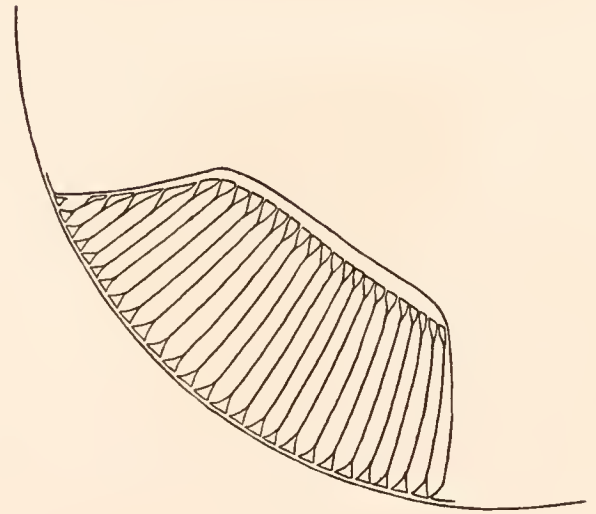


Fig. 105.
Western Mockingbird (*Mimus polyglottos leucopterus*).

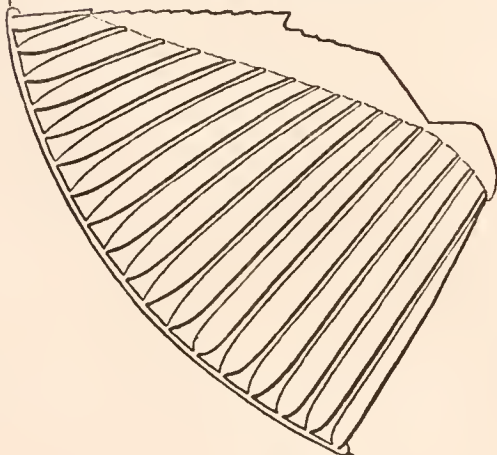


Fig. 103.
Red-headed Woodpecker (*Melanerpes erythrocephalus*).

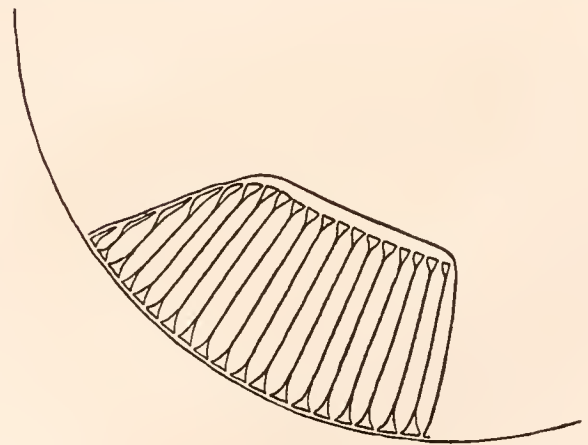


Fig. 106.
Bluebird (*Sialia sialis*) ×18.

Lateral View of the Pecten in the Prepared Eyes of Certain Species of Birds.

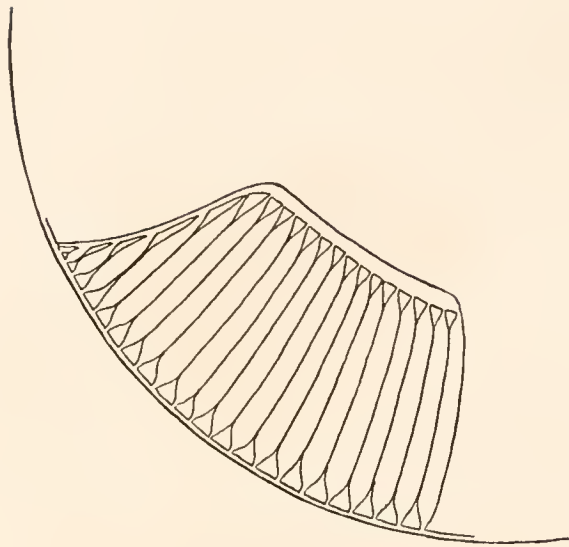


Fig. 107.

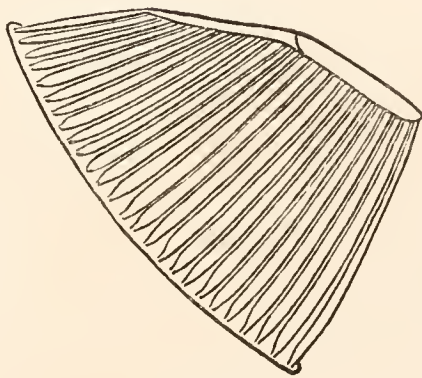
California Shrike (*Lanius ludovicianus gambeli*).

Fig. 108.

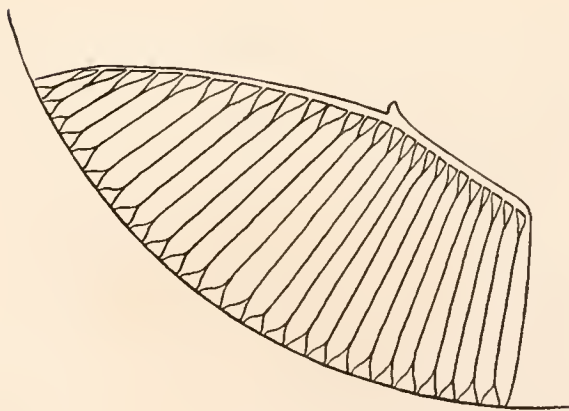
American Crow (*Corvus americanus*).

Fig. 109.

Steller Jay (*Cyanocitta stelleri*) $\times 12$.Lateral View of the Pecten in the Prepared Eyes of
Certain Species of Birds.

The *Retina* and the *vessels of the choroid* are practically invisible in the eyes of birds viewed macroscopically a few minutes after death. However, when treated with Perenyi's fluid and other preservatives or especially in case of successful carotid injections, the choroidal bloodvessels and tissues become more opaque or at least more translucent and may then be studied with success. Doubtless the ophthalmoscope gives us the one best means of seeing these tissues as they exist during life, but both methods, supplemented by the microscope, are needed for a complete study of them in all their relations. Very little light is thrown on these questions by naked-eye observations of the choroidal vessels, although in some birds, especially when injections of carmine have been made, they are quite evident. Serial sections, in conjunction with the use of the ophthalmoscope, afford the best means of studying these fundal vessels.

The pigment deposits and other histological elements in the choroid and retina — especially in the former — that combine to make or modify the general coloration of the fundus oculi are best seen with the ophthalmoscope; prepared specimens furnish but slight indications of these. Differences of level, as in the macular areas, are, however, well shown macroscopically.

Areas of Distinct Vision. As a result of the investigations of Slonaker and the writer it may be said of Birds with but a single fovea that this sensitive area is generally placed about the center of the retina, slightly above and towards the *nasal* aspect of the optic nerve entrance. This observation is practically illustrated in a number of pictures reproduced in this work from the drawings of Kennedy and the paintings of Head. See, for example, the drawings of the fundus views of *Sialia sialis* (Fig. 140), *Corvus americanus* (Fig. 142) and *Nycticorax nycticorax* (Fig. 129), in which a single, deep, well-defined fovea is present.

An exception to the rule of the nasal position of the single foveæ and macular regions is noticeable in the Owls. These birds possess a single, deep fovea encircled by a round, sharply defined area located above and on

the *temporal* side of the optic disc, an example of which is pictured in *Syrnium aluco* (Fig. 132) and *Strix flammea* (Fig. 112). This arrangement closely approaches the binocular maculae of Man; indeed the visual apparatus of Strigiformes resembles the human eye more closely than does any other order.

The *Choroid* is seen macroscopically as a dark background for the translucent, or only partially visible retina; indeed, the coloration of both macroscopic and ophthalmoscopic pictures of the bird's fundus is largely determined by this deeply pigmented ocular tunic with its rich vascular supply.

As noted in Chapter VIII, *domestication* brings about changes in all the fundal tissues — usually tissue degeneration, if not actual disease. Hence we find that Gallinæ possess very shallow or doubtful foveæ. The writer has concerned himself little with barnyard fowls, but Slonaker has shown that while *Columba livia domestica*, still retains a medium fovea surrounded by a well-defined macular area, *Meleagris gallopavo* and *Numida pucherani* have very shallow *areae centrales*. As stated elsewhere, some Birds have no macular region demonstrable by the naked eye. *Gallus domesticus*, for example, has an extremely doubtful fovea, while *Anser domesticus* and *Anas boschas domesticus*, in addition to a very shallow macular region, exhibit a band-like area extending horizontally across the retina. The latter device probably enables the bird to widen the limits of his field of distinct vision (especially while feeding) without being obliged to move the whole head. This curious provision is more clearly shown in the Ring-Neck Plover whose fundus shows a very distinct band-like area that passes obliquely across the retina. A dark line, like a trough or gutter, appears to the naked eye in preserved specimens to extend almost the full length of the band. Slonaker examined this area microscopically but could find no trough-like depression.

Oval, ovoid, circular or ribbon-like areas, are as a rule, readily traced in the gray, smooth retinal tissues, although both the microscope and ophthalmoscope may be needed, as in the Flamingo and some of the

Gallinaceous birds, as a supplement to macroscopic inspection to decide the presence or otherwise of a macular region or of any of its components. The limits of the *retinal band area* often call for these aids; indeed it may be said that no exploration of an avian fundus should be regarded as complete until all these requirements are met. Areas of acute vision, in prepared material, appear to be whiter or less gray than the surrounding retina; there is not, however, a sharp definition to the naked eye, or even when observed by the help of a magnifying lens, but the tissues of the *areae centrales* shade off and gradually blend with the perimacular tissues.

It must not be assumed that because no central area of distinct vision is discovered macroscopically that it does not exist. Some macular regions are so shallow and so slightly differentiated from the neighboring tissues that only the microscope can settle the question of their existence.

The exact character and visual purpose of these retinal band-like areas (sometimes also visible to the ophthalmoscope) await further histological investigation.

Birds of prey as well as the swift fliers show the best marked and the greatest variety of macular regions. A typical instance is seen in the Sparrow Hawk. In this bird each fundus presents a well-marked *fovea nasalis* and *fovea temporalis* connected by a short band-like area.

The *nasal fovea* is invariably the deeper and sharper of the two, and probably is used when distinct sight and binocular vision are required. It is surrounded by a large, macular area and is situated about the center of the retina.

The *temporal fovea* is shallower, is encircled by a smaller area and is placed near the periphery of the retina lower than the nasal fovea but about the same distance from the optic papilla. This foveal region holds about the same relative position in the fundus as the single fovea of the Owl while the *fovea nasalis* stands in the same relation as that occupied by the Blue-Bird and the Robin.

Of the swift fliers the Terns and the Swallows present much the same foveal and band-like sensitive regions as the Hawks; in other

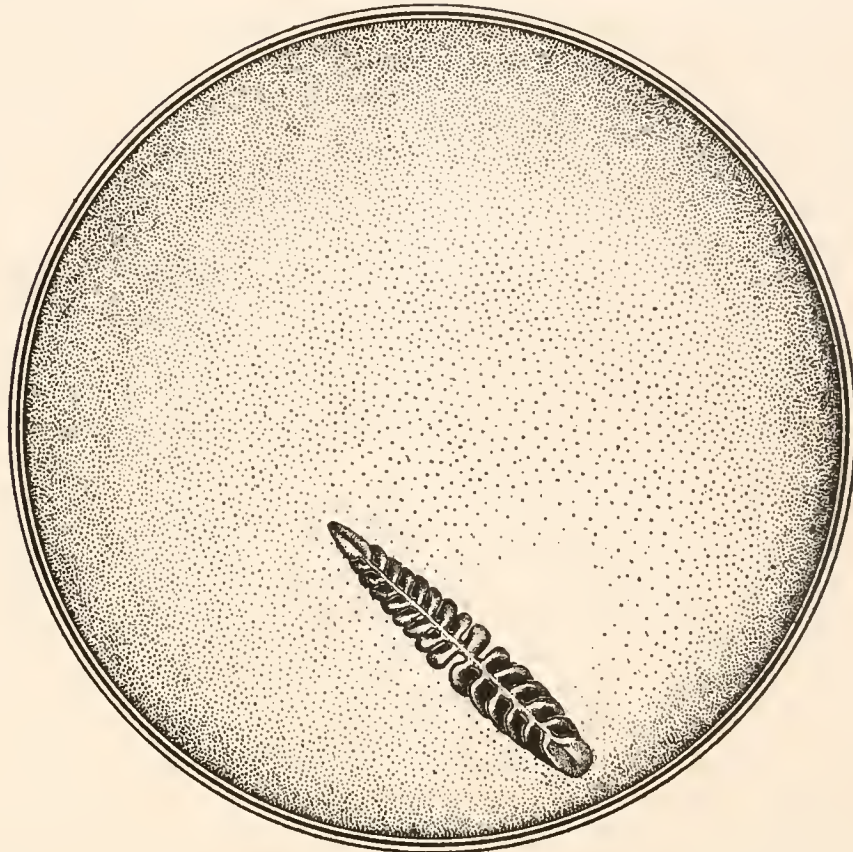

Fig. 110. Example of the First Type of Central Visual Areae in Birds. The Amacular Fundus of the California Valley Quail (*Lophortyx californicus vallicola*) $\times 16$.

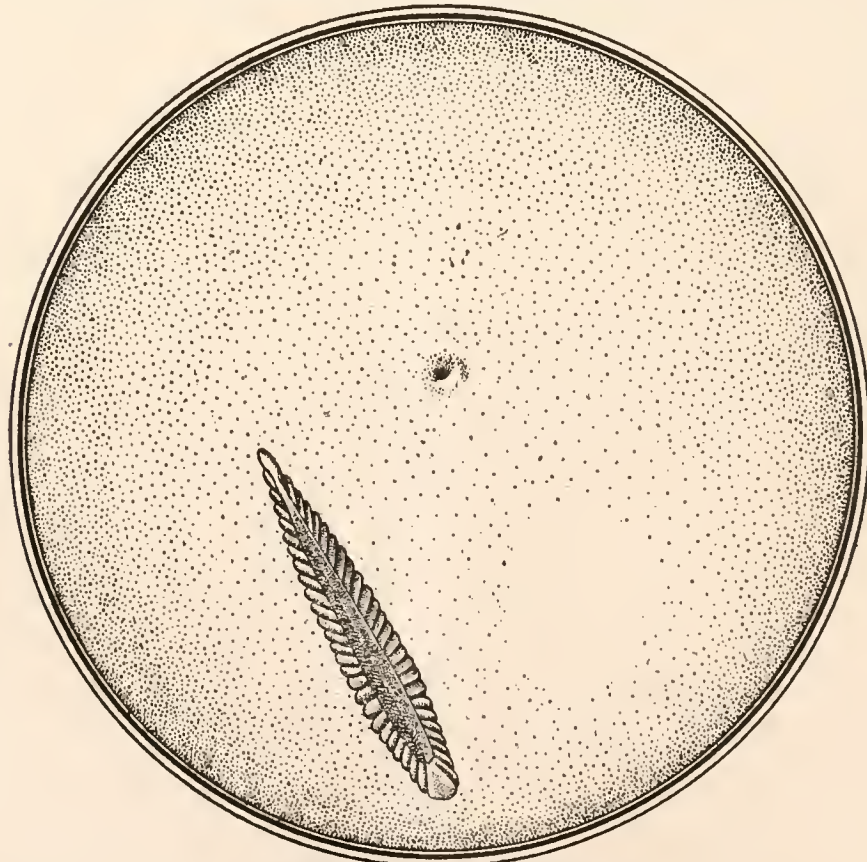

Fig. 111. Example of the Second Type of Central Visual Areae in Birds. The Nasal Monomacular Fundus of the Steller Jay (*Cyanocitta stelleri*) $\times 12$.

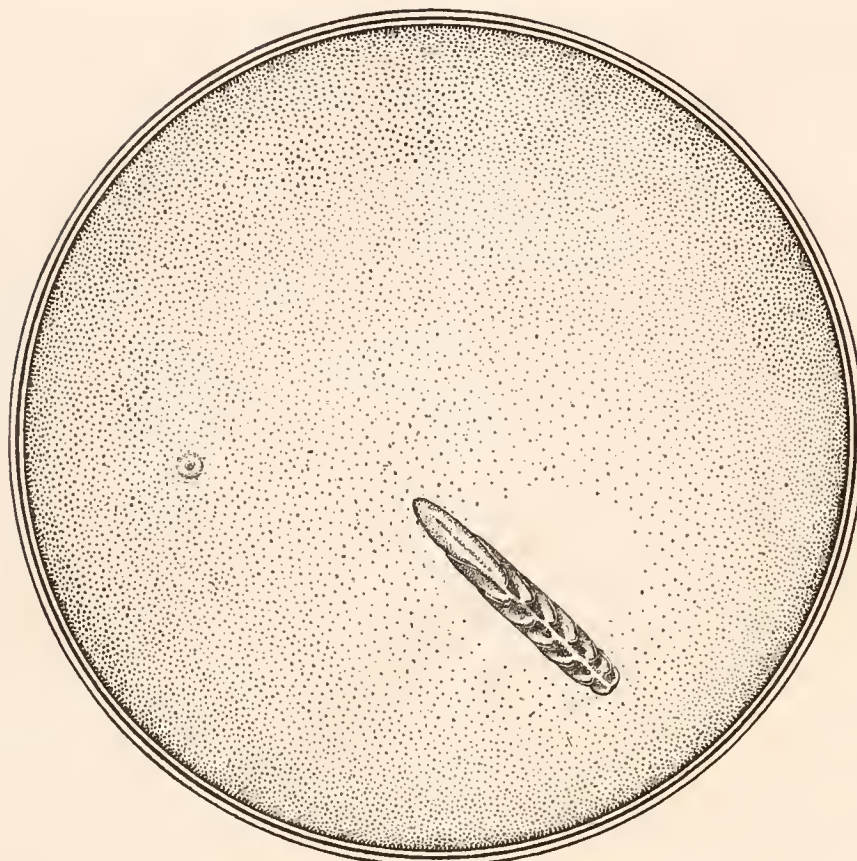

Fig. 112. Example of the Third Type of Central Visual Areae in Birds. The Temporal Monomacular Fundus of the European Barn Owl (*Strix flammea*) $\times 9$.

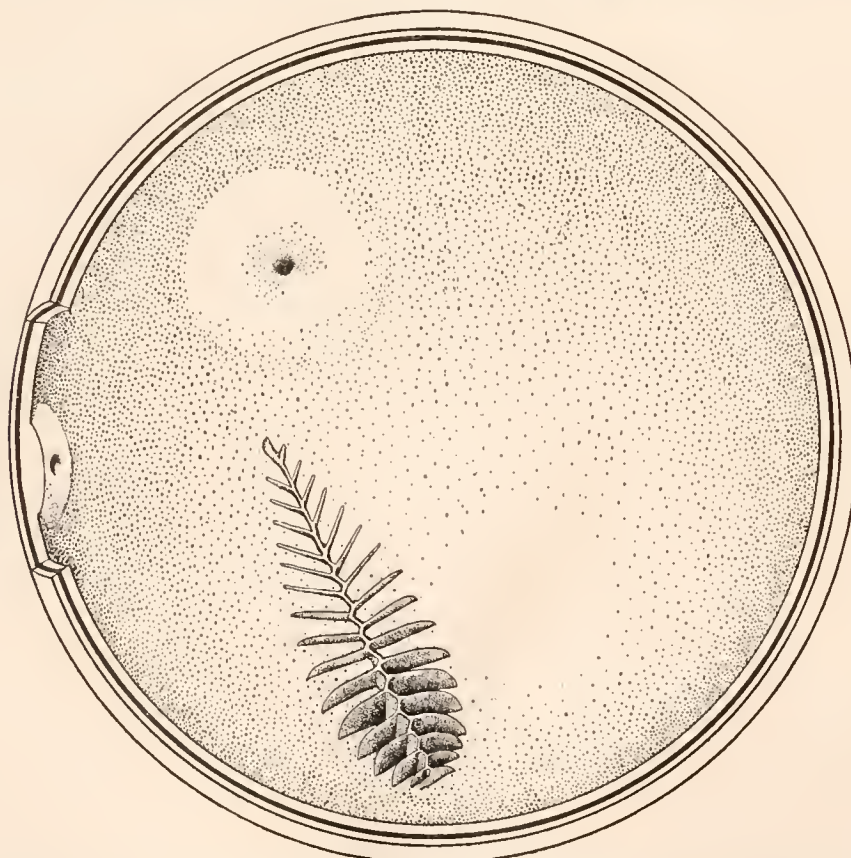


Fig. 113. Example of the Fourth Type of Central Visual Areae in Birds. The Bimacular Fundus of the British Kingfisher (*Alcedo ispida*).

words the disposition of the areas for acute vision assumes this form in Birds that take their prey on the wing or by darting upon it from a distance.

A Classification of Areas of Distinct Vision in Birds

From the foregoing it may be concluded that there are at least six arrangements of these areas, and consequently six forms of apparatus for securing acute eyesight in birds. These may be classified as follows:

1. The *amacular fundus*, in which, as in the California Valley Quail (see Fig. 110), there is to be seen neither with the ophthalmoscope nor in preserved material any indication of a central macular region; rather a rare class. It is only by a microscopical examination of serial sections that one sees the histologic elements indicative of an area of vision more specialized for distinct visualization than the surrounding retina. Such fundi are rare, and are found, for example, in a few domestic birds. Slonaker discovered a shallow and ill-defined central area in the Turkey (*Meleagris gallopavo*) and the Guinea Hen (*Numidia pucherani*); also "a very slight thickening," instead of a fovea, in the Cock (*Gallus domesticus*).

2. The *nasal monomacular fundus*, situated in the centre of the retina, is found in the majority of birds. An example is shown in a drawing of the eyeground of the Steller Jay (see Fig. 111). As a rule, it is best demonstrated macroscopically, although even a cursory examination of the colored plates in this work will reveal numerous examples of this form of fundus when viewed ophthalmoscopically.

3. The *temporal monomacular fundus* is found almost exclusively in the Owls. An example of this form is seen in the European Barn Owl (Fig. 112); indeed in all the Strigiformes whose fundi are pictured or described in this monograph.

4. The *bimacular fundus*, in which there are two maculæ, generally a deeply marked and principal nasal region and a subsidiary temporal area. See Fig. 113, representing a macroscopic view of the (preserved eyeball) fundus of the Belted Kingfisher.

There are two sub-varieties of this fundus; (a) certain eyes of regular form in which the *nasal* macular region is well developed and the fovea is deep and sharply defined, as in *Alcedo*, *Sterna* and *Tachycineta*; (b) in birds with eyes of irregular shape, exhibiting a deeper *temporal* fovea and better marked macular region. These are found in the Hawks especially.

5. A *band-like central area* with which is almost invariably associated a well-defined fovea or macula. To this form of avian background the writer has given the name *infulamacular* fundus*. As an example, see Fig. 114, showing a macroscopical view of the eyeground in the Greater Yellow-legs (*Totanus melanoleucus*). In this class the band incloses, in some part of its course, the single fovea which in its turn is found on the nasal side of the fundus.

6. Finally, in some avian backgrounds there are *two macular regions, either joined to or associated with the band-like area*, to which the name *infulabimacular fundus* has been given by the writer. An ocular background of this description is seen in the Common Flamingo. See Fig. 115. There are at least two varieties of this form.

The Sparrow Hawk (*Falco sparverius*) and *Buteo borealis* furnish examples of form (a) — a well-defined nasal macula with a deep fovea situated near the centre of the retina and a shallow though easily demonstrable temporal macula, the two joined by a short ribbon-like area. The band area does not extend beyond either macular region.

In second form (b), represented by the Tern (*Sterna hirundo*), the band-like area encloses a nasal macula while a second (temporal) macular region lies above and apart from these.

Even a slight acquaintance with the *fundi oculorum* of the comparatively few Birds so far examined shows not only numerous types of *areae centrales*, but a still greater variety in their size, shape and appearance, both macroscopical and ophthalmoscopical. These are most distinctly marked in the prepared specimens. Some Birds exhibit a large, circular

* *Infula*, a band or ribbon.

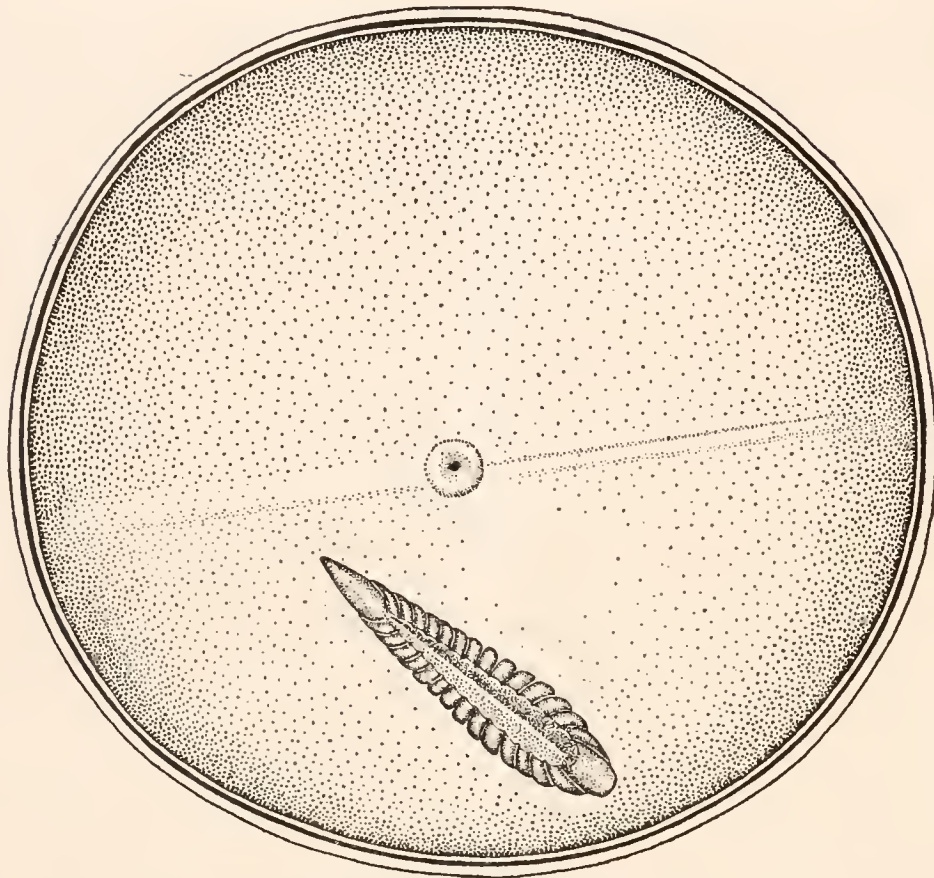


Fig. 114. Example of the Fifth Type of Central Visual Area in Birds. The Infulamacular Fundus of the Greater Yellow-legs (*Totanus melanoleucus*).

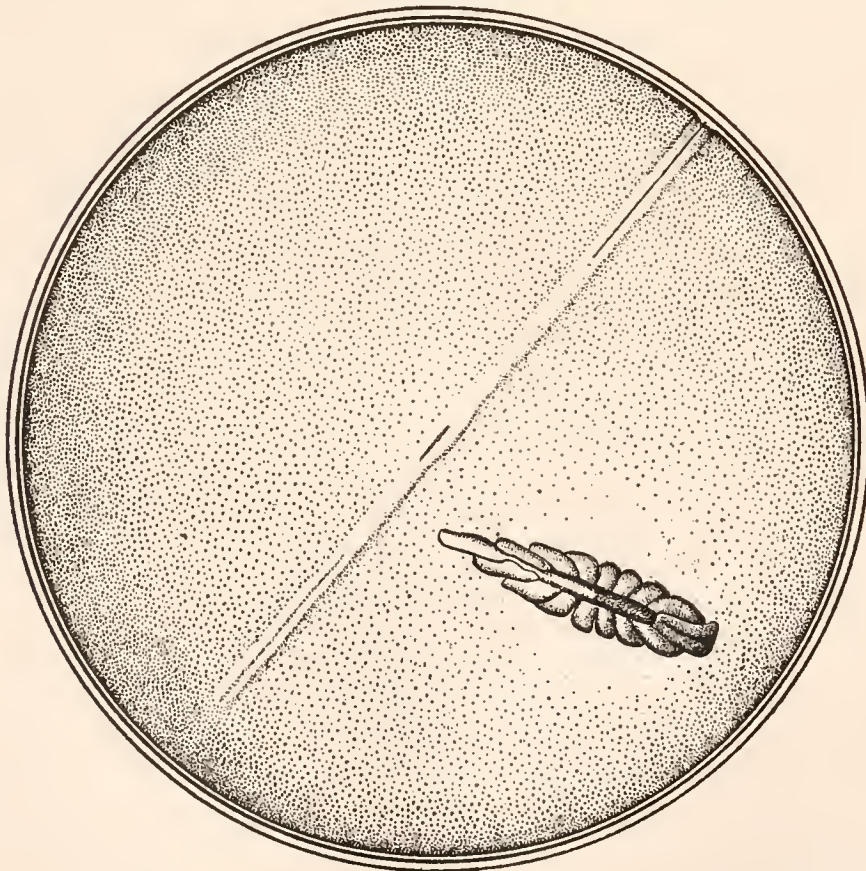

Fig. 115. Example of the Sixth Type of Central Visual Area in Birds. The Infulabimacular Fundus of the Common Old-world Flamingo (*Phoenicopterus roseus*).

area — single or double, sometimes associated with a band area, sometimes not—with clearly outlined margins and a deep fovea and distinct foveola. In others the fovea is shallow and the macular borders are with difficulty differentiated from the fundal retina.

Photography of the Fundus Oculi in Prepared Eyeballs

Attempts similar to those of Wolff and others, mentioned in Chapter VI, to photograph the interior of the posterior half of the eye have been made with some success in the case of prepared eyes. The difficulties that surround these attempts, although fewer than with the living subject, are as yet unsurmounted so far as minute and exact fundal details—the chief object to be attained—are concerned. Photography furnishing a clear and sharp definition of small objects arrayed at various points in one concave surface is as yet impossible—hence the blurred appearance of pictures of the vertebrate eyeground so far published. Even the best of these—the enlarged stereoscopic photographs that illustrate Arthur Thomson's *Anatomy of the Human Eye* (London, 1912), the carefully prepared original photographs in the beautiful atlas of Fritsch, and the stereographs of George Dixon—hold out little hope that similar processes may be of use in depicting avian eyegrounds. Only the laborious pen and brush of the careful and competent artist-ophthalmoscopist can so far be depended upon to depict the mac-

roscopic appearances of these complicated tissue arrangements.

R. H. Elliot (*The Lancet*, p. 830, Nov. 11, 1916) has developed a method of photographing prepared eye specimens of which the writer has had no personal experience, but which he believes may be of value to the investigator. Elliot regards the following points of importance: The photograph must be taken in water, without the intervention of glass or other similar material. The source of light must be good and even. The camera must be placed vertically above the object so as to avoid reflections. The object of the photograph must be placed so that its image will occupy the center of the plate, and a method of adjustment should be available to secure this end with a minimum of inconvenience. A simple arrangement is necessary to fix the eye in position during the whole period of exposure. To save unnecessary retouching the object should be photographed lying on a dark and uniform surface to obviate the background disturbing the attention of those viewing the picture. Care should be exercised in the choice of a camera and exposure periods must be carefully studied. For the making of lantern-slides the contact method was recommended, and attention was directed to the following points: correct exposure; the preparation of plates for exposure; development and fixation of the slides; the drying of the plates; and the reduction, intensification and varnishing of slides.

CHAPTER VIII

EFFECTS OF DOMESTICATION AND OTHER ABNORMAL INFLUENCES ON THE FUNDUS OCULI OF WILD SPECIES OF BIRDS

As noted in Chapter III the eyes of only healthy individuals and (as far as could be ascertained) of normal wild species have been chosen for the purposes of this research. In practice, however, this is not as easy a task as first appears, since it is on occasions difficult to decide by any or all of the three principal means of investigation — the ophthalmoscope in living specimens, the microscope and naked eye in preserved globes — whether a given condition is normal or abnormal, congenital or acquired. The writer's observations of the eyes of both domestic and wild birds leads him to believe that *domestication* of Birds, which generally means a radical departure from their natural food, exercise, manner of raising their young, use of their various organs (eyes included) and above all the effects of confinement *per se*, is the principal cause of the anomalies seen in the fundi of caged or barnyard species. This difficulty in determining the exact character of tissue alterations is all the greater when the suspected fundus change occurs in both eyes and the organs are not available for macroscopic and microscopic examination. For instance, the eyeground of the Spoonbill (Plate XXV) is shown with a curious (and unusual) linear stripe running parallel and close to the optic disc. This may be an abnormal fundus condition although the weight of evidence leans the other way.

Nocturnal birds, when caged, appear to be especially affected by "Zoo" conditions. The Caprimulgidae, as well as the Strigiformes, for example, are liable to acquire choroidal diseases.

While examining a number of common Screech Owls, the writer found one individual, about five years old and three years in captivity, that showed the following conditions: Left eye; usual Owl fundus; well marked disseminated choroiditis, affecting the nasal aspect of the background more than the temporal. The choroidal vessels show through a number of atrophic areas. Usual pigment spots smaller than normal, almost punctate. Right fundus: the general appearance on this side is of a striped gray, very much like the warp and woof of some fabrics, or like the beginning choroidal atrophy of myopia. In other respects the right fundus resembles the left.

Mr. Head informs me that in examining with the mirror a Bluebird (*Sialia sialis*) in captivity seven years, the vitreous humour was found to be quite dull and foggy and the fundus showed spots of an orange-red color. This was very likely a diseased condition, as the other eye had a cataract in it.

The writer has examined with the ophthalmoscope the eyes of a number of Turkey Vultures (*Cathartes aura*), practically domestic animals in many American towns, and found few of them healthy. In one case the bird had cataract in each eye. In another there was beginning central opacification of the lens in the left eye; the same condition more advanced in the right. A third had no lenticular changes, but owing to a suspicion that the fundus findings might not be those of a healthy individual the findings were not included in the list described in Chapter IX. The following are the notes of this examination: Left fundus; general coloration steel

gray. Resembles the Bald Eagle. Pecten large and apparently reaches posterior part of lens. Optic nerve entrance entirely obscured and optic nerve fibres are persistent at temporal margin of the disc. Retinal reflexes very distinct. At the upper and temporal edge of the disc the white border of papilla shows quite distinctly. Pecten very black and in no part translucent; lies in well defined coil-like folds. No definite visual areas can be differentiated from the general fundus. Fundus 'granular' in places. The refraction slightly hyperopic.

Beginning with his experience as a student in the *Thierartzneischule* of the University of Berlin in 1888, the writer has examined the eyes of many barnyard fowls, to find in them a great variation in the fundus appearances even of the same species. The following few descriptions from notebooks will suffice to illustrate this point:

Bantam cock (*Gallus domesticus*). Fundus examination; direct, with electric ophthalmoscope. Both backgrounds the same. The whole eyeground is of a uniform 'pepper and salt' and granular variety — the 'pepper' predominating. The macular region shows quite plainly, the fovea being represented by a single star-like deposit which looks exactly like (and may be) a crystal of cholesterin. The disc is a long oval, almost but not entirely covered by the pecten at each side but

quite clear at either end. The pecten changes size and position under the examination but not so quickly as in the Crow, for example.

Large and mature 'speckled hen,' with a light, brick-red iris. Kept in laboratory of St. Luke's Hospital as a source of pure avian blood. The observations on the bantam rooster just detailed almost entirely coincide with the findings in this bird, except that no single stellate formation in the macular region was noticed. Skiascopy and pupil reflexes almost the same. There was no noticeable astigmatism developed in either.

A great variety of fundal pictures — normal and abnormal — are presented by our Domestic Pigeons. The following are notes on the fundi of the Homing or Homer Pigeon: The background is readily seen in all these domestic Pigeons. It bears a close resemblance to that of the common Hen, except that the macular region is better defined in the Pigeon. The sprinkling of fine, dark-brown pigment over a reddish background, interrupted here and there with colored points, generally yellowish and glittering, giving the whole a uniform appearance like fine 'mixed tweed' cloth seen from a distance of a few feet, is very characteristic of this class of fundi. The pecten is relatively small, clubbed, spiral, black-brown and prevents one from seeing more than a third of the ovate disc.

CHAPTER IX

THE OPHTHALMOSCOPIC AND MACROSCOPIC APPEARANCES OF THE FUNDUS OCULI IN VARIOUS ORDERS OF BIRDS

THAT one may properly answer many questions involved in the anatomy and physiology of the important organs and tissues that constitute the eyeground in Vertebrates it is necessary to consider not only the ophthalmoscopic, but the macroscopic and, in some instances, the microscopic findings. Although none of these methods of research has as yet been carried out with any approach to completeness yet the histology of the retina and other visual organs has been satisfactorily studied in Man, and a few other species of Vertebratæ, by Cajal, Greeff and others. Little attention has, however, been paid to the other two forms of investigation, that is to avian ophthalmoscopy or to what may be termed avian *ophthalmomacroscopy*.

Ophthalmoscopy is, in effect, a demonstration of the actual (comparative) size and relative position of the principal parts—nerves, bloodvessels, [oil droplet (?)] dots, organs of special sense—as well as the actual coloration of the fundus oculi of the living Bird. Macroscopy, on the other hand, reveals some details of the Bird's eyeground not apparent or only faintly apparent to the ophthalmoscope. For example, the extent and other exact relations of some of the areas of acute vision, as well as definite, lateral views of the pecten, are better determined by naked-eye examinations of prepared specimens than by viewing them through the pupil of animate species.* To

*The dots that besprinkle the fundus in the black and white drawings (to indicate the macroscopical appearances of the fundus in preserved specimens) are merely the artist's device to depict the concavity of the eyeball, elevation of parts, etc., and have nothing to do with the fundal dots and other coloration so well shown in the colored plates.

this may be added, as elsewhere pointed out, that in certain instances the fine anatomy and exact relations of certain organs and tissues of the background of the Bird's eye can be determined only by a microscopical examination of stained and injected sections of the parts.

The following species (healthy adults) have been examined either with the ophthalmoscope or by inspection of prepared eyeballs, or by both methods. In a number, also, the eyes have been sectioned and examined microscopically. These findings have been mostly pictured in the text or by appended colored plates, and will now be described.

A. RATITAE

Struthioniformes

Nubian or Northern Ostrich. *Struthio camelus*. (Figs. 116 and 77; macroscopic view). The black and white drawing of this fundus shows a large, regularly oval papilla sprinkled with pigmented dots and circled by a well-defined border.

The foreshortened view of the *pecten* gives one the impression of an octopus-like figure lying upon and almost covering the surface of the optic disc, which is plainly visible beneath and sprinkled with pigment dots. There are readily counted twenty-four pectinate convolutions (12 double folds) that meet above and are joined to an irregularly ovoid body—the crest or free margin of the marsupium—apparently by a sort of purse-string action. The folds of the pecten are extremely thin and entirely unlike the great majority of the convolutions in carinate birds.




Fig. 116. Nubian Ostrich (*Struthio camelus*) $\times 3$.

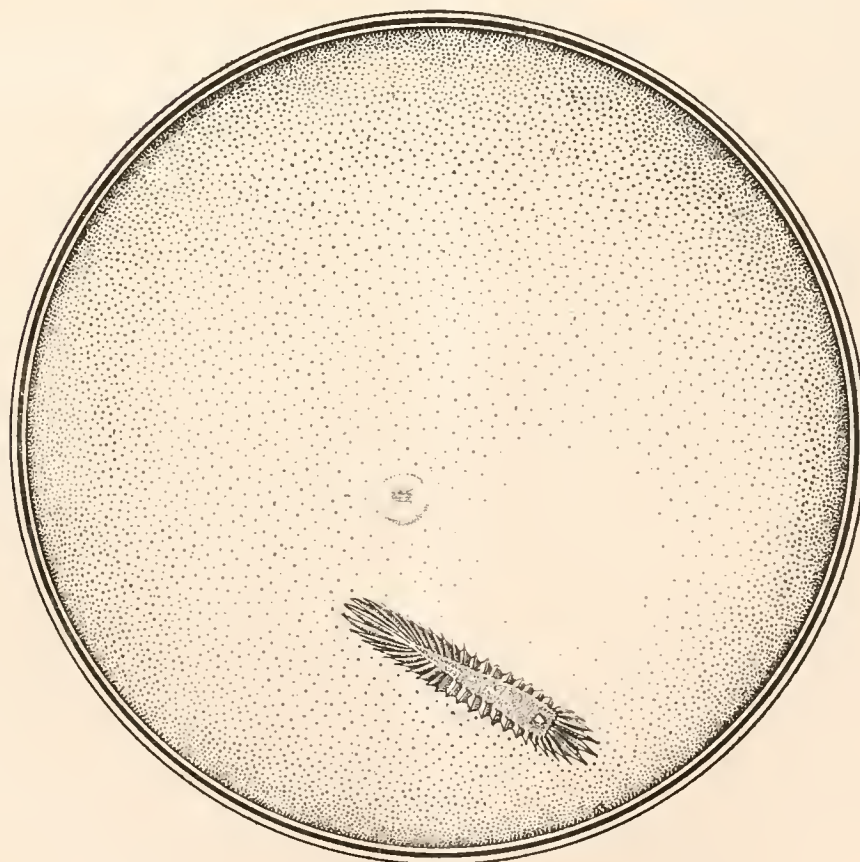

Fig. 117. Rufous Tinamou (*Rhynchotus rufescens*) $\times 10$.

Macroscopic Appearances of the Fundus Oculi in the Preserved Eyes of Birds.

A long, uniform band of two dark lines enclosing a broader white band runs almost horizontally across the fundus above the optic disc. About the middle point of the band (above the disc and towards the nasal aspect of the fundus) is a round depression (?), black in the center and surrounded by two indistinct, pigmented semicircles, made by a widening of the parallel lines that enclose the fundal band.

The extended major axis of the optic entrance oval describes an angle of almost 45° with the inferior border of the retinal band.

This angle the writer has called the *infula-papillary angle*, from *infula*, a band, and *papilla*, the optic disc.

Plate I, page 121, gives a very good idea of the ophthalmoscopic appearances in this species. It represents the eyeground as seen in specimens examined by Head in the Gardens of the British Zoological Society and by the writer in a young male adult living in the open and under ideal conditions on the Cawston Ostrich Farm near San Diego, California.

The general color of the eyeground is dull red, varied by a uniform sprinkling of lighter red, round dots and gray granules. The lower half of the fundus appears somewhat grayer in tone than the upper sectors. This appearance is probably due to the numerous opaque nerve-fibres that extend from all sides of the papilla as a center across the fundus to the periphery of the ocular background. The red coloration of the fundus is seen to be more intense towards the upper half of the eyeground. The optic nerve-entrance is very broad, oval in shape, and its contour resembles that of Rhea and the Tinamous. The margins of the nerve-head are very white and it is possible with the mirror to see all around the pecten. The centre of the disc, including the parts near the root of the pecten, is stippled with minute, brown pigment dots, like black pepper grains.

The *pecten* proper rises from the nervehead much like the same organ in the Tinamou, and presents, ophthalmoscopically, the appearance of a number of dull, dark, sepia-

brown tubercles. It does not project far forward into the vitreous cavity, while its outlines and contour may be distinguished both above and below the disc. The pectinate margins are formed of round or ovoid projections. These nodular masses also appear to constitute the body of the pecten.

The *macula* is situated about as it is in Rhea; it is not very striking in appearance, and takes the form of a crescentic arrangement of minute, gray dots. It is seen towards the nasal side of the disc near its upper end, and is not surrounded by the closed reflexing noticed in so many avian fundi.

Rheiformes

AMERICAN OSTRICH. *Rhea americana*. For an exact reproduction in color of the ocular background of this bird see Plate II, page 121, which shows the left eye; erect image.

The *coloration of the fundus* as a whole is buff, merging into dull red at the periphery. It is stippled all over with minute dots of a lighter tint, and much resembles the fundus appearances of the Tinamou shown in Plate V.

The optic disc appears to be a broad oval, made up of white and coarse nerve bundles that exhibit a faintly defined, fringe-like margin all around its periphery. Radiating for a distance of about two disc-breadths across the fundus are a few, dull-gray, opaque nerve fibres that finally disappear into the background.

The *macula* is situated slightly above and to the nasal side of the optic papilla. It is somewhat grayer than the surrounding eyeground; above, towards the outer side and below the fovea, are a few pale, bright-green reflex lines.

The *pecten* is a massive organ with saw-like margins, the serrations being of a lighter brown than the central body. The lower part of the pecten is somewhat club-shaped, and comes well forward toward the posterior capsule of the lens. Between the projecting teeth of the pectinate serrations may be seen a slight stippling of pigment-like black pepper grains.

Casuariiformes

WESTERMAN CASSOWARY. *Casuarus occipitalis*. The colored drawing shown on Plate III, page 123, is intended to reproduce an ophthalmoscopic view of the right eye by the erect image. Two birds (four eyes) furnished almost identical pictures.

The fawn-colored *eyeground* is covered with a minute, silver-gray stipple, in the form of fine, short lines with their long axes running in a vertical direction. As these dotted lines approach the macular region they become more and more convergent until they form a brilliant cluster at the fovea. There is no visible line of demarcation or reflex ring separating this area from the general fundus area. There are no visible choroidal blood vessels or opaque nerve fibres.

The *optic disc* is long and boat-shaped, with a reddish, apparently concave centre. It is uniformly sprinkled with darker red dots, which, as they approach the margin of the papilla, are more closely packed, and give the appearance of a shadow cast all about the inner edge of the disc. The margins of the nerve-head are distinctly white, but they have not the "fibrous" appearance seen in most avian backgrounds.

The chocolate-brown *pecten*, much broader at its base than at the apex, resembles a corkscrew, its lateral elevation being not unlike a cockscomb, with its six serrations rounded off at the apex. Two central serrations come well forward towards the lens.

Apterygiformes

MANTELL APTERYX. *Apteryx mantelli*. In July, 1914, the writer examined a Mantell Apteryx in the London Zoo. The animal was 12 years old and probably had monocular vision. The keeper said that (in daytime especially) the bird had poor eyesight for both distance and near. The bird's refraction was by skiascopy myopic (about 1.50 D.) in either eye. The fundus appearances are exactly as Head has depicted them in his drawing (Plate IV). In this fundus picture the *macular region* is plainly visible; and the *pecten* comes well forward and is also easily seen. The *ocular back-ground* is

uniformly orange-red, somewhat mottled with brown. The brilliant, white, round *disc* is surrounded by short, opaque nerve-fibre layers, not entirely covered by the fenestrated base of the long, large and conical *pecten*, whose pointed end reaches almost to the lens. There are no signs of choroidal bloodvessels.

Tinamiformes

RUFIOUS TINAMOU. *Rhynchotus rufescens*. (Figs. 117 and 78). A macroscopic picture of the *background* shows a slight and rather uniform pigmentation, darker towards the periphery.

The long, narrow comb-like *pecten* somewhat resembles, when seen from before backwards, a small crayfish. It is made up of from 48 to 50 convolutions, the dorsal crest forming an irregular triangle with a short spine projecting from its inferior end.

The *macula* is plainly marked above and on the nasal side of the *pecten*, about half a disc-length from the anterior terminal of the papilla.

MARTINETA TINAMOU. *Calodroma elegans*. A picture of the left ocular fundus (by the erect method) is furnished by Plate V, page 125. This taxonomically interesting species presents a background whose coloration is, in the main, a deep gray, the lower half merging into dull orange. The whole of the fundi is covered by a collection of tiny dots packed closely together. In the upper half of the field they are white, but from the region of the disc and downwards they become a dull orange color. Crossing the fundus and running vertically on either side of the papilla are several orange-red choroidal capillaries.

The *macula* appears as a dull-gray area, with a brilliant white central spot surrounded by a small, pale-green, streaked, reflex ring. It is plainly visible on the nasal side of the *pecten*. The optic nerve entrance is oval in shape and exceptionally broad.

The mass of the *pecten* almost completely covers the optic papilla, which is quite white and looks like a mass of coarse opaque nerve fibres. The optic margins are bordered with gray pigment, from which spring

a few short opaque nerve fibres. The pecten is chocolate brown, and in addition to its massive appearance is much shorter than the same organ in most of the birds examined. All parts and all details of this pecten can be viewed with the mirror without the least difficulty. It is easy to see that it is fringed all around with pointed tabs, that the central portion or ridge is serrated and that it comes well forward towards the lens. In examining the fundus with the ophthalmoscope through the undilated pupil the pecten seems to fill the pupillary area so that most of the fundus is obscured and shows through the fringe about the papilla as a light shines through a grating.

CARINATAE

Galliformes

YARRELL CURASSOW. *Crax globosa*. The fundus appearances of this bird are depicted as Plate VI, page 125, and are the result of an examination of four eyes in two specimens. The four backgrounds were found to be identical in all respects.

The *eyeground* is a dull, leaden gray covered with tiny, white dots. There are no visible choroidal vessels.

The *papilla* appears as a long oval, whose central zone is dull-orange mingled with minute, dark-brown dots. It also presents a marginal fringe of white. A few opaque nerve fibres extend on either side of the disc across the fundus, but for a short distance only.

The *pecten*, of spiral form, is colored dark chocolate-brown. It seems to taper quite decidedly where it joins the disc, and looks like the roots of a tree at its distal end, where the rootlets bury themselves in the disc. Just above the disc, some little distance to the nasal side of the pecten, is a round, gray, softly outlined area near which is seen a well-marked reflex of a pale blue-green tone.

BRUSH TURKEY. *Cathartus lathami*. Plate VII, page 127 depicts an ophthalmoscopic view of this species.

The *eyeground* is dull, slaty gray, underlying numbers of fine, light-gray dots. These dots are uniformly scattered over the fundus except towards the nasal side. Here, on a level with the superior end of the optic nerve and in the direction of the macular area, they are brilliant white, are closely packed together and are devoid of a reflexing.

Extending from either side of the optic disc and running at right angles to that organ are a few, rather fine, semitranslucent nerve fibres, which are lost towards the periphery.

The *optic disc*, whose upper end is shaped like the sharp bow of a boat, appears to be composed of a mass of brilliant, white, opaque nerve fibres.

The *pecten*, of the usual chocolate brown color, is massive and somewhat club-shaped. It extends well forward towards the lens and tapers rapidly as it approaches the superior end of the nerve.

CALIFORNIA VALLEY QUAIL. *Lophortyx californicus vallicola*. (Figs. 110 and 79.) An examination of this *background* with the naked eye discloses *no well-defined macular region*, at least not in this specimen; it may be that in better preserved material a shallow fovea can be isolated. The pecten presents anteroposteriorly an elongated, acuminate figure with 30 convolutions, or 15 folds, regularly disposed on either side of a straight, linear, median crest, that runs the whole length of the upper aspect of the free border. The convolutions are separated at several points, especially near the middle, so that glimpses of the dotted, whitish *optic entrance* beneath may be seen.

HARLEQUIN QUAIL. *Coturnix histrionica*. The remarkable fundus of this bird, viewed with the ophthalmoscope, is portrayed as Plate VIII, page 127, of this monograph. The picture is the result of an examination of several individuals, all exhibiting identical *eyegrounds*.

The *general color of the ocular background* is light gray sprinkled with minute granules, which give it the appearance of a rough surface. This granular surface appears

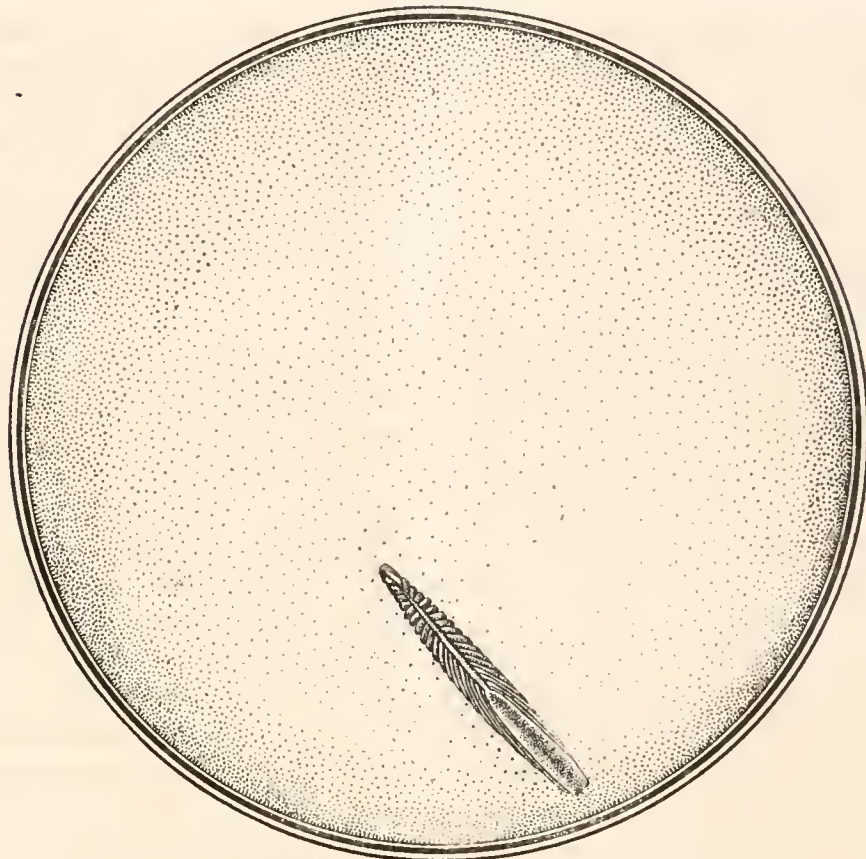


Fig. 118. Wonga Wonga Dove (*Leucosarcia picata*) $\times 10.5$.




Fig. 119. British Wood Pigeon (*Columba palumbus*) $\times 10$.

Macroscopic Appearances of the Fundus Oculi in the Preserved Eyes of Birds.

white or light gray when directly illuminated with the reflected light of the ophthalmoscopic mirror.

The *optic nerve-head* gives one the visual impression that it is formed of brilliant, white, short, coarse, opaque fibres. Its shape is unusual, being long and narrow, with a rather striking resemblance to the projecting, serrated jaws of the Sword Fish. Extending along each side of the optic disc, at right angles to it, are a few rather pale, thin, opaque nerve fibres.

The *pecten* is lighter brown in color than usual, and is very narrow at its junction with the papilla. On either side of it are a few minute dots of brown pigment. The inferior segment of the pecten forms a corrugated, bulky mass which, however, extends well forward into the vitreous cavity to the posterior surface of the lens. No definite macular region was discovered in the various specimens examined.

Columbiformes

WONGA WONGA DOVE. *Leucosarcia picata*. (Figs. 118 and 81; macroscopic views.) The retina in the eyes of the one specimen examined showed an unusually smooth membrane.

The long, narrow *pecten* resembles the "comb" of the Wood Pigeon, and projects into the vitreous like a house-heating radiator with about 19 coils, forming 38 (or more) convolutions in all. The ridge-like crest conceals the upper middle line of the pectinate mass which, in its turn, entirely obscures a view of the optic entrance. The lower free border of the marsupium appears as a broad parallelogram covered with pigment grains, contrasting sharply with the superior end, which comes gradually to a rounded point.

There is *no well-defined macular or foveal area*.

As shown in Plate IX, page 129, the ocular background of this species presents, when examined by the ophthalmoscope, a uniform, gray tint. White dots, lighting up the fundus, are scattered over the entire field. A few choroidal capillaries are to be seen.

The *optic disc* forms a long oval; it appears as if it were composed of a collection of white fibres, and these seem bunched together for about one-half the length of the pecten. Opaque nerve fibres radiate from the circumference of the papilla, while several orange-red (choroidal) vessels, interspersed with pigment dots, run on either side of it.

The *pecten* appears as an exceptionally long, corrugated, dark-brown mass. Seen through the mirror from above it has the appearance of a piece of tarred rope.

The *macular area* is seen to the inner side of the disc and a little above its upper end. The sheen of the pale-green reflex that plays about it when illuminated by the light of the ophthalmoscope looks like watered silk. The fovea has the appearance of a small green flare, something like that from a bull's-eye lantern seen close at hand. Only one macula can be seen.

BRITISH WOOD PIGEON. *Columba palumbus*. (Figs. 119 and 80; macroscopic views.) The *background* of this species shows an elongated, pointed, ovoid *pecten*, made up of closely fitting plications (about 34 in number) joined in a free upper margin. The main body of the pecten is not concealed, as it usually is, by the crest or line of junction above, which has an abrupt flattened appearance below, an acute sloping termination above.

A faint and *doubtful foveal depression* is noticeable above and slightly to the nasal side of the disc in some specimens examined but this area does not show plainly in the individual here pictured.

The ophthalmoscopic appearances in this species are depicted in Plate X, page 129.

The general tint of the ocular background, as seen by the erect image, is pale slate-gray. The eyeground is covered with very small, dull-white dots so that the whole fundus presents a lighter shade of gray than it otherwise would. On the lower half and each side of the optic disc are seen several orange colored choroidal blood-vessels, which become more numerous as one approaches the periphery. Extending at

right angles to the papillary margin are a few opaque nerve fibres.

A little above the superior end of the optic nerve-head and towards the nasal side, is a small, round, apparently somewhat depressed *macular area* of a dull-gray tone. From its margins runs a double row of fine, blue-green, translucent lines which form about it a broken or irregular reflex ring. The bird becomes unusually restless when the light from the ophthalmoscopic mirror is focused on this part of the fundus.

Glimpses of portions of the *optic disc* show it to be dead white, and it seems to have a fringe of short fibres of the same color all about its edges. At the junction of the pecten with the nerve-head, i.e., along the central area of the latter, one sees numerous brown pigment dots that appear like small rootlets or capillaries and give a reticulate appearance to the papilla.

The *pecten* itself has a dark chocolate-brown color and a corkscrew contour; it is unusually long and narrow, and its lower segment appears to come well forward towards the lens.

VICTORIA CROWNED PIGEON. *Goura victoria*. The fundus oculi of this species, depicted as Plate XI, page 131, right eye, erect image, is of the usual gray color seen in Pigeons and Doves. The eyeground generally is covered with minute white dots. On the upper and nasal side of the fundus is the macula, a small dull-gray area surrounded by a gray and green reflex of small lines.

The *optic disc* is long, narrow, boat-shaped and a little rounded at the upper end. It looks as it were rather hollow and gray in the centre, with a white rim all around. A network of small, brown, pigment dots is disposed along the centre on either side of the pecten; and some opaque nerve fibres extend across the fundus on all sides of the nerve.

The *pecten* is of the usual dark, chocolate tint. It is corkscrew-like in appearance, but one end is rather club-shaped and looks as if it were covered with small brown nodules. This segment comes well forward towards

the lens, but not so much as in the Wood Pigeon; otherwise the fundus closely resembles the eyeground of that bird.

Ralliformes

AMERICAN COOT. *Fulica americana*. (Figs. 120 and 84.) The *background* of this species, maoscopically considered, shows, obliquely across the fundus but not reaching the periphery at either end, a "split stiek" figure—a narrow *band of unpigmented retina* depicted by two dotted lines of pigment, the line towards the optic disc containing more granules than the other. Midway between the two ends of this figure is a circle of pigment, twice the width of the band itself, made by an extension of the pigmented borders that form the boundaries of the band. In the exact center of the circle is a plainly marked pigment dot.

The large, thick *pecten* is wider at its middle than at either end. It has about 32 clearly defined convolutions, or 16 double folds. When seen from above one may perceive between these plications not only the black central body of the pecten but the papillary edges. The free border of the pecten has no definite keel but the upper margins of the convolutions join to form a serrated wavy line reaching from one terminal to the other. This practically naked, saw-like crest is unusual in the pectens the writer has examined.

The long axis of the *papilla* prolonged to meet the retinal band makes with it an angle of about 70°, the *infulapapillary angle*.

CRESTED COOT. *Fulica cristata*. In the several specimens examined ophthalmoscopically, the fundus appearances of this Australian bird (see Plate XII, page 131) were practically identical. The colored reproduction presents the left background by the usual direct method.

The predominant color of the *eyeground* is dull gray, everywhere sprinkled with minute, white dots that are more clearly seen above the superior termination of the optic nerve and to the nasal side of the pecten. Although this area is (judging from the effect of the light thrown upon various

THE FUNDUS OCULI OF BIRDS

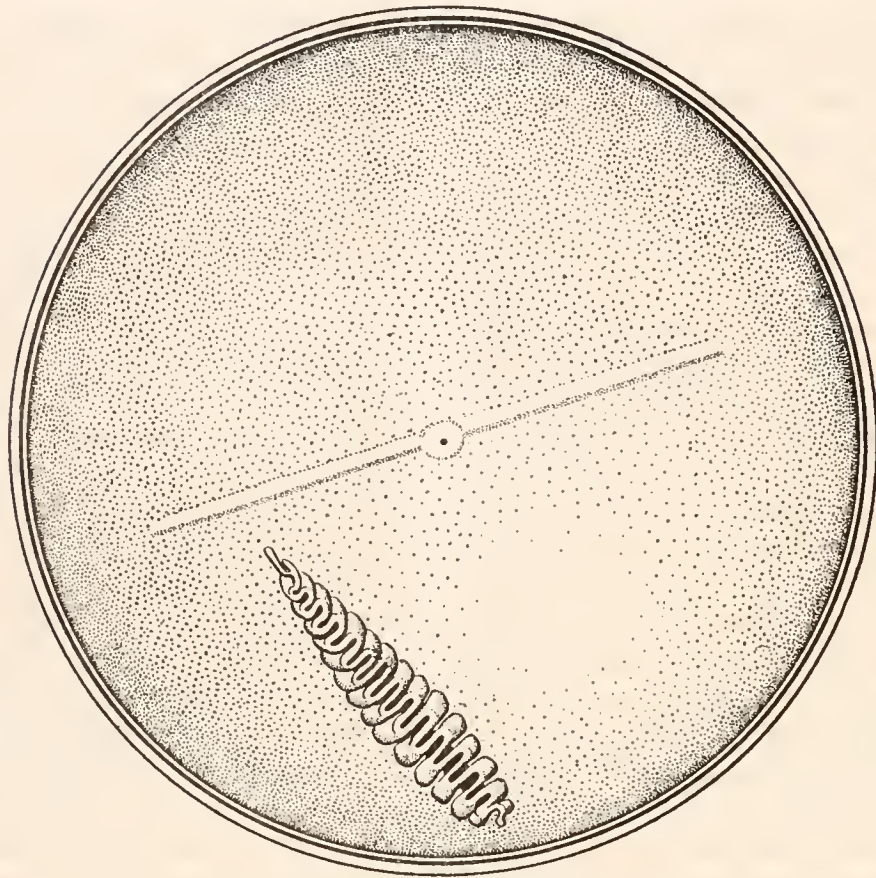


Fig. 120. American Coot (*Fulica americana*) $\times 11$.

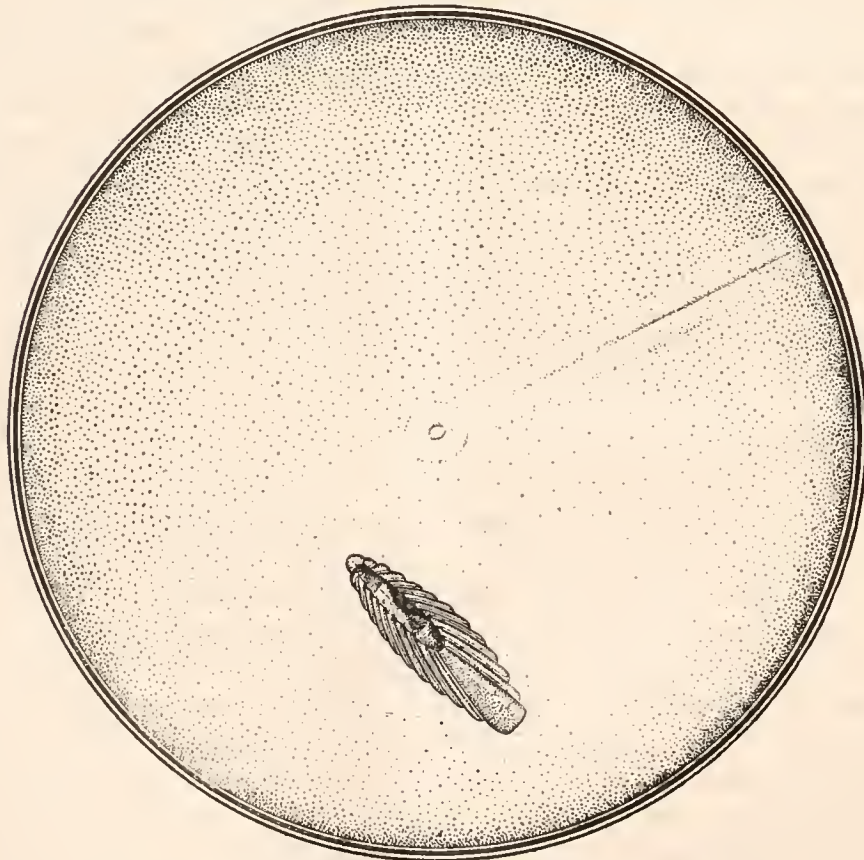


Fig. 121. Great Crested Grebe (*Podiceps cristatus*) $\times 12$.

Macroscopic Appearances of the Fundus Oculi in the Preserved Eyes of Birds.

quadrants of the fundus by the mirror) very sensitive to light there is no other ophthalmoscopic indication of a macular region.

The long *optic disc* is white, with a few tiny pigment dots about its margins. The *pecten* is lighter brown than in the majority of birds; it is very large, almost hiding the disc from view. Many opaque nerve fibres radiate from the papillary circumference and extend several disc breadths across the fundus. Owing to the large size of the pecten and the small pupil it is impossible to obtain a satisfactory lateral view of the pecten, which almost covers the pupillary area with its massive club-shaped end.

The American congener of this bird—*Fulica americana*—has a fundus almost identical, ophthalmoscopically, with this species.

IPECAHA RAIL. *Aramides ipecaha*. The ophthalmoscopic picture of this bird, representing the right eye, is seen as Plate XIII, page 133.

The *eyeground* is a very pale uniform gray stippled with darker gray and white dots, thus giving the whole field a granular appearance.

The horizontally oval *macular area* (on the nasal aspect near the upper end of the disc) assumes a pinkish tone. At its center is a small pit which, in the light of the mirror, appears as dark gray with a brilliant, white central dot. Around the macular region is a pale, blue-gray reflex, which loses itself in the general tone of the fundus but appears quite sharp on the inner side of the oval macular region.

The *disc* is a narrow, white oval, whose major axis measures about one-third the height of the pecten. A number of opaque nerve fibres run across the background at right angles to the papilla and fade into the general gray of the fundus.

The *pecten* arises from the upper segment of the disc, spreads out on it like the root of a tree and gradually disappears into the papillary substance. From this root a long, slender, spiral form projects into the vitreous. It is brown in color, is of uniform width, looks like a corkscrew and extends forwards and outwards as far as the eye can see,

looking as if it were pressed against the lower part of the lens. The anterior end of the pecten is much darker in color than its posterior half, which is quite flat.

The fundus oculi of the Weka Rails (*Ocydromus*) is quite similar to the ocular background of this specimen.

Podicipediformes

GREAT CRESTED GREBE. *Podiceps cristatus*. (Figs. 121 and 83.) A macroscopic examination of the *fundus oculi* in this species reveals a broad *retinal band*, uniform in width, that extends from the nasal periphery across the fundus and is lost in the pigment of the opposite side. It is half as wide as the minor axis of the oval disc and, along its whole length, is depicted by two parallel lines of pigment dots—the inferior border containing the more numerous grains. The nasal half of the wide band is bisected by a narrower, almost linear, ribbon composed of minute black dots that are most numerous at the periphery of the field, becoming fainter and fainter until just before the macula is reached, when they disappear altogether.

At about a long papillary diameter from the superior end of the pecten and on its nasal side, is a large, circular, partly pigmented, disc-like *macular region* arranged within and somewhat exceeding the limits of the retinal band. It has, in its turn, a central, depressed lighter area, surrounded by a small ring of pigment.

The *pecten* covers the optic entrance, and has the steam radiator-like form of the Wonga Dove. However, this species exhibits 24 convolutions, the free border shows three definite elevations above and it has a deep, opaque keel to which all 12 double folds are firmly united.

The angle made by projecting the major axis of the oval optic papilla until it bisects the lower border of the retinal band, the *infulapapillary angle*, is, approximately, 70°.

In injected specimens of this species (as well as occasionally in individuals not so treated) the choroidal vessels show very plainly.

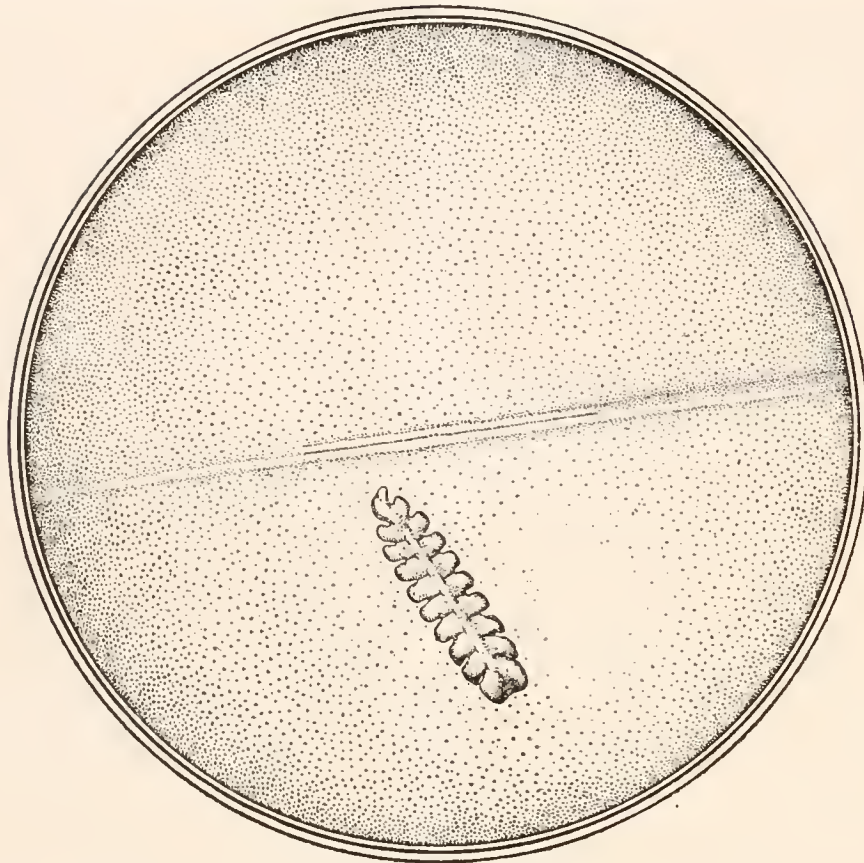


Fig. 122. Dark-bodied Shearwater (*Puffinus griseus*) $\times 9$.

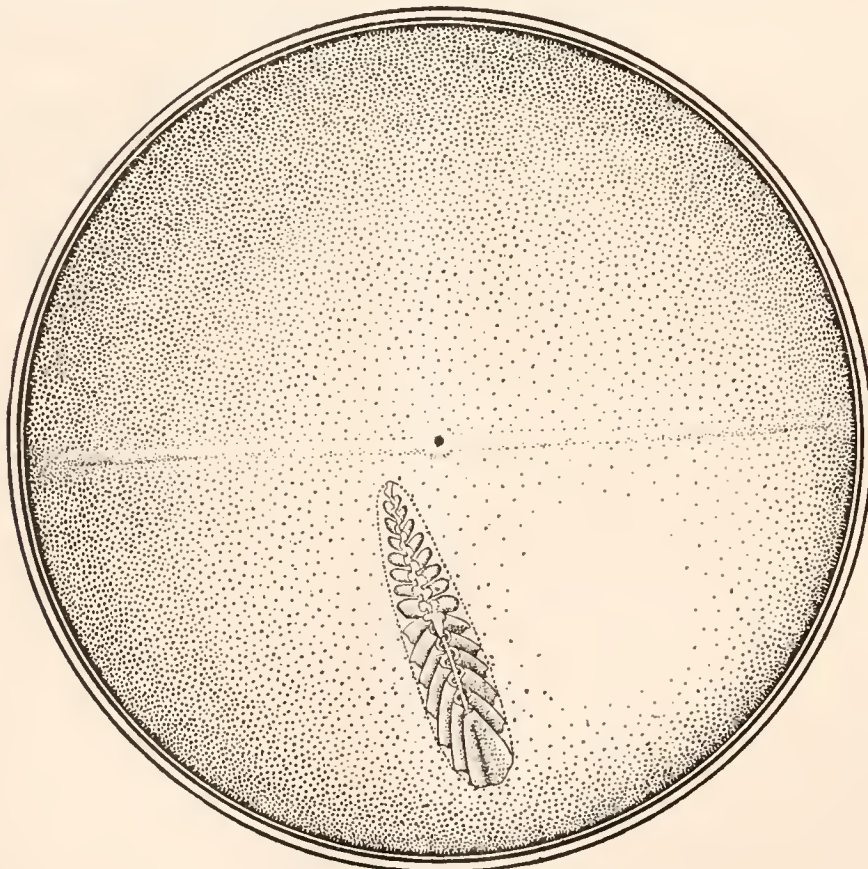


Fig. 123. Pigeon Guillemot (*Cepphus columba*) $\times 9$.

Macroscopic Appearances of the Fundus Oculi in the Preserved Eyes of Birds.

Colymbiformes

PACIFIC LOON. *Gavia pacifica*. The writer has never been able to examine more than one individual of this species, or any other Diver. He was obliged to use the ophthalmoscope, with little protection from the blazing sun of a Californian noon-day, upon a recently dead bird. The examination was necessarily incomplete. The fundus was light gray, dotted over with dark pigment granules; the pecten was large and there was a well-marked *porus opticus*.

Sphenisciformes

BLACK-FOOTED (CAPE) PENGUIN. *Spheniscus demersus*. The eyeground of this species is depicted as Plate XIV, on page 133 of this monograph.

The dominant color of the fundus is bright red shading to crimson. It is generally stippled with minute, dark-red and orange dots, much like grains of sand. About a disc-length from the upper end of the optic disc these dots become grayish-white; indeed, the fundal coloration is distinctly gray towards the upper half of the eyeground. In a region the same distance towards the temporal aspect of the background may be seen a cluster of pinpoint, brilliant, white dots in the macular area. Penguins use the nictating membrane very frequently when light is thrown on this part of the eyeground.

The optic disc exhibits enamel-white edges; it is hollowed out in the centre, like a sewing-machine shuttle. Running across this concavity and at right angles to the margin of the disc one sees a large number of gray fibres.

The pecten lies along the centre of the nerve, where it is orange-red in color and mottled with minute, brown pigment dots. The pecten has the usual dark chocolate-brown shade. It is of spiral form, like a corkscrew laid on its side. A few slender opaque nerve fibres are visible on each side of and at right angles to the disc.

Procellariiformes

DARK-BODIED SHEARWATER. *Puffinus griseus*. (Figs. 122 and 85.) The fundus of this species, as seen by the naked eye,

exhibits a darkly outlined band, widest at the nasal extremity and at its middle, with irregularly pigmented borders and a lighter center, runs across the field of view from one periphery to the other. Its central third is shown as uncolored except for a line of pigment that divides it into two equal strips—thus constituting a linear fovea, the circlet seen in some other band-like areas being absent.

There are 20 convolutions in the rather short, thick pecten. These double coils are so divided where they join the comparatively narrow sloping crest that glimpses may be had of the nerve head below. The keel covering the upper portion of free border is prolonged into a blunt, rounded process, partly formed by the larger and higher posterior "teeth" or segments of the marsupium.

What has by the writer been termed the infulapapillary angle is 55°. This is made by projecting the major axis of the papilla to meet the lower margin of the transverse sensitive area of acute vision.

Alciformes

PIGEON GUILLEMOT. *Cephus columba*. (Figs. 23 and 82.) The background of this species, when viewed macroscopically, reveals a narrow, uniform, pigmented retinal band that stretches across the field of view from one periphery to the other. At a point where it approaches the superior end of the papilla is placed a circular area (the fovea) whose diameter is twice the width of the band.

The pecten is remarkable in that it rarely obscures a view of the margins of the long, broad, ovoid, optic nerve-head, which has its pointed extremity upwards. There are 30 convolutions in the pectinate mass, and occasional views can be had of the papilla through clefts in it. The ridge-like, free border of the pecten is linear for a third of its length below but follows the undulations of the convolutions beneath it until it reaches its superior end. The double folds in this organ are longest and most voluminous at their middle, where the

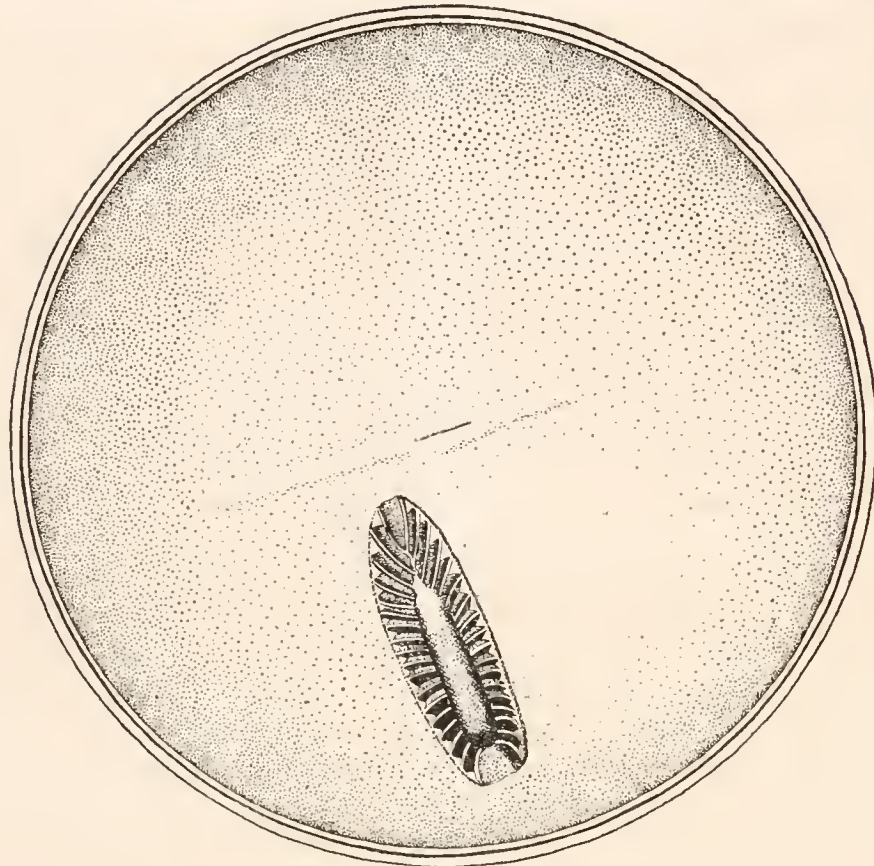


Fig. 124. Herring Gull (*Larus argentatus*) $\times 7.5$.

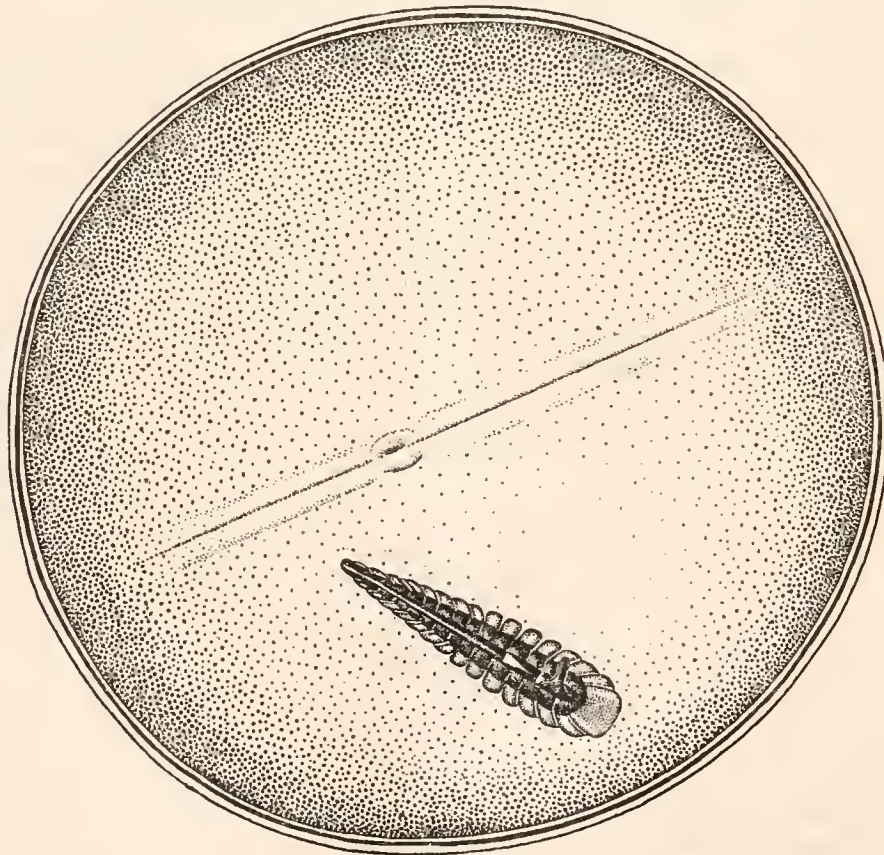


Fig. 125. Hudsonian Curlew (*Numenius hudsonicus*).

Macroscopic Appearances of the Fundus Oculi in the Preserved Eyes of Birds.

crest or keel is elevated to a sharp point, and towards which the other folds are inclined. They gradually decrease in size towards both the posterior free margin—an unusual disposition—and to the anterior or superior terminal of the optic entrance, in accordance with the rule.

The longer axis of the disc projected until it meets the retinal band makes with the latter an *infulapapillary angle* of about 65°.

PUFFIN. *Fratercula arctica*. The eyeground of this remarkable species is portrayed as Plate XV, page 135. It represents the left eye as seen by the direct ophthalmoscopic method.

The general color of the eyeground is red, rather uniformly stippled with small, mixed, light-red and dark-gray dots. Above the upper end of the optic disc and towards the temporal side is a small, round, red area surrounded by a pale, light-gray film, shot with bright lines on the outer and inner margins—doubtless the *macular region* with its central fovea. Head noticed that not only this area but most of the upper half of the fundus is very sensitive to light.

The *optic papilla*, oblong, narrow and with a rounded upper extremity, lies low down in the eyeground, while the pecten extends well forward and behind the lower margin of the pupil. A view of the nerve-head is much obscured by the body of the massive pecten which almost covers it when seen, as with the mirror, from above downward. The small segment visible with the ophthalmoscope appears not brilliant white but rather a bluish-white, the margins of the pecten being covered with black pigment.

Extending at right angles to the disc on both sides are a few very fine, gray opaque nerve fibres, that finally disappear in the fundal periphery. The *pecten* is of the usual chocolate-brown color and comes well forward towards the lens, especially in its inferior aspect.

Larifformes

HERRING GULL. *Larus argentatus*. (Figs. 124 and 86; macroscopic view.) In this species the upper and more pointed extremity of the *pecten* points slightly to the temporal

side of a linear *fovea* that is drawn as a rather broad, short, retinal *band* that skirts the clear area and stretches in a slightly oblique direction across about one-third of the central field. The foveal slit (nearly as long as the optic disc is wide) occupies a widened portion of the band-like process and shows a line of pigment dots along its upper margin.

The very broad, long *pecten* covers an equally large papilla. It has 36 thin, leaf-like convolutions which, in prepared specimens, do not obscure the margins of the nerve-head, whose canoe-shaped outlines are everywhere visible from above, except at the bow and stern. The free border, comparatively wide, is deeply pigmented, does not reach the superior extremity of the pecten and has the appearance of an ear of maize. The medial and posterior leaflets of the pecten are the longest, only the anterior five becoming smaller as they approach the upper extremity of the papilla.

The infulapapillary angle measures about 60°.

The *ophthalmoscopic appearances* of the background are the same in both the European and New World species. A large number of healthy individuals were examined both by Mr. Head and the writer.

The *ocular background* of this bird is quite similar to that of *Larus marinus*. The prevailing color is dull brown, the upper half being interspersed with masses of small gray dots, that assume a pink hue downwards from the upper end of the optic disc. One notices in this region, also, many dull-red, choroidal capillaries that run parallel to the sides of the elongated nerve-head.

A little above the upper end of the papilla, towards its inner or nasal side, is the *fovea centralis*, a brownish red dot, in the centre of a rather dull area. This macular region is enclosed by two clear, bright green rings, or reflex circles.

The *optic disc* (papilla) appears to be made up of very short, brilliant white and rather coarse opaque nerve fibres. Extending from its margins are a few, dull-gray, opaque nerve fibres, that radiate from the elongated papilla but fade away in the periphery of the background.

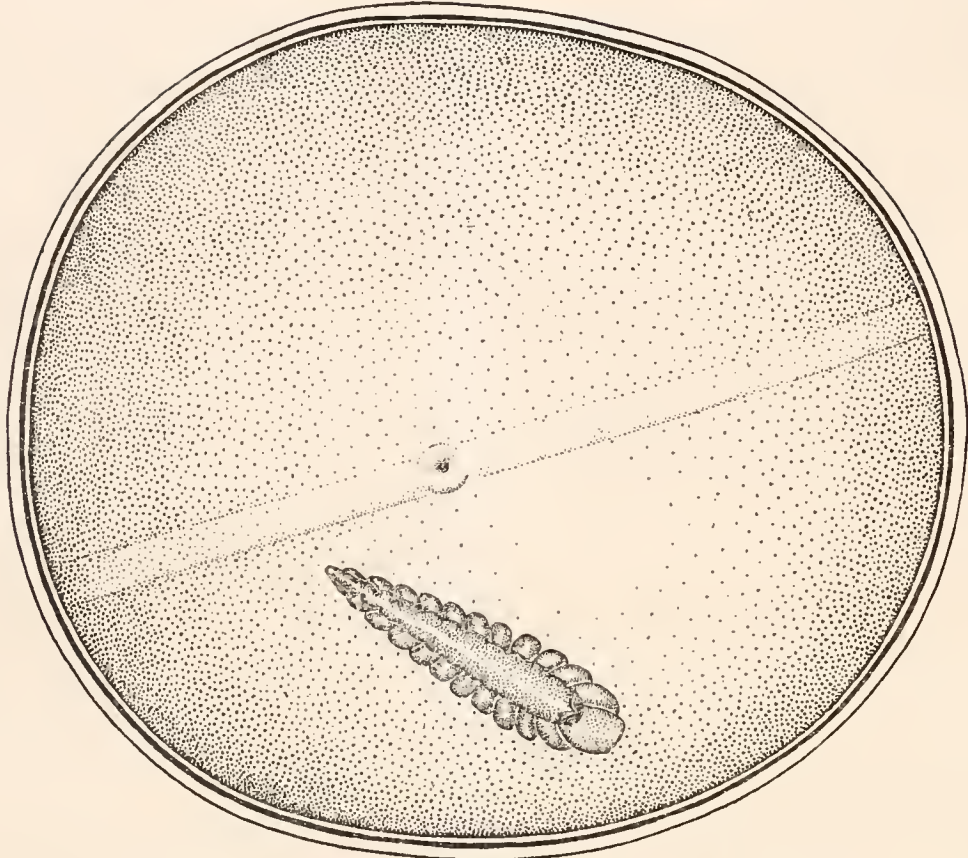


Fig. 126. Black-bellied Plover (*Squatarola squatarola*) $\times 9$.

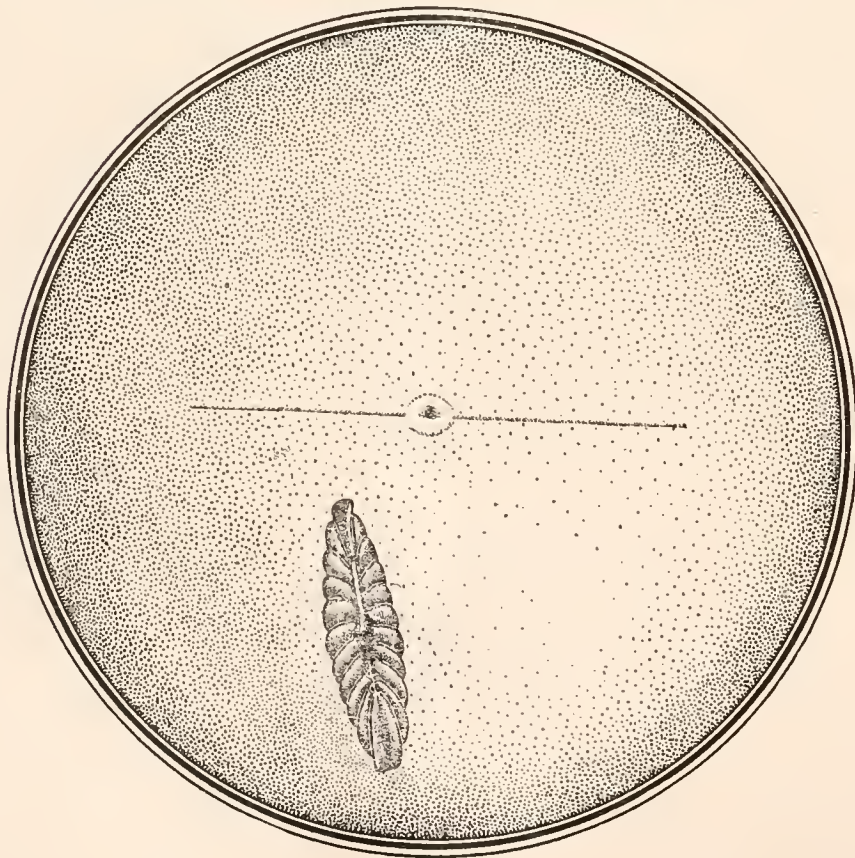


Fig. 127. Great Bustard (*Otis tarda*) $\times 5\frac{1}{2}$.

Macroscopic Appearances of the Fundus Oculi in the Preserved Eyes of Birds.

The *pecten*, of the usual chocolate-brown color, is divided into (about) fourteen convolutions, which are more massive below. They extend well forward towards the lens.

At the apparent junction of the pecten with the optic nerve the disc is rather orange-red in tone.

GREAT BLACK-BACKED GULL. *Larus marinus*. Plate XVI, page 135, depicts the fundus appearances of the left eye in this species. The general coloration of the eyeground varies from a dull gray to a dull brown — mostly the latter — traversing which are many reddish, choroidal bloodvessels running more or less in a vertical direction. It is the number and visibility of these capillaries that give the red tone to an eyeground essentially gray.

The *optic disc* is a long, narrow oval, quite white, with a quantity of fine gray lines radiating in all directions from the papillary margin. On the inner aspect of the eyeground the macula is seen. It is situated about one disc-length from the upper end of the pecten and half a disc-length above the end of the same organ on the inner side.

The *macula* resembles a blue-green flake of iridescent glass. It is of oval shape with a reddish-brown center, which, however, is unprovided with a reflex ring.

The *pecten* appears to be in folds; the lower, or broader, portion extends well forward towards the lens and turns towards the nasal side of the bird's head. The inner quadrants of the fundus are more easily seen with the ophthalmoscope than the outer half but, so far as the latter area is visible, there is no sign of a second macula on the outer part of the eyeground.

Charadriiformes

BLACK-BELLIED PLOVER. *Squatarola squatarola*. (Figs. 126 and 89; macroscopic view.) Preserved eyes of this species present a moderately broad, grayish *retinal band*, whose borders, drawn as pigmented throughout, extend somewhat obliquely across the fundus from one margin to the other. Near the middle point of this retinal area is a circular, crateriform disc so set in the ribbon-like figure that its circumference is not pig-

mented within the band proper but is continuous with the tinted borders themselves. In some individuals there are traces of a groove in the retinal band.

The *pecten* in shape resembles that of the Hudsonian Curlew. It has 24 sausage-like convolutions; its fringed keel being prolonged at the inferior extremity into a spinous process that (not shown in the cuts) follows the concavity of the eyeball and almost reaches the margin of the lens. One-third of the coils present a concave surface to the posterior free margin.

The infulapapillary angle is about 50°.

In prepared specimens the eyeball is ovoid, with axes 8:9. In some individuals, also, there are traces of a groove in the retinal band.

HUDSONIAN CURLEW. *Numenius hudsonicus*. (Figs. 125 and 88; macroscopic view.) The *background* of this bird's eye shows a broad, grayish *band*, with evenly dotted borders, that extends almost horizontally across three-fourths of the visible fundus. It is equally divided throughout its whole length into two parts by a plainly marked line.

The major axis of the papilla projected towards the band describes with the latter an angle of 50°. It bisects it half the axial length from the crater-like fovea.

The *pecten*, carrot-shaped from above, has a fringed cap covering its upper free border. It exhibits 34 convolutions, the spaces between the middle ten being deep enough to allow a glimpse of the optic margins, that are elsewhere completely covered. The black, free margin corresponds in shape to the pectinate body, being quite broad below, narrow and pointed above. Its inferior third is prolonged (into the vitreous) in the shape of two conical elevations and a long, single notched spine. The crest gradually slopes from behind forward so that the posterior-coils are the longest. Two-thirds of the coils "face" forward.

GREATER YELLOW-LEGS. *Totanus melanoleucus*. (Figs. 114 and 87; macroscopic view.) In this species a broad *retinal band*, faintly depicted with pigment lines, extends across the entire visible field, its nasal half being divided by a double-dotted line that

ends at the pigmented circumference of the circular macula.

The *macular region*, twice as wide as the surrounding band, presents a large, central fovea.

The *pecten* has much the same shape as in Squatarola; it is, however, a little larger, and has 32 convolutions. The medium sized coils, longer (taller) as one approaches the posterior free margin, are capped by a deep, irregular, partially serrated, ridge-like crest that terminates posteriorly in a sharp point; anteriorly the crest becomes much narrower, and ends in a tapering triangle.

The *optic entrance* is (at its middle) seen through the interrupted coils of the pecten; and the infulapapillary angle, made by its projected major axis and the lower margin of the retinal band is between 45° and 50° .

The shape of this eyeball is oval, 10x11.

STONE PLOVER. *Ædicnemus scolopax*. The fundus appearances (left eye, erect image) of this nocturnal bird are depicted in Plate XVII, page 137.

The *eyeground* is a warm brown or chocolate color, rather deeply pigmented near the periphery and covered with orange-red dots that are very densely packed on the upper half of the fundus. Below the optic entrance are numerous choroidal vessels running parallel with and on either side of the papilla.

The *macula* is difficult to distinguish and is not clearly defined with the ophthalmoscope. It is situated above the superior end of the disc on its inner or nasal side, and about half the apparent length of the pecten from the upper end.

The fundus coloring is slightly darker in the macular area, which is surrounded by a reflex ring, pale gray in color, in the form of very minute lines radiating from its margins. There are, also, a few radiations near the *fovea centralis*.

The *papilla* is white, oval in shape, fringed all round with dense black pigment, and a few gray, opaque nerve fibres are seen on either side of it.

The *pecten* is very large and projects well into the vitreous. It is of unusual shape, rather narrow, but when examined from above

looks as if it had been compressed and flattened on both sides, with a narrow edge above.

GREAT BUSTARD. *Otis tarda*. (Figs. 127 and 90.) The macroscopic reproduction of this *background* shows a narrow line of pigment, representing the usual *retinal band*, which extends horizontally across the central two-thirds of the visible fundus. At almost its exact middle is an incompletely oval area encircled by a ring of pigment grains. A dark spot (fovea) more or less surrounded by black dots, occupies the centre of this crater-like space.

The large and compact *pecten* forms a very regular, oval figure whose extremities appear to be of practically the same shape and size. It is made up of about 22 convolutions united in a crest that, from above, takes on the appearance of a fisherman's (cork) floater. The pecten in this species is remarkable because of the small number and large size of its folds, because the central five of these are the longest, and because the middle half of the keel, or crest, is projected as a tall cone into the vitreous.

The major axis of this optic disc subtends an infulapapillary angle of 70° with the linear retinal band.

Gruiformes

KAGU. *Rhinochetus jubatus*. In many respects the eyeground of this bird, as seen by the ophthalmoscope, presents appearances (see Plate XVIII, page 137) similar to the fundus pictures (Plate XVII, page 137) of the Australian Stone Plover, except that the former has a gray area above the disc, instead of a red and brown one. The drawing is of the right eye, as seen by the erect image.

The *background* is, in general, covered with a mass of minute dots that are gray in the upper half of the fundus and orange below. The lower sectors of the fundus are stippled with pigment. Choroidal vessels are numerous and run in rather straight, vertical lines on both sides of the optic disc. They are dull-orange in color.

The *fovea* is shown towards the anterior or nasal half of the retina, and appears as a round hole or crater-like depression, brown in color, which reflects a grayish sheen from its

center. A narrow gray circle or reflex ring surrounds this pit.

The *optic disc* has its central portion apparently stippled with bright orange-red dots, while its margin is fringed with coarse, white fibres, that are also studded with brown pigment dots especially near the outer border.

The *pecten* is of the usual deep, chocolate-brown color, rather narrow where it joins the disc but becoming much thicker and more massive as it projects into the vitreous towards the lens.

BRAZILIAN SERIEMA. *Cariama cristata*. This species presents an ophthalmoscopic picture of the right eye, erect image, that is reproduced as Plate XIX, page 139. The dominant color of the fundus oculi is a dull-drab. Over the lower quadrants of the eyeground run rather straight, dull-red, choroidal capillaries that fade away as they reach the upper half of the field. This region is also shot with a greenish-blue muslin-like film, which is probably a reflection by the retina of light rays from the ophthalmoscopic mirror. Above the end of the disc is a small, round depression, quite clear of any reflex. To the inner or beak side of the eye is the circular macula, whose diameter is about three times that of the cavity at the end of the disc. The center of the larger circle is quite clear, with the exception of a bright shimmer, such as is sometimes seen about the human fovea. The circumference of this circle is very sharply defined, and has a bright ring around it of glistening white.

The *optic disc* appears as a long, white oval, with irregular margins.

The black-brown, corrugated *pecten* is very large and long; it extends into the vitreous and almost touches the lens with its club-shaped terminal. Very fine opaque nerve fibres radiate at regular intervals from the whole papillary circumference.

In two eyes of this bird examined by the writer there were, in addition to the appearances just detailed, several scattered, reddish-brown deposits, very slightly pigmented, in the choroid. These were found in an individual captive in the Bronx Park for four or five years, and were probably pathological.

Ardeiformes

AMERICAN BLACK-CROWNED NIGHT HERON. *Nycticorax nycticorax nœvius*. (Figs. 92 and 129; macroscopic view.)

There were no definite, naked-eye indications of a fovea in the individuals examined.

The *pecten*, more pointed at its superior extremity, exhibits 20 convolutions, so separated that a view of the disc borders is here and there obtained. The pectinate coils are united by a narrow, cord-like crest that extends on the same plane and in a straight line (except that at its middle point it is slightly higher) along the upper free border from one extremity to the other. The coils do not differ much in length.

EUROPEAN NIGHT HERON. *Nycticorax nycticorax*. Seen with the ophthalmoscope the *eyeground* (see Plate XX, page 139) is dull gray, covered with grayish-white dots. The lower part of the fundus exhibits a number of faint, reddish choroidal bloodvessels, that run in a vertical direction, and whose disposition is similar to the capillaries seen in the fundus of the Boatbill, depicted in Plate XXII, page 141.

The *optic disc* is long, but of medium width, with both extremities rounded. Its center is orange-red and covered with minute, brown pigment dots.

The *pecten* is deep brown and its outlines are well defined the whole length of the papilla. Very thin grayish radiations extend from the upper two-thirds of the optic entrance.

The *macula* is situated quite close to (and towards the upper nasal aspect of) the disc. It is surrounded by an outer ring of whitish lines; then, towards its centre is a zone resembling the surrounding, punctated retina. In its exact centre is a small fovea composed of gray-white striæ.

GREAT WHITE HERON. *Ardea occidentalis*. The individual examined by the writer had been in captivity at the Bronx Park for several years and was slightly myopic. The eyegrounds of both eyes appeared identical and the ocular organs were normal. The pupil contracts under the strong light of the ophthalmoscopic mirror to medium size.

THE FUNDUS OCULI OF BIRDS

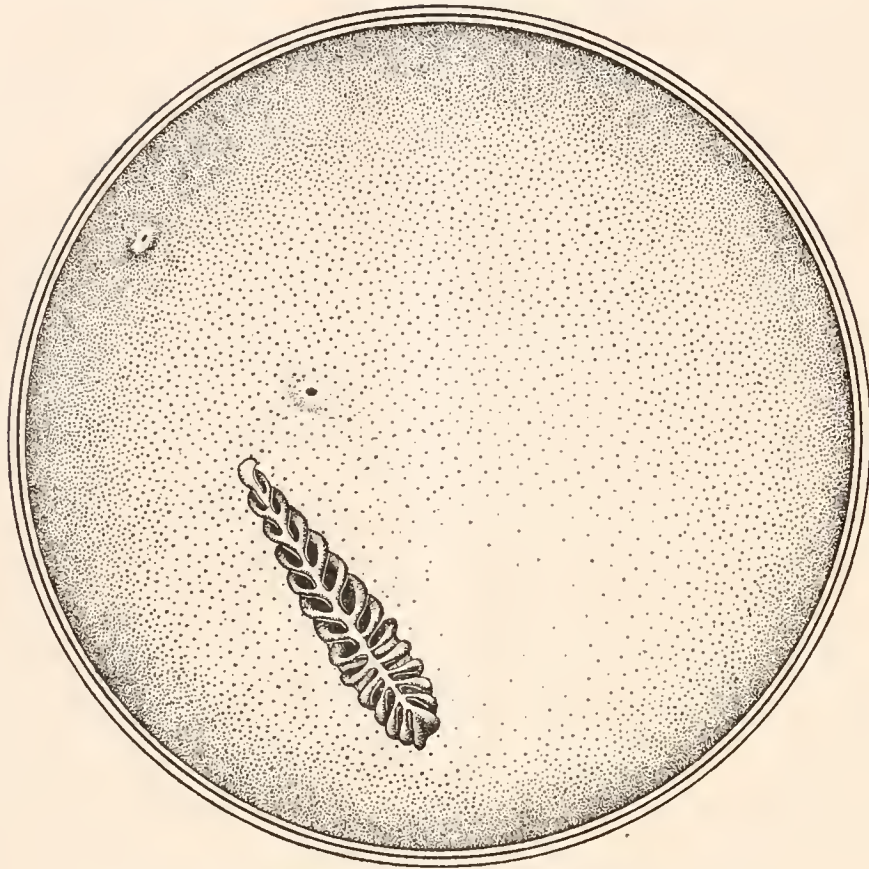

Fig. 128. American Bittern (*Botaurus lentiginosus*) $\times 8$.

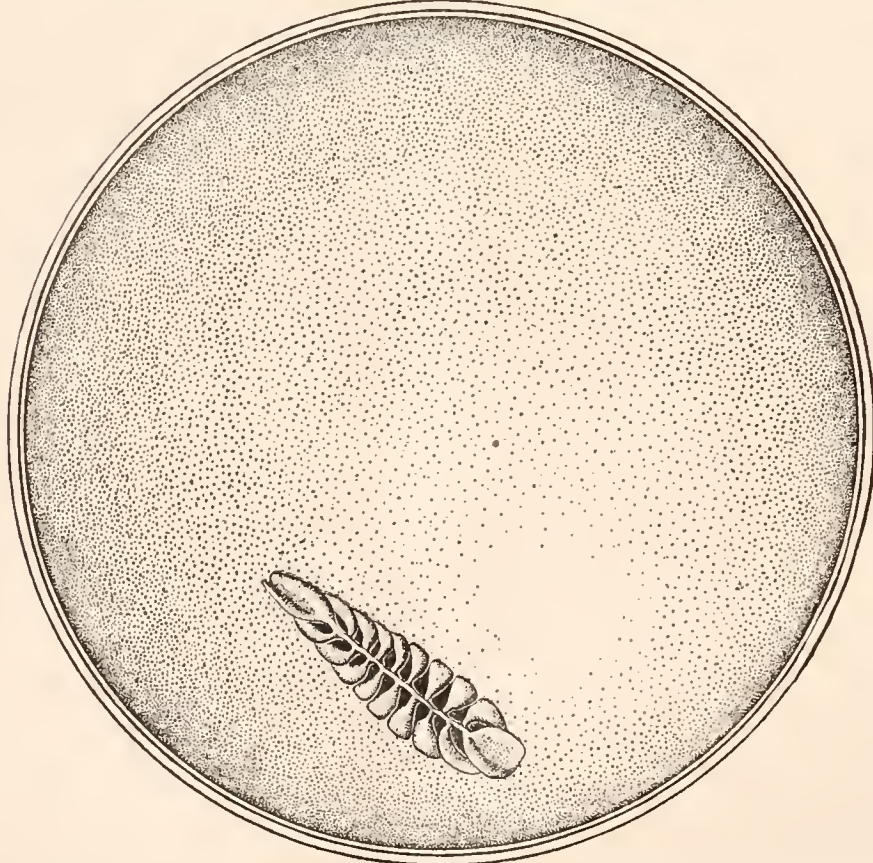

Fig. 129. Black-crowned Night Heron (*Nycticorax nycticorax naevius*) $\times 6$.
Macroscopic Appearances of the Fundus Oculi in the Preserved Eyes of Birds.

The dominant *color of the background* is light-reddish or brownish-gray and has apparently a granular surface.

The *papilla* is white, almost entirely covered by the pecten and seems shorter than in most birds.

The *pecten* is unusually large; only its free end, which is blunt and rounded, can be outlined with the mirror. There is no well-defined macular region.

AMERICAN EGRET. *Herodias egretta*. A young adult was examined by the writer in the Bronx Park. The dominant color of the fundus in this species is a clear, bright, steel-gray.

The *pecten*, an oblong with rounded ends, covers most of the optic disc, whose white border can be seen only on the outer side. Striæ, composed of whitish opaque nerve fibres, radiate from the circumference at regular distances from each other.

AMERICAN BITTERN. *Botaurus lentiginosus*. (Figs. 128 and 91.) This fundus when seen by the naked eye and in prepared specimens, shows two *macular regions with their foveæ*. The *fovea nasalis* — a large dot surrounded by a nebular ring — just above and slightly to the nasal side of the superior extremity of the pecten. Temple-wards and almost at the periphery of the visible background is the *fovea temporalis* — a less distinct area, also depicted as a central spot surrounded by a ring of pigment grains. Allowing for the concavity of the eyeball the two maculæ seem separated (in the figure) by about two-thirds the length of the optic disc.

The coralliform, fenestrated structure of the *pecten* is made up of 28 narrow convolutions that are separated at their upper free margins so as to allow, here and there, a good view of the pigment-dotted surface of the opticus. There are three (unequally) short and eleven (equally) long double coils joined above by a narrow but uniform crest.

EUROPEAN BITTERN. *Botaurus stellaris*. The left fundus oculi of this species is depicted in Plate XXI, page 141 of this work.

The eyeground, mostly mouse-colored shading to yellow, is sprinkled with small, dull-white dots.

Almost immediately above the upper end of the optic nerve entrance and towards the nasal side of the disc is the *macular area*. The fundal dots at this point are much duller in tone and incline towards a dull, buff color. The region of the macula, enclosed by two circles, one within the other, is also characterized by the presence of very short, bright, bluish-green lines radiating from the center of the fovea. These striations are very brilliant and are easily seen by the aid of the ophthalmoscope.

The *optic disc* is ovoid, blunt at its upper extremity, and appears as if its longer margins describe a series of small curves corresponding to the folds of the pecten. The disc on either side of the root of the pecten is dull-brown; near by are small, orange-red choroidal capillaries. The papillary margins are quite white and, in contrast with the shadow cast upon the neighboring field by the dark pecten, the disc stands out in sharp contour. Extending a short distance over the fundi and about the optic disc are a few opaque nerve fibres. The pecten, convoluted, with serrated margins, and of the usual chocolate-brown color, extends below the lower end of the optic disc, and is plainly visible. It does not project far into the cavity of the vitreous.

BOAT-BILLED NIGHT HERON. *Cancroma cochlearia*. The eyeground of this Central American species is represented by Plate XXII, page 141, and depicts the left eye by the erect image. The prevailing coloration of the background is dull-red, covered with orange-red dots. These punctate deposits are intermixed on the upper half of the fundus with smaller and brighter dots of a grayer tone. On the lower half and on each side of the optic nerve are a few orange-red choroidal capillary vessels, that run in a vertical direction, parallel to the long axis of the disc.

The *macula* is situated towards the nasal side of the nerve head. This sensitive area is rather brighter in color than the surrounding field, and several white dots are included in it. These small dots, however, are noticeable only when the light of the mirror is reflected on the region in certain directions. Rather

a bright, irregular and linear reflex surrounds the macular region, which is very sensitive to light.

There is a long, narrow *papilla* with rounded extremities. It appears as if it were composed of short, white fibres, surrounding an orange-red center covered with minute, dark-brown pigment grains that form a network over the whole red area. Extending from each side of the disc across the retina are a few dull-gray, opaque nerve fibres.

The *pecten* can be traced the whole length of the disc; it is dark brown in color and grooved spirally like a corkscrew. It does not appear to come far forward towards the lens, and its union with the nervehead can readily be traced. The *pecten* and its immediate relations remind one of the fundus oculi of the Bitterns.

GLOSSY IBIS. *Plegadis falcinellus*. As will be seen on examining Plate XXIII, page 143, representing the left fundus oculi of this species, the *general coloration* is blue-gray, the eyeground being covered with a nebula of minute, pale-gray dots, giving it a brilliant gray tone when lighted up by the rays from the ophthalmoscopic mirror.

Towards the lower part of the fundus and on both sides of the optic disc, but parallel with it, are many orange-red choroidal capillaries; they are especially numerous below the optic nerve and suffuse the peripheral background with an orange-pink glow.

Only one sensitive area is seen. This *macular region* is located above the disc on the nasal side of the nerve. In the center of the area is a small, white, round dot, surrounded by a brilliant blue-green reflex, like the sheen on floss silk. It is probably due to the play of light on the fine fibres radiating from the center of the fovea.

The *optic disc* looks as if it were a mass of coarse white fibres; it is similar in shape to the *papilla* of the Spoonbill, but it can be traced only for about half its length, the lower part being obscured by the massive club-shaped *pecten*. The disc is bordered with black pigment which gives the appearance of a shadow cast on the eyeground. This organ is of the usual chocolate-

brown color and projects well forward towards the lens.

A large number of semi-translucent nerve fibers radiate from the margins of the optic nerve on all sides; they extend across the choroidal vessels, and finally vanish altogether in the fundal periphery.

AMERICAN JABIRU. *Mycteria americana*.

The fundus of the left eye is depicted in Plate XXIV, page 143 by the direct method. The *general coloration* is a slate-gray, the whole eyeground being quite uniformly sprinkled with small but variously sized, white dots. In the upper and nasal quadrant of the picture is the small, single *macula*, an area darker than the surrounding parts, whose exact centre shows a round white dot — the *fovea*. In the lower two-thirds of the field are seen numerous, plainly marked choroidal vessels that extend the whole length of the *pecten*, converging somewhat towards the posterior aspect of its base. About two-thirds of the long and rather broad *nerve-head* is plainly visible, except the central portion, which is partly obscured by the *pecten*. This large, black-brown organ, divided into 15 large and several much smaller double folds, terminates above as a thin, dark rod. The disc is fringed by black pigment grains, and from its lateral margins project a number of short, faint, whitish lines.

SPOONBILL. *Platalea leucorodia*. The colored fundus view (see Plate XXV, page 145) is of the erect image, left eye. In general the color of the *eyeground* is decidedly gray, becoming brownish towards the periphery. It will be noted that the entire fundus is thickly sprinkled with minute, irregularly shaped, gray-white dots, that appear more distinct about the macular region.

At the *fovea*, where they are brilliant white, they are still more closely packed. With the ophthalmoscope the foveal region appears to be sunken below its surroundings, and to be enclosed in a pale, greenish (reflex) ring that is of oval shape with its long axis horizontal. Judging from the effect on the bird when the direct light from the mirror is thrown upon it, this area is extremely sensitive to light.

The optic nerve-entrance is a long, narrow oval, and presents a brilliant white appearance. Near its upper end are several choroidal capillaries of a pale, golden-yellow color. Parallel to the long axis of the nerve-head is another elongated mass of white fibres* (almost like a second optic disc) having its center stippled with fine pigment dots, and extending across the eyeground. Radiating from the circumference of the papilla one sees a number of faint, translucent fibres, crossing the small white area on the nasal side of the nerve.

The *pecten* does not project very far forward into the vitreous; it is dark gray-brown and appears to be completely covered with a number of warty protuberances. It appears to be attached to the whole length of the centre of the disc, that is stippled with fine, red dots.

Anseriformes

BLACK-BELLIED TREE DUCK. *Dendrocygna autumnalis*. The fundus appearances, as revealed by the ophthalmoscope in six eyes of three individuals, are depicted as Plate XXVI, page 145. Five normal eyegrounds were identical; the sixth exhibited a congenital defect of the nerve-head which entirely changed the fundal picture.

The *fundus oculi* of the Tree Duck is colored a light fawn, besprinkled with minute, white dots, that glisten when a strong light from the mirror is thrown upon them. On each side of the papilla is seen a number of choroidal capillaries, bright orange in color and rather straight.

The *optic disc* is also orange-red along its major axis, this central zone being stippled all over with a network of fine black dots. The circumference of the disc is fringed with white fibres.

The dark-brown *pecten* arises, as usual, from the whole length of the disc. Viewed from above it seems very thin and twisted,

* Whether this is a normal condition or an anomaly of development cannot be definitely stated without an examination of additional specimens, but it was present in both eyes of the individual under consideration.

like a corkscrew. A few opaque nerve fibres extend for a short distance and at right angles to the disc on either side. The upper part of the fundus is almost obscured by numerous minute, brilliant, white dots. Although Head noticed that when he focused the bright light of the mirror on the upper quadrants of the fundus the Ducks used their *membrana nictitans* more frequently than usual he could not discover any well-defined sensitive area.

BLUE-WINGED TEAL. *Querquedula discors*. The general appearance of this bird's eyeground closely approaches that of the Mallard. The long, ovoid papilla is disposed with its major axis at right angles to the upper mandible.

MANDARIN DUCK. *Aix galericulata*. In examining the eyeground of this species the writer found that the light of the ophthalmoscopic mirror, when projected on the eyes directly from the front, illuminates, roughly speaking, about one-sixth of each field.

The prevailing color of the background is light, gray-brown, streaked with faintly marked choroidal capillaries, that are, however, confined to the nasal side of the disc.

The direct method shows a vertically placed *optic entrance*, that appears to stretch almost over the whole fundus. The field on the outer aspect of the disc seems to be superficially roughened or granular. There are no radiating opaque nerve-fibres or concentric reflex rings visible with the mirror.

The *pecten* is comparatively small, does not entirely cover the disc and presents from above downward a reticulated appearance.

MALLARD DUCK. *Anas boschas*. The general *coloration of the fundus* of this bird is gray-red. The *optic nerve entrance* is much longer than in most species, extending in a perpendicular fashion across the background; it is in no place obscured or entirely hid by the *pecten*. The papilla appears to be attached for three-fourths of its course to the latter, which arises in partially translucent, veil-like folds and extends to the posterior surface of the lens. No concentric

circles of opaque nerve fibres are visible. The whole background, including the disc, seems to be dotted with many punctate pigment grains.

CANADA GOOSE. *Branta canadensis*. The individuals of this species examined by the writer had been domesticated in the Bronx Park for several years but under conditions approaching their usual habitat.

The appearances of the *fundus oculi* were practically identical in all the specimens examined, and are similar to those of the Mallard. The concentric arrangement of the optic fibres in *Anas* is lacking in the Brant, while the latter has the larger pecten.

Although the *pecten* is rather large, the outlines of the vertically oval, yellowish-white papilla are visible throughout.

BLUE (SNOW) GOOSE. *Chen caerulescens*. Plate XXVII, page 147, reproduces the fundus appearances of two individuals examined by Mr. Head and of another seen by the writer. The backgrounds were the same in all. The predominant *fundal color* is a distinct fawn, sprinkled with small, round, orange-pink dots of irregular shape and size. Running vertically past and parallel with the optic papilla, over the lower half of the fundus, are numerous, straight, orange-red, choroidal capillaries.

The *fovea* is probably indicated by a small, glistening white dot above the end of the disc on the nasal side. This small, punctate deposit nearly disappears when the light from the mirror is turned in certain directions. An inconstant, bright-green reflex is noticeable in this part of the eye, and there is a decided photophobia when the ophthalmoscopic light is flashed upon the region of the supposed macula. Moreover, by careful focusing the circumference of the foveal (?) dot shows a small brown rim, like the sides of a crater. However, the light from the mirror does not reveal any actual depression; the eyeground appears level throughout and is uniform both in color and texture.

[The *optic nerve-head* is boat-shaped, tinted orange along its central zone and shows a narrow rim of coarse opaque nerve fibres

that form a fringe about its circumference. This orange centre is sprinkled with numerous minute, dark-brown or black dots. A few gray opaque nerve fibres arise from the disc margins, and cross the fundus horizontally. The pecten, of corkscrew shape, runs the whole length of the disc and comes well into the vitreous.

LESSER SNOW GOOSE. *Chen hyperboreus*. (Figs. 93 and 131.) There is, judging from a naked-eye survey of this fundus, a grayish but well-defined, rather narrow, *retinal band*, devoid of pigment, that runs obliquely through the center of the field from one periphery to the other. It is more definitely outlined by pigment grains on its inferior than on its upper margin, especially where it traverses the nasal half of its course. About its middle point is the single *macular region* and *fovea*—a short but regular line of pigment in the center of an enlargement of the band.

The large, shoe-shaped *pecten* is composed of 24 heavy, compact convolutions that terminate in a cigar-shaped superior and a triangular inferior extremity. The conical crest of the upper free border is wide for three-fourths of its entire length. It terminates in a thin, corkscrew process before it reaches the tip of the upper convolution, which almost touches the retinal band, with which the (projected) major axis of the nerve-head describes a right angle. The convolutions decrease *pari passu* in size from behind forward, all the coils inclining towards the lower end of the disc.

Phoenicopteriformes

COMMON OLD-WORLD FLAMINGO. *Phoenicopterus roseus*. (Figs. 94 and 115; macroscopic view.) This ocular *background* shows a small but compact pecten, whose 18 convolutions are (apparently) drawn towards the center of the organ above by a deep, cigar-shaped crest, so that the marsupium resembles, when viewed laterally, a truncated cone.

Stretching obliquely across the fundus is a light-colored, *retinal band* of medium width, which ends abruptly just before it reaches

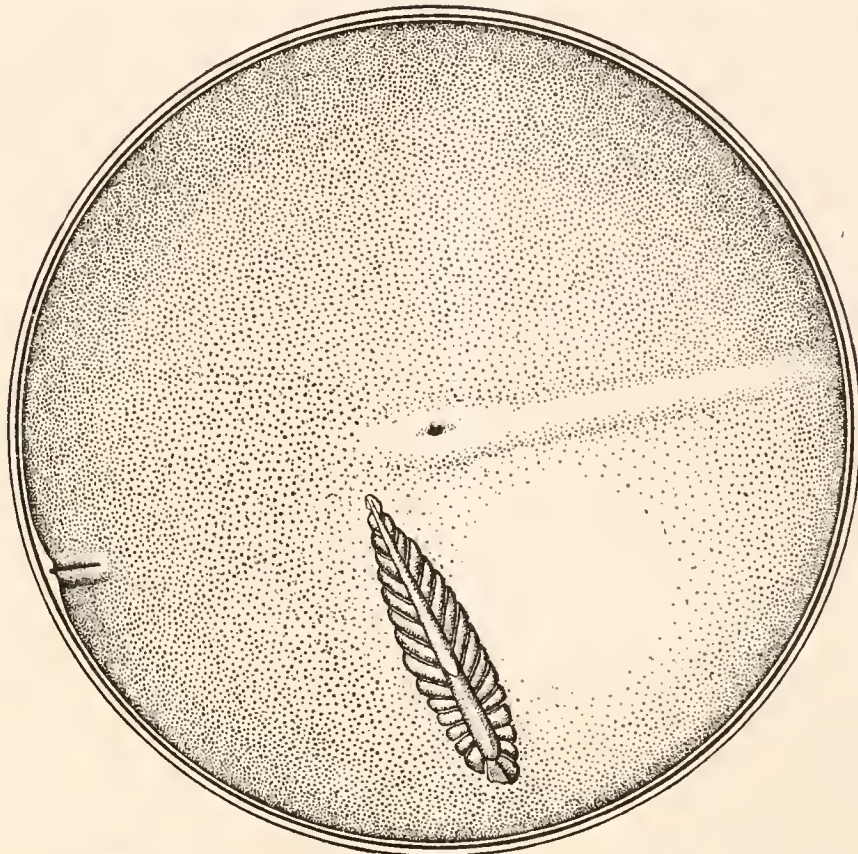

Fig. 130. Brandt Cormorant (*Phalacrocorax penicillatus*) $\times 9$.



Fig. 131, Lesser Snow Goose (*Chen hyperborea*) $\times 9$.

Macroscopic Appearances of the Fundus Oculi in the Preserved Eyes of Birds.

the temporal border of the field. Two lines of pigment dots—the one at the nasal end more plainly marked and each as long as the disc—divide the terminals of the band into two narrow spaces. The lower margin of the band is drawn with numerous minute pigment grains that are sparsely supplied to the upper border except at its nasal end. A third line of pigment, deeper in color than the other two, and about as long as the papilla is wide, indicates the middle point of the band somewhat nearer its temporal end. At this point the band becomes slightly broader, especially below. In the centre of this shortest line the pigmentation is somewhat pronounced, but an outline of the ordinary *slit-like fovea* within a retinal band is not here well developed.

An extension of the long diameter of the papilla to meet the lower border of the retinal band, makes with it an infulapapillary angle of 65° .

Pelecaniformes

CORMORANT. *Phalacrocorax carbo*. The fundus view shown in Plate XXVIII, page 147, of this work, represents the ophthalmoscopic examination of eight eyes of four individuals. Two were tame birds, the others were freshly caught, but their eyegrounds were identical. The drawing presents the appearances in the left eye by the direct image.

The fundus oculi is mostly of a slate-gray color, uniformly sprinkled with numerous, minute white dots, closely packed together. Running chiefly parallel with the long axis of the optic disc are several rather straight, orange-red choroidal capillaries, that extend the whole length of the papilla and beyond its inferior extremity.

The *macular area* is seen a little above the upper end of the optic disc and on the nasal side of the nerve. The fovea appears as a reflex image of a few short, bright, white lines surrounded by a narrow and similar ring.

The *optic disc* gives the impression that it is composed of a mass of very white, cotton-like fibres, disposed as a fringe all about the papillary margin. The central area of the disc, especially on each side of the root of the pecten is orange-red,

stippled with minute, brown pigment grains. Perpendicular to the papillary margins are a few short, fine opaque nerve fibres, that run towards and are finally lost in the peripheral eyeground.

The pecten is rather long and of the usual chocolate-brown tint; it is much narrower than usual on the upper half of the disc, and comes well forward into the vitreous humor, extending behind the margin of the pupil.

FALLARONE CORMORANT. *Phalacrocorax dilophus albociliatus*. An adult individual of this species (while dying) was examined by the writer in an open boat in San Diego Bay, California. An ophthalmoscopic view was obtained under these difficulties, and is consequently incomplete. However, the writer saw through dilated pupils that the fundus was gray-black and uniformly dotted throughout. The pecten was easily seen, but not well enough to count or accurately describe the arrangement of its plications.

BRANDT CORMORANT. *Phalacrocorax penicillatus*. (Figs. 95 and 130.) This *fundus oculi*, when viewed with the naked eye, in prepared specimens, shows a broad, gray band depicted in the black and white drawing as extending in a rather oblique direction from the nasal periphery of the field to a point immediately above the superior end of the papilla. Here, just before it terminates, the band widens and develops into an oval area with a large central, black dot, crowned by minute and scattered pigment grains. This *macular area* is located about the width of the minor axis of the optic disc from the upper extremity of the latter.

[In the temporal margin of the black-and-white drawing is a slit-like mark; this is *not* a second fovea but an artefact fold in the retina.]

The *pecten* presents a broad, and rather long, pointed oval, with its blunt extremity below. It is composed of 32 convolutions whose free margins are united above in a keel, and whose wide and thicker posterior fourth covers nine equally long double coils. It then slopes to the superior pointed extremity of the disc, having joined, above, the remaining nine unequally short coils.

GANNET. *Sula bassana*. The picture of the fundus, as shown in Plate XXIX, page 149, is the result of ophthalmoscopic examinations of three healthy, adult specimens. It depicts the left eye; erect image. The general color of the eyeground is dull-yellow with a gray tint, everywhere covered with light gray dots, that are most numerous on the upper half of the fundus. Below and on each side of the optic nerve are several orange-red choroidal capillaries. These vessels are fairly straight and run parallel with the long axis of the disc.

The nerve-entrance and pecten are situated rather high up in the field; consequently it is easy to examine the details of the peripapillary background.

Above the upper end of the optic disc and a little towards the nasal side, is a small circular *macular area*, red in tone but surrounded by a larger circle, like a gray shadow. The margins of the latter gradually fade into the background.

The visible margins of the *papilla*, apparently composed of coarse, white, opaque fibres, are not, as in many species, covered by the pecten. The central part, near the root of the pecten, is orange-red in color.

The pecten itself is evidently attached to the disc for nearly its entire length, and does not appear to come forward towards the lens.

REDBACK PELICAN. *Pelecanus rufescens*. The individual (male) examined by the writer was five years old and had been domesticated in the Bronx Park for at least three years. His refraction, estimated by the skiascope, was about +1.D. The general coloration of the ocular background is a well-diffused, light reddish-brown; in some parts of the field verging on gray. The *pecten* is very large—larger at its free than at its papillary extremity—and twelve distinct corrugations in it are visible and can be counted by the aid of the ophthalmoscope.

Although the canoe-shaped *optic papilla* is almost entirely obscured by the mass of the pecten yet it is uncovered towards its temporal end, where it presents a very white, pointed extremity; elsewhere it ap-

pears reddish-brown. Radiating fibres surround the disc, like a halo.

AUSTRALIAN PELICAN. *Pelecanus conspicillatus*. The fundus appearances of this bird, as demonstrated by the ophthalmoscope, are portrayed in Plate XXX, page 149.

The predominant color of the eyeground is a dull but deep gray, sprinkled generally with irregular dots, most numerous in the upper part of the fundus. The lower quadrants of the field are covered with a dull, orange-red, choroidal capillary system, disposed in a vertical direction. The *disc* is a wide, pointed oval, exhibiting a number of bright-red orange ridges that are uniformly stippled with black pigment dots. The disc margins stand out as a clear white.

The *pecten*, broad and massive, seems to fill the pupillary area. It projects far into the vitreous, reaching, indeed, the posterior surface of the lens. In spite of its large size and intraocular disposition both the free and the attached ends of the organ can be outlined by the ophthalmoscope. Passing in a radial direction from its circumference is a number of opaque nerve fibres.

The single *macular area* is to be found on the inner side of the fundus. It is surrounded by a narrow, sharply defined, reflex ring of greenish color.

CALIFORNIA BROWN PELICAN. *Pelecanus californicus*. A young adult was examined on the Coronado Islands, Mexico, by the writer. The pupils measured about 5 mm. and were not affected by light, as the bird had just died. The fundus was well seen. There was a distinctly whitish background, almost uniformly covered with minute gray-black dots. The *pecten* was large, and of the corkscrew type, almost covering the whitish-yellow optic disc whose margins were easily made out. This bird seems, from the position of his eyes and their frontal disposition, to have binocular vision.

Serpentariiformes

SECRETARY BIRD. *Gypogeranus (vel Serpentarius) serpentarius*. The ocular background of this species presents a most unusual appearance. The colored drawing (Plate

XXXI, page 151), depicts the right fundus by the erect image. The general *color of the eyeground* is dull gray, pitted all over with mixed light and dark brown pigment grains or dots, the darker being about double the size of the lighter granules. Interspersed with these dots is a dense mass of minute, bright points that cover the whole fundus, but they can be observed only when the reflected light of the mirror is focused upon them. These various deposits give the background the appearance of a rough surface. There are no visible choroidal bloodvessels, but a thin layer of translucent nerve fibers surrounds the papilla for a short distance, particularly along the long axis of the nerve-head.

A little above the upper end of the optic disc and towards the nasal side is the *fovea centralis*, a round white dot enclosed by a narrow ring of bright green. This area is extremely sensitive to the reflected light of the mirror. On the temporal side of the disc, and above the end of it, is also a long, narrow, sensitive area. This part is enclosed by a shimmering reflex of green light. The animal, otherwise quiet, becomes very fidgety when this area of the fundus is examined, and gasps for breath as if it was being suffocated.

[The *optic disc* is long and rather narrow, both ends being rounded off. It is quite white and deeply pigmented at its outer and upper borders.

The *pecten* is of a lighter brown than usual, is plainly serrated on either side and appears as a narrow band that extends the whole length of the disc. Just before its junction with the optic nerve-head it is stippled with bright, orange-red grains. The central part of the *pecten* does not project far forward into the vitreous; it appears to be quite narrow, while the whole length of its upper edge or crest seems rather wavy. On the whole, the fundus appearances present a picture unlike those of any other species examined by Head or the writer.

Accipitriformes

LÄMMERGEIER. Bearded Vulture. *Gypaëtus barbatus*. Plate XXXII, page 151, represents an ophthalmoscopic view of the right ocular fundus (erect image) of this bird.

The *eyeground* is slate gray, not stippled, as in so many avian fundi, but presenting everywhere a granular appearance. The lower half of the fundus is covered with dull, orange-red choroidal bloodvessels that run in a vertical direction, parallel to the sides of the optic disc.

Above the papilla (about two disc breadths from it on the nasal side) is a small, round, dark-brown pigmented pit, surrounded by two distinctly marked, brilliant reflex rings, each having a greenish tint. On the nasal side of the nerve-head, but quite near the disc, and much less distinctly outlined than the depression just described, is the *second macular region* with its fovea. Looking at it through the mirror it seems to have a soft, indistinct but dark center.

All the fundal sectors are clearly seen.

The *optic entrance* is pure white, with an orange-red central area from which arises the *pecten*. This body is very narrow and tapers on its upper aspect for about one-fifth of its length. It then becomes much broader and almost covers the outer zone of the disk. As it comes forward towards the lens its contour resembles that of the Bald Eagle.

This fundus is singularly free from opaque nerve fibres.

BALD EAGLE. *Haliaëtus leucocephalus*. The fundus picture seen in Plate XXXIII, page 153, is the result of an examination of a number of individuals. The writer, for example, had an ophthalmoscopic view of the eyeground of five Bald Eagles in the Bronx Park collection.

The prevailing color of this bird's fundus is dark reddish-brown, the lower half changing to a dull orange-red. The whole eyeground is covered with choroidal capillaries, and dotted over with brown pigment grains, giving it a rough, granular appearance. A gray sheen pervades the upper part of the fundus.

On the temporal side and some distance from the upper end of the optic nerve is a brilliant, white, round dot surrounded by a small, light-green reflex ring, which is itself enclosed in a very brilliant, narrow green ring—the *muscular region*. On the nasal side of the disc, and on a level with this

macula is another area, of a gray color, surrounded by a fan-shaped, luminous reflex.

The *optic nerve-entrance* is distinctly white, and along its center is strewn a large number of minute pigment dots. The outer margin of the disc is bordered with black pigment, as if a shadow were cast upon it by the pecten. In this regard and in some others this fundus resembles the eyeground of the Sea Eagle.

WHITE-BELLIED SEA EAGLE. *Haliaëtus leucogaster*. The ocular fundi of three individuals of this species were found to be identical and furnish the ophthalmoscopic appearances shown in Plate XXXIV, page 153.

The *coloration of the eyeground* is mostly dull-brown, the lower quadrants of the field being covered with dull, orange-red capillaries evidently choroidal.

The *optic disc* is a long white oval, whose center is tinted with orange and covered with tiny pigment dots. The papillary margins are white bordered with black pigment.

The upper half of the fundus is covered by a mass of dull gray dots. There is a well defined reflex near both maculæ, each similar in position to that seen in the Kestrel. These areas are evidently very sensitive to light, as the bird becomes very fidgety and irritable when the reflected rays from the mirror are thrown directly on one or other fovea.

The *pecten* is very large and comes well forward towards the posterior surface of the lens. Both extremities of the organ are clearly visible through the ophthalmoscope. There are very opaque nerve fibers to be seen in any part of the eyeground.

AMERICAN OSPREY, or Fish Hawk. *Pandion haliaëtus carolinensis*. When light is thrown directly from the front and at a distance of one foot, on the pupils of this bird of remarkable visual powers the red reflex is seen to occupy fully three-fourths of each pupillary area.

By the aid of the ophthalmoscope the writer found the *general fundal coloration* to be bluish-gray with a suggestion of brown. These tints are uniformly distributed throughout the ocular background, and there is very little of the striation seen in *Buteo* and other genera.

The *pecten* almost entirely obscures the view through the pupil of the optic disc; it is a compact, intensely black body, showing about ten convolutions.

Mainly because of the undilated pupil and large pecten no definite fovea was visible.

EUROPEAN KESTREL. *Tinnunculus alaudarius*. Plate XXXV, page 155, is a faithful reproduction of the ophthalmoscopic appearances in this sharp-sighted species, depicting the right eye by the direct method.

The *ground-color* of the fundus is a light brown, or brownish-gray. The lower quadrants are streaked with orange-red, choroidal capillaries that run in a more or less vertical direction, and become more distinct and brighter red as they approach the periphery of the field. The *optic disc* is a long, white oval, showing its margins well beyond the pigmented and fringed pecten. The central area of the papilla appears to be hollowed out like a canoe and the pecten does not overlap it at any point of its circumference, as is so frequently the case in avian fundi.

The disc extends as far downwards towards the fundal periphery as the observer's eye can reach. At its lower extremity several small choroidal vessels can be seen.

The *pecten* has a rounded but pyramidal form, sloping towards the centre of the disc at both ends. It is of a dull-brown color, and corrugated like a photographic camera. At the junction of pecten and papilla are scattered numerous brown dots, so disposed as to give the former the appearance of a web. The upper part of the eyeground is quite devoid of choroidal blood-vessels, but is covered with minute white dots. The fundus is much clearer of the retinal shimmer or reflex noticed in most birds.

The two macular regions are very distinctly visible. The nasal macula is situated just above the upper end of the disc and about half a disc-length on the inner or beak side of the eyeground. It is a dark-brown spot with a pale area all around it. Outside of this region and enclosing it are two distinct, pale-green, filiform, reflex rings, the interior rings being quite free from the white dots. On the outer aspect of the eyeground, about

one-third the length of the disc above and two-thirds to its outer side, is seen the second or temporal macular region. At its center is a light, gray spot surrounded by a dark brown area. Both these areas are in their turn encircled by a small, pale-green, reflex ring about one-fourth the diameter of the corresponding circle about the superior macula. Slender, opaque nerve fibers run out at right angles to the disc on both sides.

RED-TAILED HAWK. *Buteo borealis*. The optic-nerve entrance in the individuals examined by the writer is almost entirely covered by the pecten, except at its superior end, which can be outlined and examined by the mirror. It lies (obliquely) at an angle of about 70 degrees with the upper mandible, and can be seen through the more or less translucent pecten. The background generally has a striated appearance with the choroidal vessels showing through.

LITTLE BUSTARD. *Tetrax tetrax*. Plate XXXVI, page 155, reproduces the left fundus oculi, direct image, of this species. The fundal coloration is mostly a warm gray, covered with small, dull orange-red dots. In the lower half of the field and on each side of the optic nerve entrance is a number of choroidal blood-vessels of a dull orange-red color, running parallel with the disc.

So far as seen, the *papilla* is a dead white; optic fibres form a fringe-like setting about it. The central zone of the disc is covered by a mass of minute, brown, pigment deposits of irregular shape. Opaque nerve fibres extend at right angles to the disc on either side.

A little to the temporal side, about one disc-length from the upper end of the optic nerve, is a small, brown spot like a tiny hole. This *macular area* is surrounded by a brilliant, green reflex ring.

The *pecten*, of a dark chocolate-brown color and shaped like a corkscrew, comes well forward towards the inferior border of the lens.

The fundus of the Great Bustard — *Otis tarda* — closely resembles that of *O. tetrax*.

Strigiformes

TAWNY OWL. *Syrnium aluco*. (Figs. 132 and 96). The ocular background of this species shows, macroscopically, a solitary,

temporal, macular region and fovea. This single macular area is about a disc length and a half above and to the temporal side of the smaller or superior end of the pecten.

The irregular shape of the eyeball and fundus in the Owl must not, in this connection, be forgotten. The comparatively undersized *pecten* exhibits 14 convolutions (four large and of equal size, ten unequally smaller) that when viewed from above look like a small bunch of raisins. Between the folds may be seen the margins of the *optic nerve entrance*. The crest surmounting the upper free border is very thin, inconspicuous and undeveloped.

The *ophthalmoscopic view* of the normal fundus (the result of examination of numerous individuals) is shown in Plate XXXVII, page 157.

On the outer aspect of the papilla and about one disc-length from it, on a level with the upper margin of pecten, is a slight depression (*macula*) almost devoid of choroidal vessels. Its centre is a dark red color, the whole macular region closely resembling the same area in the (brunette) human eye. On the margins of this depression and surrounding it is a bright circular reflex. Head found this reflex to be so bright and dense in some individuals that it was difficult to see the other macular details, although, in most instances, by shifting slightly the reflected rays from the mirror the macular margins come out distinct and sharp. For some distance outside this foveal ring the eyeground is seen as if one were viewing it through a translucent, grayish mist or haze; and the fundus thus seen generally appears to be granular with a few, small choroidal capillaries showing here and there. Inside the ring, however, the details are strikingly clear, and the coloration bright red. Above the macula, on the outer side of the disc, is a quantity of dark pigment deposited between the choroidal vessels, by contrast making the latter stand out as of a bright orange color. The inner aspect of the fundus appears yellow; it exhibits numerous choroidal blood-vessels, whose yellow tint is distinctly brighter near the inferior segment of the disc.

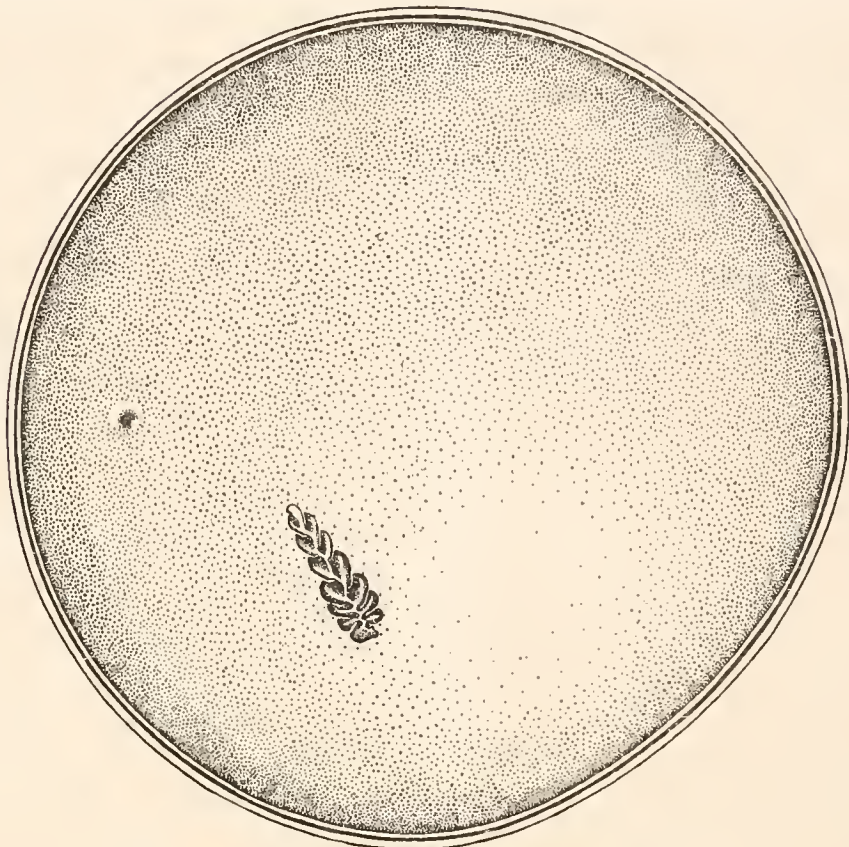

Fig. 132. Tawny Owl (*Syrnium aluco*) $\times 7$.



Fig. 133. Greater Sulphur-crested Cockatoo (*Cacatua galerita*) $\times 9$.

Macroscopic Appearances of the Fundus Oculi in the Preserved Eyes of Birds.

BURROWING OWL. *Spotyto cunicularia hypogaea*. The ocular *fundus* of this species is irregularly round, as in all the Owls, and in prepared specimens the details show distinctly.

The single, temporal, oval *macular region* lies above and about a disc length and a half from the upper end of the papilla. In the center of the macula is the fovea—a dark pigmented spot with fine granules arranged cap-like above it. Outside this, again, is the ovoid circumference of this region, incompletely edged with fine dots. These are more numerous distributed below the macula than above it. Connected with the macular region is a light colored and rather broad band that extends horizontally to the center of the visible background. It is unevenly divided into two strips by a parallel arrangement of minute pigment dots.

Seen from above the relatively small *pecten* closely resembles a disarticulated, acuminate leaf, the stem representing the spinous projection immediately above the lowest terminal convolution. The light double folds of the marsupium slope backwards and cover most of the optic entrance; they meet above in a uniform, very narrow, slightly undulating crest whose posterior end projects half the height of the unlying coil well into the vitreous cavity. An extension upwards of the long axis of the disc cuts the retinal band at the junction of the inner and second fourth, making an infulapapillary angle of, perhaps, 40°.

This interesting Owl is especially subject, like other Strigiformes, to pathological variations in the fundus picture due to confinement and domestication. Both Head and the writer examined a number of individuals that undoubtedly exhibited choroidal disease and other pathological changes. Rejecting these, the general color of the fundus of this species is found to be dull-orange, mottled and blotched in its upper half with orange-red. Choroidal vessels are plainly seen, covering all the lower part of the eyeground, just as in the Tawny Owls. The well defined macular area is seen within the outer half of the fundus, a little above the upper extremity of the optic disc.

It is distinguished from the surrounding choroïd by a collection of minute pigment granules or dots with a bright, white spot in their centre.

The *optic disc* is white and of oblong shape, slightly rounded at the ends. From its edges run a few, short nerve fibres that form a complete fringe about the visible papilla.

The *pecten* is decidedly larger in proportion to bodily measurements than one finds it in most of the larger Owls, especially larger than in the Tawny Owl. It extends well forward into the vitreous, and its lower half appears very massive and of a dark brown color. The pectinate convolutions are plainly seen and the anterior or upper half is more delicate in structure, being perforated where it joins the disc. Here it forms a dark network on the surface of the nerve-head where, also, a few red granules mingle with the chocolate-brown texture of the pecten.

SNOWY OWL. *Nyctea nyctea*. It is a popular belief, and one held in many public aviaries, that these owls are likely to become blind if much exposed to daylight. Consequently they are often caged in darkness or semi-darkness, although their habits are really diurnal, or at least they are as much Day birds as Night birds.

In any event the changes in habitat involved in their captive surroundings are, in the judgment of the writer, responsible for certain alterations found in their fundi and in those of other Bubonidae kept for more than a year or two in public gardens.

The normal, dominant *coloration of the fundus* is very light yellow-red, but decidedly less red than in *Syrnium aluco*. See Plate XXXVII, page 157, of this Atlas. In the first individual (two years in captivity) examined there were throughout the *left background* extensive choroidal changes, especially one cruciform, pigmented, partially atrophic area running across the field towards the nasal side. These long, striated alterations were also seen in the temporal part of the fundus.

The large, club-shaped *pecten* springs from a well defined whitish, ovoid disc. The margin of the *papilla* is occupied by numerous

small, dotted, pigmented deposits. The ocular media were entirely clear.

In the *right fundus* the pathological changes were the same except that towards the nasal side of the papilla there was a large, atrophic, pigmented area extending almost to the periphery of the fundus, entirely unlike the smaller and narrower lesion in the left eye. Altogether the morbid changes in the right eye are more numerous than in the left.

In a younger individual the coloration of the background, the papilla, the pecten and the macular region were precisely as in the first-mentioned bird. The pathological lesions, however, were entirely different. They appeared in each eye as four or five rather small, round, pigmented exudates, having a whitish atrophic (?) centre, much like the medium-sized deposits in the human eye when affected by a disseminated choroiditis.

EUROPEAN BARN OWL. *Strix flammea*. (Figs. 97 and 112; macroscopic view). This fundus shows the single sensitive regions (*macula* and *fovea*) on the temporal aspect of the field, slightly above and less than the long disc-diameter from the upper termination of the optic entrance. The fovea is represented by a large dot in the center of a number of minute granules, surrounded by an untinted area inclosed in a ring of still more numerous pigment grains.

The small *pecten* is made up of 14 short, stout convolutions (the largest ten of equal size) that only partially cover the nerve head, which has pigment granules scattered over its surface. The pectinate coils meet above and are joined by a straight, thin, cord-like crest. They all incline towards the posterior free border. The upper free margin is about half the length of the papilla.

The fundus oculi of the British species, painted from a recently captured specimen, is depicted on Plate XXXVIII, page 157. With Mr. Head, the writer examined many of the Strigidæ confined at the time (July, 1912), in the gardens of the (British) Zoological Society. Those that had been caged two years or more were plainly affected with choroidal changes, mostly of the disseminated choroiditic type, the choroidal atrophy and

pigment deposits varying in amount but nearly always more marked the longer the birds had been imprisoned.

The *general tone of the eyeground* in *Strix flammea* is dull gray with bright, clearly outlined, orange-red choroidal vessels distributed all over the fundus, except at the macular region. At this area the tint is much grayer, being, in addition, stippled with small, irregular blotches of orange-red and gray dots.

The *macula* is also suffused with a gray reflex. It is situated above the upper end of the optic disc and nearly in a line with the long axis of that organ.

The *papilla* is long and narrow, with pointed ends, and is apparently made up of coarse, white fibre-bundles the central portion of which is covered with minute, brown, pigment grains, that have a distinctly reticulated appearance. These white fibres border the nerve-head all around.

The dark-brown, convoluted pecten of the Barn Owl is much larger than that of the Tawny Owl. It is also placed farther forward towards the lens than the pecten of the latter bird. Extending from both sides of the disc are a few, dull-gray fibres that stretch a short distance across the fundus and then disappear.

Two specimens of *Strix pratincola* and two of *Strix perlata* revealed ophthalmoscopic appearances quite similar to those seen in *Strix flammea*, except that the fundi of the two first-named species are generally of a deeper gray. All these (four) individuals were suffering from choroidal changes.

Psittaciformes

GREAT SULPHUR-CRESTED COCKATOO. *Cacatua galerita*. (Figs. 98 and 133; macroscopic views.) In this ocular background there is no visible *fovea* or macular area.

The medium-sized *pecten* exhibits rather broad, rounded convolutions, some 24 in all, that are joined above by a heavy process or crest of irregular outline. The latter extends one-half the length of the free upper border, joining together nine equal-size double folds. From this keel-like body the mass of the pecten slopes off to the front, exposing portions

of the whitish nerve head, which is dotted with very small pigment granules.

The *ophthalmoscopic appearances* of the left eye of *Cacatua galerita*, erect image, are portrayed in Plate XLI, page 161. The *background* is of a fairly uniform, light grayish-blue color, sprinkled with minute white dots that are interspersed with many less numerous but somewhat larger dark gray deposits. The *macular area*, at the upper-inner quadrant, is an irregularly round, light brownish area whose diameter is half the disc length. It is not, as in many Birds, surrounded and defined by an outer ring; the periphery fades into the surrounding gray of the fundus. The upper sixth of the long, pointed *papilla* is distinctly visible where it is not covered by the indented *pecten*, whose twelve double folds have a corkscrew termination above. Portions of the disc borders can be seen from above through the plications, except at its posterior terminal where the dark-brown mass entirely covers it. Faint, whitish lines of opaque nerve fibres extend from the margins of the upper half of the disc a short distance across the centre of the eyeground.

ORANGE-WINGED PARROT. *Chrysotis amazona*. Plate XXXIX, page 159, represents the ophthalmoscopic appearances in the right eye of this species. The dominant *color of the eyeground* is deep gray tinted with buff. The lower sectors and the peripheral zone of the fundus are suffused with pink, the background generally being punctuated with minute, dull-yellow dots.

The *macular area* is situated towards the nasal side of the disc, a little above the end of the *pecten*. It is slightly depressed and enclosed by a rather bright but pale-green reflex-ring. Extending from the circumference of this circle, slightly above as well as below, are a few translucent fibres, pale green in tone; and at its centre is a dark-gray dot or depression, with a small, faint halo extending from its upper edge.

The *optic nerve-head* looks as if it were composed of coarse, white, opaque fibres, which form a fringe all around the deeply-colored *pecten*. The *papilla* is long and boat-shaped, and its outlines can be traced

the whole length of the *pecten*. Many fine, gray, opaque nerve fibres extend from the margins of the *papilla*, cross the background of the eye and are eventually lost in the fundal tissues.

The dark-brown *pecten*, seen from above, has a spiral form, with a tag or tail-piece at the upper end. A lateral view shows it to be plicated, like a fan. It stands well forward towards the lens.

The light reflected into the eye from the ophthalmoscopic mirror does not appear to disturb specimens of the species at all, unless it is concentrated on the macular region.

WHITE-FRONTED CUBAN CONURE. (?) *Conurus ridgway*. The writer examined with the ophthalmoscope the fundi of an individual four years old that had been an inmate of Bronx Park for three months. Neither a one-fifth of one per cent solution of sulphate of atropia nor a homatrophine and cocaine mixture had any effect on the size or motility of the pupil.

The *eyeground* was generally *reddish-gray*; the *pecten* was large, convoluted and extended well into the vitreous cavity and approached the posterior lens surface. There was no well-defined macular region. The optic entrance was almost covered, and a view of it obscured, by the base of the *pecten*.

KAKAPO. OWL-PARROT. (New Zealand.) *Stringops habroptilus*. In July, 1914, the writer examined the single specimen then in the gardens of the Zoological Society at Regent's Park, London. The bird had, at that date, been in captivity two years, and seemed dazed when exposed either to bright natural or artificial light. The keeper reported that the bird is very quiet during the daytime but digs in the sand of his box at night. The lids have no cilia-like protection—only scattered plumules on the otherwise naked lids. He has large pupils and a dark brown iris.

The red-brown fundus is fairly easily seen with the ophthalmoscope without using any mydriatic. The frontal position of the eyes (found in all *Strigiformes* and to which order the writer believes this species rightfully belongs) is marked in this animal, and

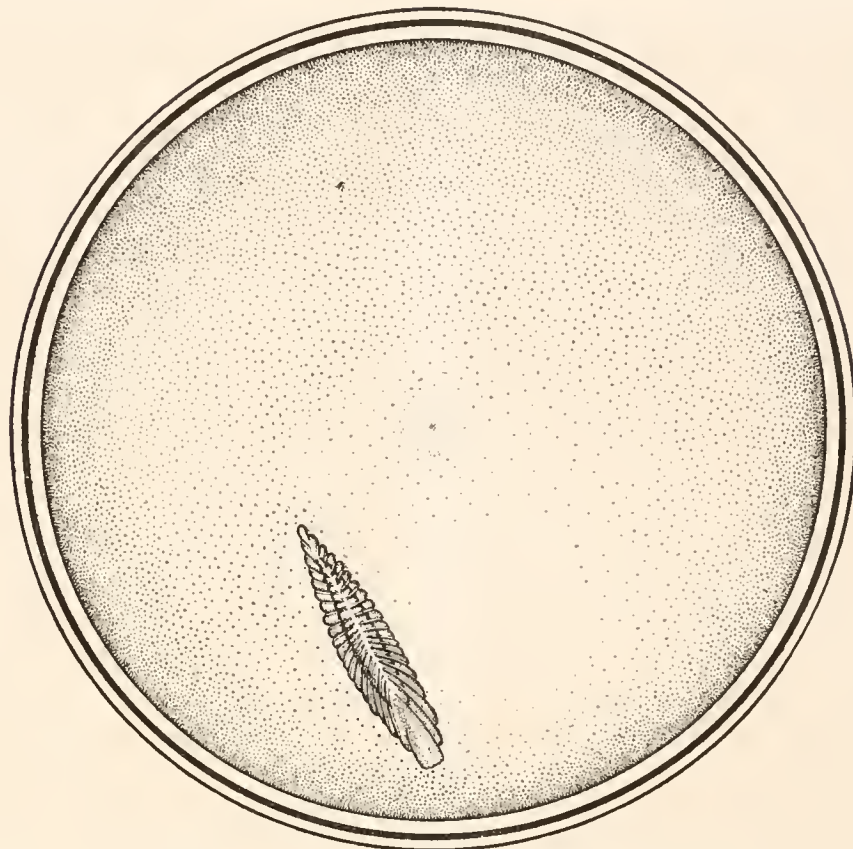


Fig. 134. Common Hoopoe (*Upupa epops*) $\times 18$.

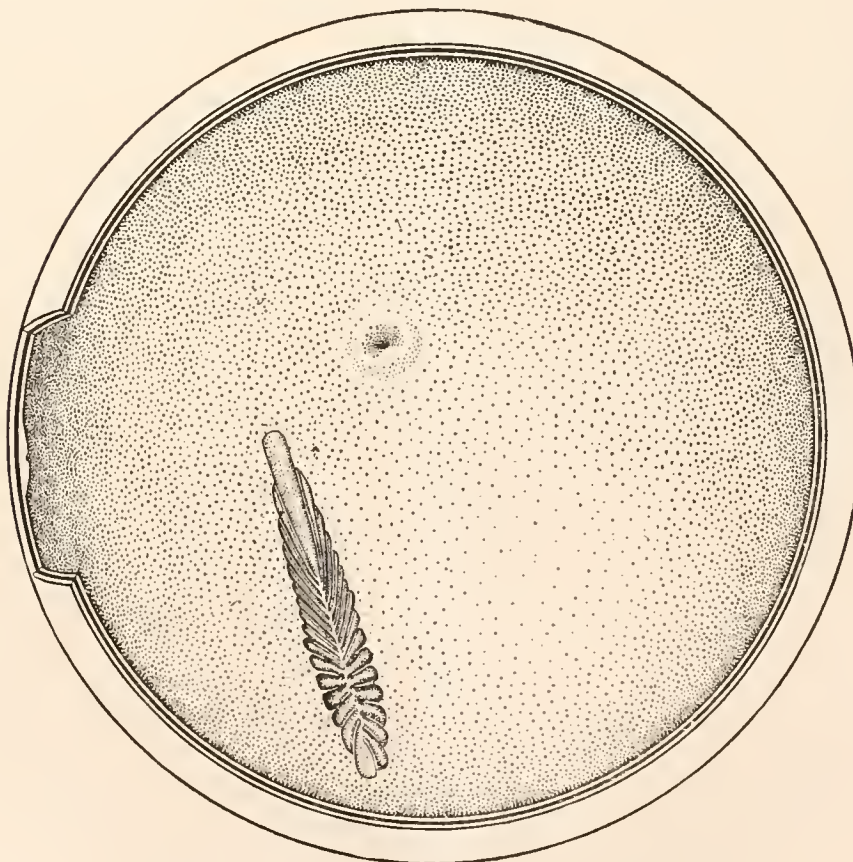


Fig. 135. Anna Hummingbird (*Calypte anna*) $\times 31$.

Macroscopic Appearances of the Fundus Oculi in the Preserved Eyes of Birds.

the bird evidently possesses binocular vision as he always looks straight ahead at objects that he wishes to see distinctly. Plate XL, page 159, furnishes an ophthalmoscopic view of the right eye, erect image. The *eye-ground* is orange-red stippled all over with lighter orange dots. The lower half of the fundus has a large number of minute, dark, reddish-gray depots of pigment intermingled with lighter dots; also, a great many choroidal blood vessels run in a vertical direction over the field of view on either side of the optic entrance. They become more numerous towards its lower periphery.

The *macula* is placed, as in Owls generally, on the temporal side of the optic papilla, about one disc-length from its upper end and half that distance to the temporal or outer aspect of the fundus. It is a bright, orange-red area surrounded by dark, red-gray pigment, like a shadow. There is no circular sheen around it, such as has been noted about other avian foveæ.

The *optic nerve-head* is white, and along its center appears a network of minute, brown pigment dots clustering around the sides of the pecten. A few white opaque nerve fibres extend a short distance on either side and about the upper end of the disc.

The *pecten*, of the usual black-brown color, extends the whole length of the disc. It is rather straight in its upper half but is more convoluted towards the lower part, where it is quite massive and resembles a corkscrew. This portion of the pecten comes markedly forward towards the lens so that it more nearly resembles the same organ in the Burrowing Owl than in the Parrot; as indeed the foregoing studies of the fundus oculi lead unmistakably to the conclusion that this bird belongs to the Owls rather than to the Parrots.

Coraciiformes

EUROPEAN KINGFISHER. *Alcedo ispida*. (Figs. 99 and 113; macroscopic view.) This remarkable background shows two extensive, well-defined, circular *macular regions*, both supplied with a large, deeply pigmented fovea. The nasal *macula* is large and

saucer-like. The *fovea nasalis* is surrounded by a nebula formed of microscopic dots that are, however, absent at the lower nasal third of its margin. About the same distance down and templewards from the superior end of the disc, as the deeper fovea is up and nasalwards, lies the secondary *area temporalis*. [In the sketch the wall of the globe is cut away to expose it.] This temporal macular region is smaller and not so well defined as the nasal fovea but it exhibits a distinct pigmented centre surrounded by a dotted ring.

The large and curious *pecten* exhibits 17 double folds, two at the superior terminal of the organ. These 34 convolutions are very thin (like strips of paper), and through the wide intervening spaces almost the whole surface of the *optic disc* can be seen and its outlines readily traced. The papillary surface is dotted exactly like the surrounding retina. The crest or free border of the pecten is quite narrow, and caps the pectinate mass in a wavy line. The naked-eye view from above gives a picture much like a fern frond.

LAUGHING KINGFISHER. *Dacelo gigas*. The ophthalmoscopic appearances of this species are pictured in Plate XLII, page 161.

The *fundus oculi* is in general of a light fawn-gray color mingled with irregularly shaped, white or gray-white dots, except in the neighborhood of the optic nerve where it is orange-red, like the glow cast on the sky by the setting sun.

The *optic nerve entrance* is long and narrow; it is white except along its central area, which is orange-red striped with brown pigment dots. A large number of opaque nerve fibres run out on each side of the optic nerve and at right angles to it.

The pecten is very long and narrow and has the appearance of a brown centipede.

The *macula* is very conspicuous. About half a disc-length from the upper end of the nerve, towards the nasal side, is a small, round, dark-brown hole, surrounded by a very narrow, bright green ring. This circle encloses a smaller area that is of a darker gray and devoid of the dots seen at other

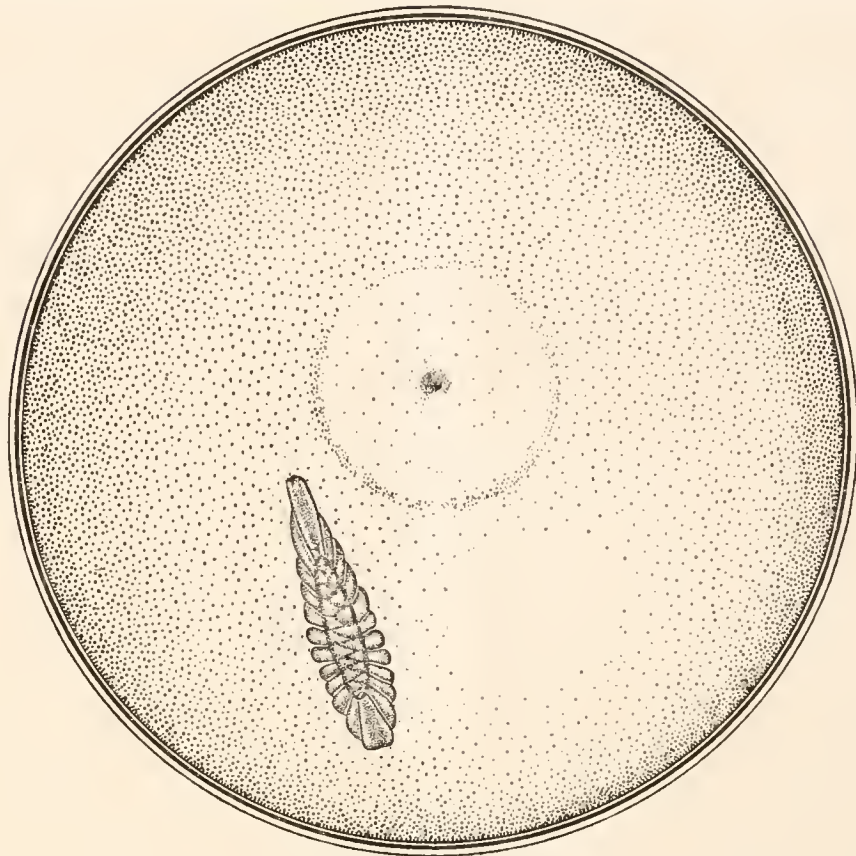

Fig. 136. Yellow-billed Cuckoo (*Coccyzus americanus*) $\times 13$.

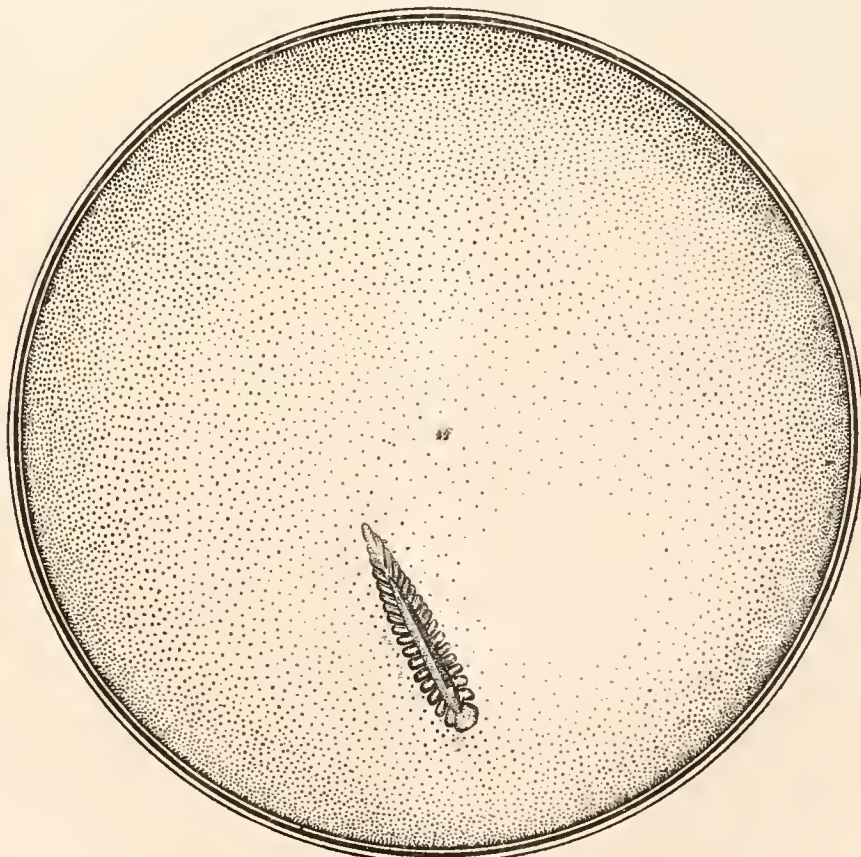

Fig. 137. Red-shafted Flicker (*Colaptes mexicanus*) $\times 12$.

Macroscopic Appearances of the Fundus Oculi in the Preserved Eyes of Birds.

parts of the eyeground. The *fovea nasalis* always appears directly opposite the pupil; there is no *fovea temporalis* visible to the ophthalmoscope.

COMMON HOOPOE. *Upupa epops*. (Figs. 134 and 100; macroscopic view.) This medium-tinted *fundus* exhibits a single *macular region*,—a round figure whose diameter is equal to the extreme width of the papilla. It is depicted by a dotted line of pigment grains that are more numerous below. The *fovea* is shallow and not well-defined.

The relatively large *pecten* has numerous (about 40) convolutions; it forms a compact mass that almost obscures the papilla, particularly when the disc is viewed from above. It is covered by an ovoid cap that extends from the ridge-like (upper) free border about one-fourth of the distance to the pectinate base, whose full length is more than four times its extreme width.

BLACK HORNBILL. (?) *Spagolobus adratus*
An ophthalmoscopic view of the ocular fundus of this species is pictured as Plate XLIII, page 163 of this work. The painting is of the right eye by the direct method. The shimmering reflections from the translucent retinal elements of the fundus make an accurate ophthalmoscopic view somewhat difficult. The principal color of the eyeground is dull gray, interspersed for some distance about the optic nerve-entrance with a mass of fine, opaque fibres that extend about a disc-length over the fundus. Beyond the fibres are several dull-colored, choroidal capillaries that cross the fundal field in a vertical direction. Near the macular region the fundus is illuminated by a brilliant gray iridescence.

The *optic disc* is a long, white oval, that extends downward and a little inward towards the inner or beak side of the head.

The *pecten* is very large, the lower segment being carried so far forward behind the iris that it is difficult to inspect it with the ophthalmoscope. Instead of the usual fringe of pigment the pecten presents serrated margins.

The *macular region* is quite circular and is red-brown in color. An inner circle is

dead white, while the foveola is represented by a dark-red, central spot. There are two bright rings around the macula of an iridescent, blue-green color, the fundus between the two circlets being a light, luminous gray.

EUROPEAN NIGHTJAR. *Caprimulgus europæus*. The fundus picture (left eye, erect image) of this bird is furnished by Plate XLIV, page 163.

The *eyeground* appears orange-red, everywhere stippled with small, red and brown patches of irregular shape. Scattered about are several pigmented areas, such as one seen in the eyes of human subjects with disseminated choroiditis. This condition, somewhat modified, is seen in many owls long confined in zoological gardens or aviaries, and it seems to be confined to Night Birds, and to be one of the results of confinement and domestication. In many respects, also, the eye of the Nightjar resembles that of the Strigiformes except that *Caprimulgus* has fewer choroidal vessels in the lower half of the fundus. These are faintly outlined, but they give to that part of the eyeground a deeper red than the remainder of the background.

The *optic papilla* is short and broad. The antero-posterior view with the mirror shows it as a dull, grayish-white body largely covered with brown pigment dots. Its margins, where it is not obscured by the mass of the pecten, is much lighter in color. Radiating from the sides of the disc, and extending for a short distance on either side, are a few white opaque nerve fibres, which are light gray and become less distinct on the outer side of the papilla.

ANNA HUMMINGBIRD. *Calypte annæ*. (Figs. 101 and 135; macroscopic view.) The ocular *background* of this species shows two plainly marked *macular regions*, the nasal fovea being, as usual, the better defined. This *area nasalis* is seen as a black spot entirely surrounded (except at the lower fourth of its circumference) by a halo of dark pigment grains. Outside of this is an untinted zone that, in its turn, is encircled by a nebulous ring broader below than above. The tunics of the eyeball are cut to show the temporal site of the second macular

region. Figure 135 furnishes an enlarged picture of this area, which is a duplicate of the *area nasalis* except that the fovea is shallower and not so black, while the pigmentation of the surrounding ring is less marked.

The *pecten* has 32 convolutions—16 on each side—united to a long, narrow sinuous crest. The fold that constitutes the front of the free border becomes broader and rounded as it gradually slopes from the crest to the superior end of the optic disc. Uncertain glimpses are gained of the papillary borders through a few spaces between the more central pectinate folds; otherwise the surface of the optic entrance is entirely obscured.

Cuculiformes

YELLOW-BILLED CUCKOO. *Coccyzus americanus*. (Figs. 102 and 136; macroscopic view.)

The *single macular region* is of immense size—considerably larger than the untinted area on the nasal side of the pecten, and two-thirds as wide as the optic entrance is long. A nebulous zone of pigment dots encloses this large sensitive area, the dots being drawn as distributed everywhere except at the upper fourth of the zone, where they are comparatively few. The *fovea* occupies the exact center of the circle and shows as a dark pigment spot with its upper two-thirds covered with black granules closely spread above it fan-wise.

The *pecten* has about 24 heavy, compact convolutions that almost completely cover the optic entrance. They are joined at the irregular free border above by a translucent, cigar-shaped band of tissue that extends the whole length of the crest.

The anterior and pointed terminal of the *papilla* approaches to within less than a disc width of the temporal boundary of the macular region.

EUROPEAN CUCKOO. *Cuculus canorus*. The ocular fundus of this bird, as seen in living specimens by the aid of the ophthalmoscope, is depicted on Plate XLV, page 165. The picture is drawn of the left eye; erect image.

The coloration of the *eyeground* is gray with a suggestion of fawn, everywhere show-

ing minute, grayish-white dots. Towards the lower quadrants of the fundus and in particular at the extremity of the pecten the background is suffused with a dull pink. Near the optic nerve on either side are several, plainly visible, orange-red choroidal vessels.

The *macula* is seen above the disc, towards the nasal side. This area, slightly red in tone, appears depressed below the fundal plane, although no definite fovea is visible with the mirror.

The *papilla* is almost completely covered by the pecten, so that only the outlines of the former can be seen by the antero-posterior inspection of the ophthalmoscope. Where the papillary margin is visible it shows extremely white.

The *pecten* also extends far above as well as below the disc terminals and projects deeply into the vitreous chamber. It appears by the mirror to be a chocolate-brown in color. Opaque nerve-fibre radiations are seen to originate at the disc margins, whence they cross the background and finally disappear from view at or near the periphery of the field.

Piciformes

SULPHUR-BREASTED TOUCAN. *Rhamphastus lamatus*. As shown in Plate XLVI, page 165, this bird has a dull-gray eyeground (when it is viewed ophthalmoscopically) rather regularly spotted with whitish-gray dots.

The optic *papilla* is apparently composed of short, coarse, white fibres which form a sort of fringe all round its margins. Along each of its sides and parallel to its long diameter a few orange-red, choroidal vessels are seen. Radiating from the papillary circumference are numerous opaque nerve fibres that extend to the fundal periphery across the eyeground on all sides.

The *pecten* is almost black-brown in color and in shape resembles the same organ in the Hornbills and the Kingfishers, especially in the former.

Above the end of the optic nerve entrance and about half its length to the nasal side are three dark-brown spots, clustered together and surrounded by a small gray reflex. This

area is probably the macular region; at least it corresponds to its usual locality in other orders and presents the characters one might expect, knowing the habits of the animal.

RED-SHAFTED FLICKER. *Colaptes mexicanus*. (Figs. 104 and 137; macroscopic view). The ocular *fundus* of this species presents a single fovea (or what in Man is called the *oveola*) that seems larger than usual; at any rate the central black spot is more pronounced than in most Birds. It has no well-defined macular ring but appears to have a place in the uniformly dotted retina about half a disc length above and slightly to the nasal side of the anterior optic terminal.

The *pecten* has seventeen double coils (34 single convolutions) on either side of a prominent and rather deep keel or ridge that unites them above. Of these coils two stand at right angles to the keel, two are slightly curled on themselves and present a concavity towards the posterior free border, while the remainder look in the opposite direction with varying degrees of concavity.

RED-HEADED WOODPECKER. *Melanerpes erythrocephalus*. (Figs. 103 and 138; macroscopic view). The general appearance of this *fundus* much resembles that of the Red-shafted Flicker. It is true that here the *macular field* is defined by a boundary of faint printed dots, but these are hardly distinguishable, except at the infero-nasal quadrant, from the pigment of the neighboring retina. In the center of the sensitive area is a single black spot surrounded by a cloud of dark granules that are wanting below, intended to depict the *fovea*.

The *pecten* has 34 single convolutions. Its structure also closely resembles that of the Flicker just described, but the former is larger, the folds are heavier, and the uniting keel is wider and deeper.

GILA WOODPECKER. *Centurus uropygialis*. An ophthalmoscopic view of the fundus oculi of this bird, as shown in Plate XLVII, page 167, shows it to be dull-gray tinted with yellow, and nearly uniformly charged with minute, gray dots.

At the superior termination of the optic disc (on the nasal side) is a small gray depres-

sion, partly surrounding a central, well-marked and glistening white dot. Within this area are, also, several golden yellow dots, which can be seen only when the reflected light of the ophthalmoscopic mirror falls obliquely upon them. Owing to the limited number of this species that Head and the writer were able to examine it was impossible to say whether the punctate deposits last mentioned are normal or pathological. Further investigation of additional specimens, both ophthalmoscopically and microscopically, will be necessary to decide the question.

The outlines of the *optic nerve entrance* are well defined, and the central area of the papilla at its union with the *pecten* is dull orange stippled with dark brown pigment, like pepper grains. The papilla is fringed with coarse white fibres. A large number of translucent nerve fibres radiate from the edge of the optic disc on all sides; they become fainter and fainter as they approach the fundal periphery and finally disappear.

The *pecten*, of the usual chocolate brown color, reveals several corkscrew convolutions. It comes well forward towards the lens, and presents a massive, club-shaped appearance.

In most respects this fundus picture resembles the eyeground of the Greater Spotted Woodpecker.

GREAT SPOTTED WOODPECKER. *Dryobates vel Dendrocopus major*. The fundus picture of this species is seen as Plate XLVIII, page 167. The color of the eyeground is a uniformly dull but definite gray, interspersed with a large number of small, gray dots. Below the optic disc and *pecten* are a few faint, orange-red choroidal vessels.

The *optic disc* is apparently built of a mass of brilliant, white, opaque fibres, very short and thick. In the form of radiations from the margins of the papilla towards the fundal periphery run many gray, opaque nerve fibres, that appear to occupy a plane lower than the white elements of the disc.

The *pecten* has three corkscrew convolutions on the disc, while its lower part forms a club-shaped mass of a deep chocolate-brown color that appears to come well forward towards the lens.

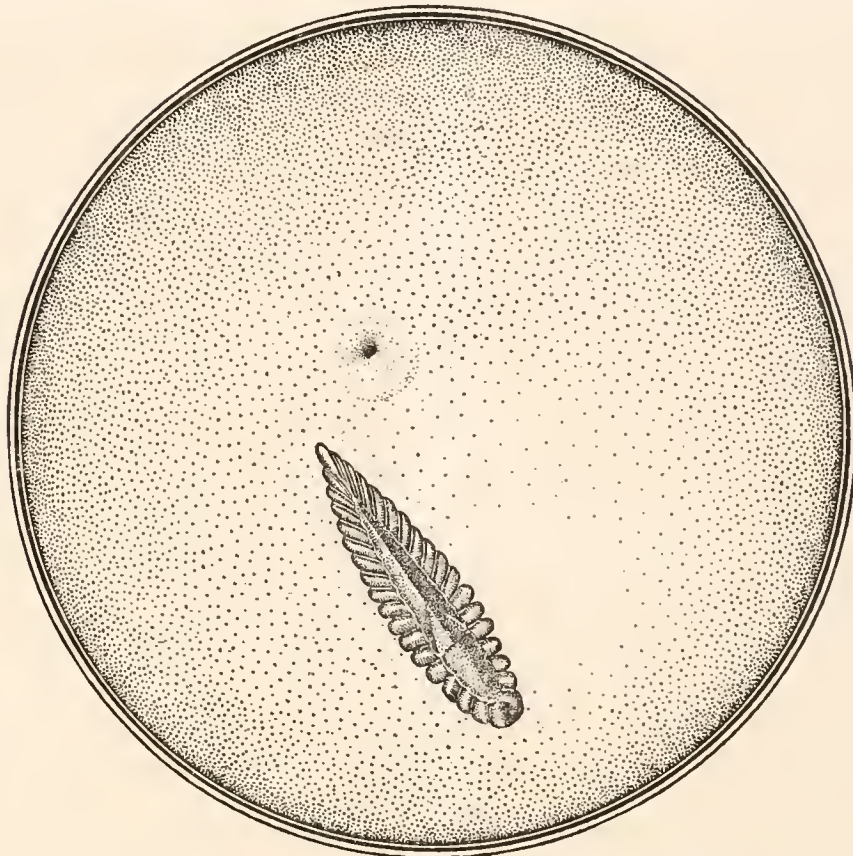


Fig. 138. Red-headed Woodpecker (*Melanerpes erythrocephalus*) $\times 13$.

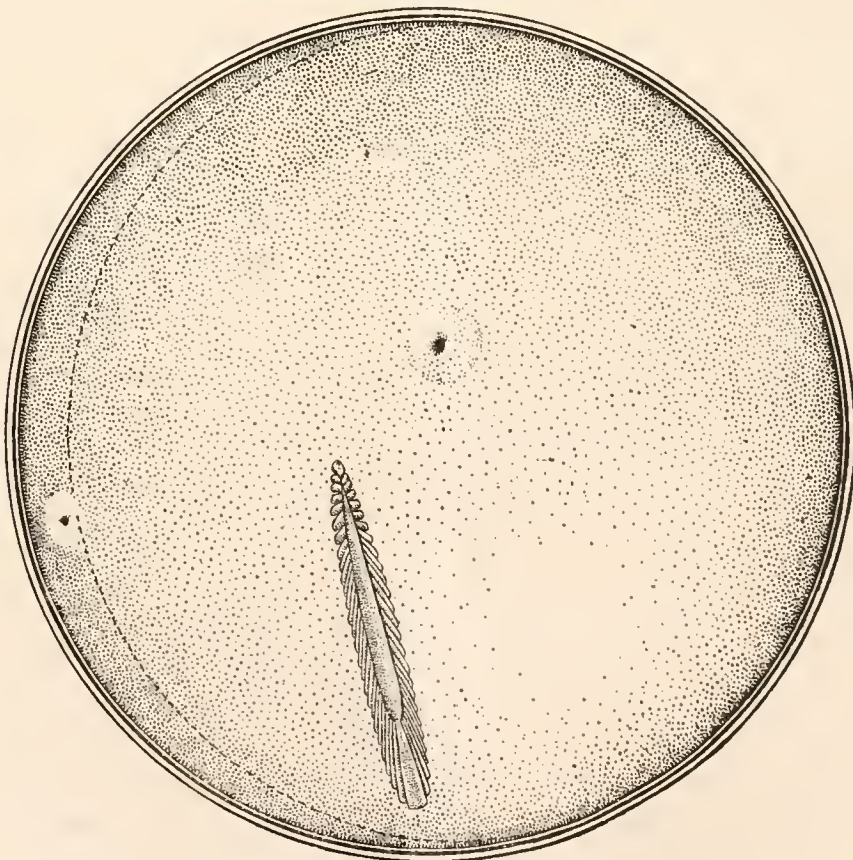

Fig. 139. Western Mockingbird (*Mimus polyglottos leucopterus*) $\times 14$.

Macroscopic Appearances of the Fundus Oculi in the Preserved Eyes of Birds.

There seems to be only *one sensitive central area*. This single macula is, as usual, on the nasal side of the pecten and has the appearance of a brilliant, white, round dot, the fundus surrounding it being a little darker than the general color of the eyeground. The surrounding gray area makes the white fovea stand well forward, almost as if it were actually situated in the vitreous. No reflex ring can be seen around it.

Passeriformes. *A. Mesomyodi*

DERBY TYRANT. *Pitangus derbianus*. The fundus view of this species, shown by Plate XLIX, page 169, represents ophthalmoscopic examinations of three specimens. The six eyes of the three birds presented precisely the same ophthalmoscopic appearances.

The *eyeground* is blue-gray, everywhere sprinkled with minute, gray dots. These dots are so closely packed in the upper half of the fundus that they give it a distinct silvery appearance. Running at right angles to either side of the optic papilla are numerous dull-white opaque nerve fibres. These are near together and extend well across the eyeground.

At right angles to the optic disc towards the nasal side and a little above its superior end is a dense, pale-blue, punctate mass that appears to surround the fovea. A light-blue reflex ring also encircles this area.

The *optic nerve-entrance* is long, narrow and white. Its centre is stippled with a few brown pigment dots, and it is bordered all around with symmetrically placed black pigment granules. This pigmented margin varies a little in individuals. The pecten, long and narrow, extends well behind the edge of the pupil so that a portion of it cannot be seen through the mirror. The upper part is serrated but the lower half is more of the corkscrew type. The color is the usual deep, dull brown.

Passeriformes. *B. Acryomodi*

EUROPEAN CHIMNEY SWALLOW. *Hirundo rustica*. The ophthalmoscopic appearances in this species are shown on Plate L, page 169, and depict the erect image of the right fundus.

The *general color* of the eyeground is warm gray, tinted slightly with yellow or buff, and covered with minute, dull, yellowish dots. Several pale orange (choroidal) blood-vessels are seen near the upper extremity of the optic nerve-entrance.

There are visible two *macular regions*, one on each side of and above the upper end of the disc. [They show as small brown areas or dots in the eyeground. Surrounding the temporal macula is a slight reflex, apparently composed of minute, bright gray dots. The macula on the nasal side is quite devoid of this reflex-ring.]

The *optic papilla*, long and narrow, tapers at its upper end. On either side of the disk, and at right angles to it are a few, fine, dull-gray opaque nerve-fibres.

The *pecten* is quite narrow at its junction with the optic nerve, but it gradually becomes wider and more massive as it approaches the lens. It is of the usual chocolate-brown color, and is convoluted.

WESTERN MOCKINGBIRD. *Mimus polyglottos leucopterus*. (Figs. 105 and 139; macroscopic view). In this fundus are seen two sensitive areas. The *area nasalis*, lying above and anterior to the superior end of the optic entrance about half the length of the papilla, is seen as a black spot capped on its temporal aspect by a semi-circle of large pigment grains. The whole macular region is not only bordered by pigment but the intervening zone is, in the nasal three-fourths, also sprinkled with minute granules. The *area temporalis* is placed almost directly posterior to but much farther from the upper end of the disc than the nasal fovea. It is evidently shallower, is less plainly outlined and the *foveola* is not as large. [The black line running along the left side of the large figure indicates that a segment of the globe has been removed — to show the temporal macula.]

The very long, narrow *pecten* has 52 single, compact convolutions that everywhere hide the optic entrance. A moderately deep and wide keel unites the pectinate folds along the upper free border of the pecten almost to its junction with the superior, pointed end of the disc.

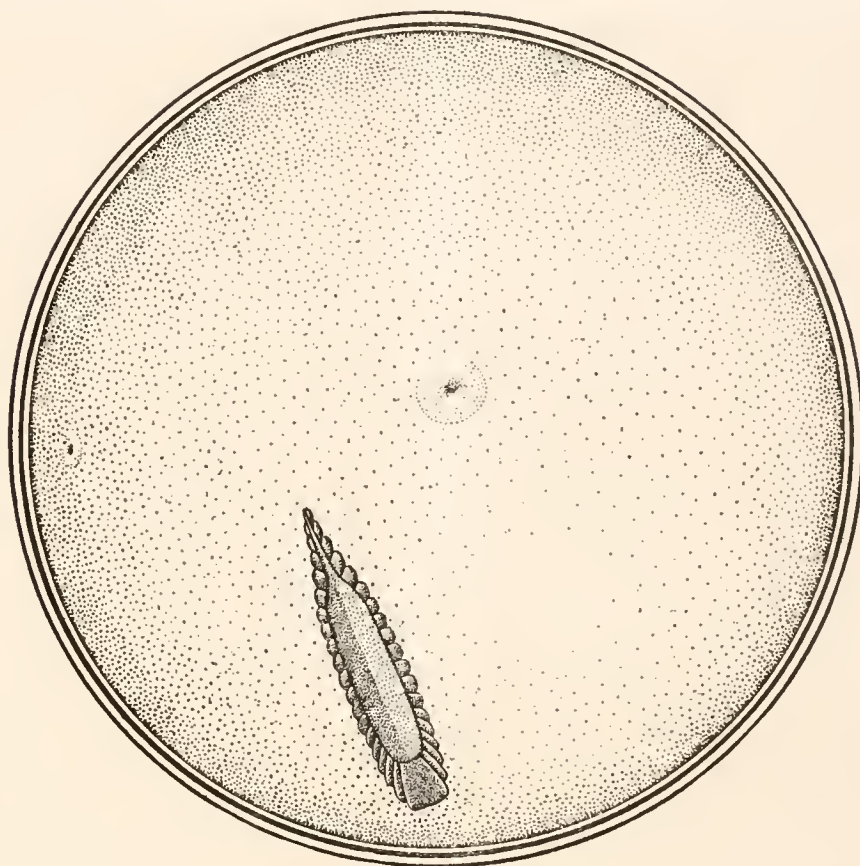


Fig. 140. Bluebird (*Sialia sialis*) $\times 18$.

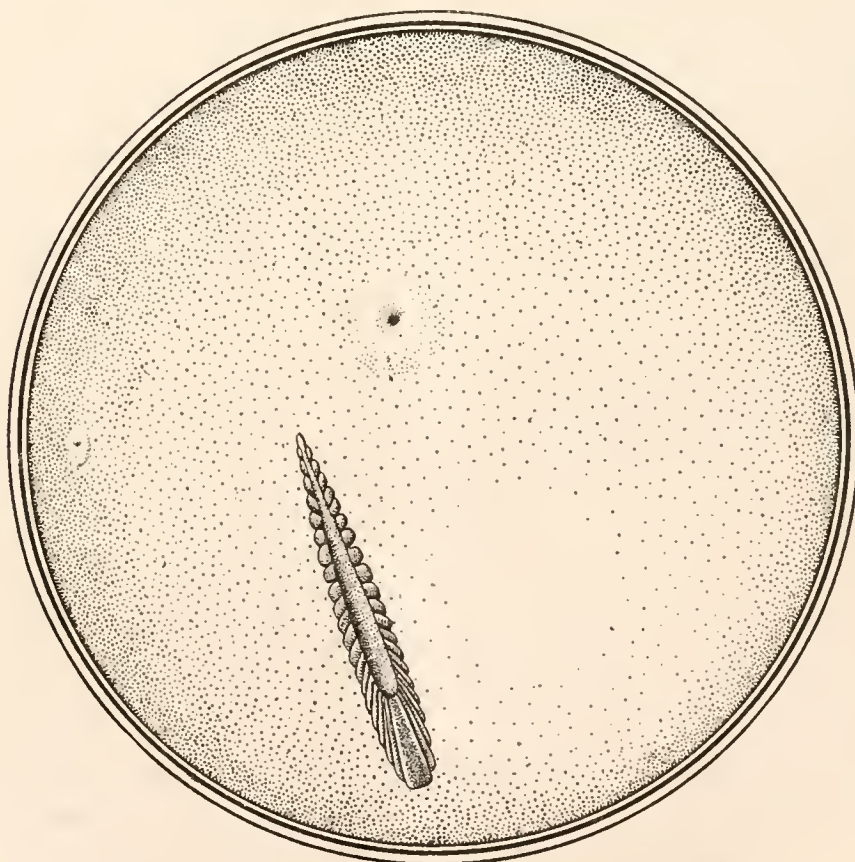

Fig. 141. California Shrike (*Lanius ludovicianus gambeli*) $\times 12$.

Macroscopic Appearances of the Fundus Oculi in the Preserved Eyes of Birds.

AMERICAN MOCKINGBIRD. *Mimus polyglottos*. The ophthalmoscope shows the prevalent coloration of the fundus in this species to be a clear, blue-gray. Thickly scattered over the background are irregularly shaped, whitish-gray dots or granules that in the upper sectors of the field give the fundus an unusually bright gray appearance.

Near the upper extremity of the optic papilla and towards the nasal side is the *macula*. This area is darker blue than its surroundings, while its centre (the fovea) is marked by a bright white dot which, again, is enclosed in a green reflex. This greenish reflex-ring has a striated appearance, the striæ being quite translucent and convergent towards the *fovea centralis*.

The *optic disc* is long and narrow; the visible portion is brilliant white and its margins are traceable on either side the whole length of the pecten. Radiating from the boundary of the nervehead are many long, opaque nerve fibres that extend over the eyeground to its periphery.

The *pecten* is, as usual, of a chocolate-brown color; it is long, somewhat club-shaped and extends well behind the margin of the iris, so that its outlines are not entirely visible by the mirror through the undilated or only partially dilated pupil.

The fundus of the Cuban Mocking Bird (*M. orpheus*) is similar in every respect to that of *Mimus polyglottos*.

BLUEBIRD. *Sialia sialis*. This was one of the earliest species examined ophthalmoscopically by the writer, and he was so struck by the wonderful *blue coloration* of the ocular background that the question arose in his mind as to whether there might not be some connection between plumage tints and fundus coloring. That query was soon answered in the negative but the beautiful blue shades in the eyeground of *Sialis* are still to be admired.

As seen in Plate LI, the ophthalmoscope shows that the general blue-gray coloring of the eyeground is modified by numerous, pinpoint dots. The punctate deposits near the periphery assume a more or less dull-golden or orange tint, a condition also noticed just

below the pecten. The elongated, ovoid optic disc is white (quite woolly at its margins) and covered almost entirely by the convoluted pecten, which is very large when compared with the size of the eye. A portion of the unusually extensive pecten cannot be seen through the small pupil. It is of the usual dull-brown color, and has "frilled" borders. On the inner or nasal side and near the lower part of the optic disc is an orange-red area, containing chiefly choroidal vessels with black pigment grains between them. This red area extends a little to the temporal side of the disc, subsequently merging into the dull orange color below. On either side of the disc and radiating from it, are numerous filiform nerve fibres which cross the background almost to its periphery. In an area a disc-length to the nasal side of the papilla, the white dots of the fundus are fainter and much closer together than elsewhere; and in this region, also, there is a reflex plainly marked. Here, if in any part of the fundus, is the fovea or macula, but it is not sufficiently well defined to be certain of it.

Figures 106 and 140 demonstrate quite conclusively that in the fundus of *Sialia sialis* there are *two macular areas*, symmetrically placed above and on either side of the pointed end of the papilla. The *area nasalis* is removed about half a disc length; the *fovea temporalis* is somewhat more distant from the same point. The *nasal macular region* is larger and more plainly marked; it is surrounded by a dotted ring, incomplete above; the corresponding *foveola* is represented by a black spot crowned by pigment grains. More than half the intervening zone is lightly strewn with minute, dark granules.

The heavily-built *pecten* is composed of 19 thick, rounded, double folds — or 38 convolutions. A comparatively massive, paddle-shaped crest surmounts these and extends along the whole of the upper free border. The major axis of the papilla makes with a line joining the two foveolæ an *infulapapillary angle* of about 70°. There is nothing to be seen of the nerve head from above.

WHEATEAR. *Saxicola œnanthe*. The color reproduction shown in Plate LII, page 171,

furnishes an exact view of the ophthalmoscopic appearances of the fundus oculi of this species. It is of the left eye, erect image. The general fundal coloration is pale gray, with a dense mass of grayish white dots permeating the entire background.

Slightly above the upper termination of the optic nerve, and towards the nasal side of the pecten, is a well-defined, round, white area, (the *macula* and *fovea*) much larger than the small spots that cover the whole of the surrounding, duller eyeground. This white area is inclosed by a brilliant, bluish-green circle, which appears more prominent and iridescent in nature than is depicted in the drawing.

Little can be seen of the *optic papilla* because it is almost entirely obscured by the pecten. However, it is long and narrow, with an irregular outline.

On the nasal side of the nerve-head are a few short, orange-red, choroidal blood-vessels with a few dots of pigment, like pepper grains, sprinkled between them. Extending from both margins of the optic disc across the fundus to the periphery, are numerous fine, opaque nerve fibres, the upper ones (on the nasal side), terminating at the macular area.

The *pecten*, red-brown in color, long and narrow, appears to be twisted on itself like a rope or a corkscrew. Its inferior end extends beyond that part of the eyeground shown in the picture, but it probably comes well forward towards the posterior surface of the lens.

ENGLISH NIGHTINGALE. *Aedon megaryncha*. The ophthalmoscopic appearances of this species is almost identical with those of the Wheatear (see Plate LII, page 171), except that in *Saxicola* the macular region is not so well defined.

CALIFORNIA SHRIKE. *Lanius ludovicianus gambeli*. (Figs. 107 and 141; macroscopic view).

There are *two macular regions* in the fundus of this bird, similar in every detail to the same areae in the Bluebird.

The *optic papilla* is, however, longer and somewhat narrower in *Lanius*, and the more extensive pecten exhibits folds joined along its free border by a rounded crest that from

above takes on the shape of a carrot. The major axis of the long ovoid disc projected until it meets a line crossing the floor of the concave fundus and joining the two foveolæ would subtend an (infulapapillary) angle of about 110°.

Passeriformes. B. *Alaudidae*

EUROPEAN TITLARK. *Anthus pratensis*. A healthy adult male individual of this species, about three months in captivity, obtained from a dealer, was examined by the writer in the laboratory of St. Luke's hospital. The pupils were unaffected by one drop of a 1% sol. of atropia instilled 48 hours previously. The bird was strongly hyperopic and very slightly (about 0.33 D.) astigmatic, the skiascope showing 3.50 D. of HAS in each eye.

The ophthalmoscopic examination revealed no opacities in the ocular media.

The *pecten* is of the usual black-brown color; it is large and spiral, filling the whole pupillary area when examined with the mirror, and almost entirely obscures the outline of the optic papilla from which it springs.

The *background* is of a fine, pepper-and-salt character with a very few opaque nerve fibres radiating from the disk. Scattered over the field are many fine sparkling points like minute grains of cholesterine. These are also to be found in the *macular region*, which is definitely outlined directly in the axis of vision and covers a space about $\frac{1}{3}$ of a disc-length. The mirror does not show a second area of acute vision.

Passeriformes. B. *Fringillidæ*

BRITISH LINNET. *Linota cannabina*. The indirect ophthalmoscopic examination of an imported individual, in captivity a year or less, shows a pecten that obscures a view of the fundus details, but the prevailing color of the eyeground is readily seen to be a beautiful, light, gray-blue beset with whitish dots.

BRITISH GOLDFINCH. *Carduelis elegans*. The fundus of this bird as seen by the indirect method — it was extremely difficult and unsatisfactory to make an ophthalmoscopic examination by the erect image — showed an eyeground that resembles that of the Linnet

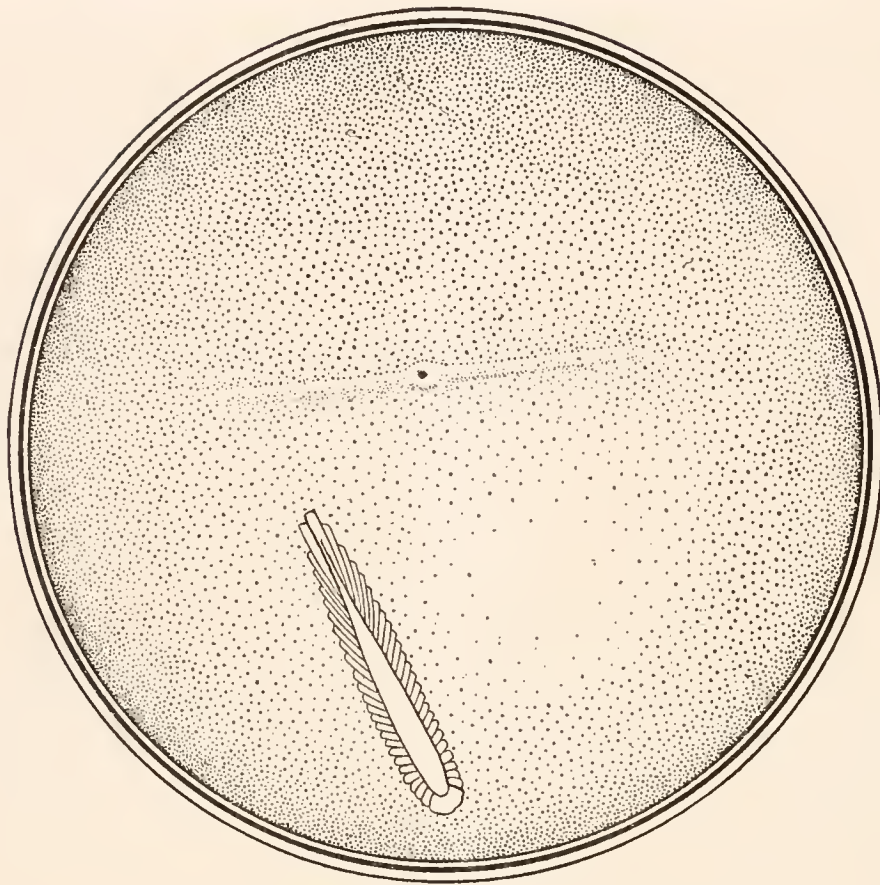

Fig. 142. American Crow (*Corvus americanus*) $\times 8$.

Macroscopic Appearances of the Fundus Oculi in the Preserved Eyes of Birds.

in being uniformly light blue-gray. The pecten obscured most of the field.

BRITISH SISKIN. *Chrysomitris spinus*. One of this species, obtained from a dealer and said to have been captive for six months, was examined by the indirect method through the small and undilated pupil. There was a relatively large pecten which made it impossible to outline the optic nerve-entrance clearly or to determine the fundus details. However, the prevailing color of the eyeground was light gray-blue, more or less regularly besprinkled with minute, yellow-white dots.

HOUSE SPARROW. *Passer domesticus*. The ocular fundus of this typical species is pictured as Plate LIII, page 173 the result of the ophthalmoscopic examination of numerous specimens. The dominant coloration of the eyeground is pale-gray covered with very fine white dots, closely packed together at the macular area. They form a lighter zone a little above the upper extremity of the pecten

and towards the nasal side of the disc. From the circumference of the optic disc a large number of rather long, opaque nerve fibres run in radial fashion towards the periphery of the fundus.

The *papilla* appears, when visible, to be composed of irregularly shaped, brilliant, white bundles; it can barely be outlined with the mirror except at the upper (and narrow) end of the pecten.

The pecten has a deep red-brown color, and its free extremity is long, narrow and of the corkscrew type. The lower segment of the organ extends well forward towards the lens and, being large and massive, completely covers the pupil and makes it impossible to obtain a lateral view.

VARIED BUNTING. *Cyanospiza versicolor*. Plate LIV, page 173, represents the ophthalmoscopic appearances of this species. The prevailing color of the *eyeground* is dull gray shading to buff. It is covered all over with

very minute, grayish-white dots. These dots coalesce at the *macula* where they form a soft, round area bordered by a light reflex. The single macular region and fovea are situated a little above the upper end of the pecten and towards the nasal side of the optic nerve. The *pecten*, very large and massive for the size of the eye, is of the usual chocolate-brown color; it is more or less club-shaped, and extends well forward towards the lens. At times it quite fills the area of the pupil, so that the fundus is difficult to explore. The pecten, whose outline is very irregular, covers the papilla entirely so that it appears to spring directly from the retina without showing the white disc margin found practically in all birds. From the sides of the apparent root of the pecten a few, whitish, opaque nerve fibres cross the field of view.

Passeriformes. *B. Tanagridæ*

SCARLET TANAGER. *Piranga erythromelas*. The dominant coloration of the eyeground in this species — readily seen by aid of the indirect method — is a clear, bright gray-brown, sprinkled with numerous, glittering whitish-yellow points.

LAW BIRD OF PARADISE. *Parotia lawii*. Plate LV, page 175, gives an ophthalmoscopic picture of the fundus of the left eye, erect image.

The *eyeground* appears yellowish gray, or khaki color, almost uniformly covered with a dense mass of minute white dots, that are smaller and denser at the macular region. A few dull-red choroidal capillaries are visible on the lower part of the fundus near the periphery.

The *optic nerve head*, dull-white, long and narrow, has a rounded upper end. Its entire central area appears as if it were a mass of fine, brown pigment dots.

The *pecten* is exceptionally long, rather narrow, spirally arranged and extends beyond the range of vision through the undilated pupil. It is similar in many respects to the fundus of the Common Pigeon.

To the nasal side and a little above the end of the disc is the *macular region*, which appears as a dull-brown, crater-like depression bound-

ed by a white mass of (reflex) striations. Opaque nerve fibres radiate from both sides of the disc but finally disappear as they approach the boundaries of the fundus.

Passeriformes. *Corvidæ*

BLUE JAY. *Cyanocitta cristata*. The fundus appearances as revealed by the ophthalmoscope in the left eye of one of this species is depicted as Plate LVI, page 175. The general color of the eyeground is a slate-gray, with an added pale-yellow tint in the lower half of the eyeground. The entire field is besprinkled with irregularly shaped, light-gray dots, giving it the appearance of a rough and rather coarse surface, especially near the macular area where the dots are more closely packed in the shape of a bright, circular patch.

The *optic nerve-head* is quite white and of oblong shape. Several orange-colored, choroidal capillaries are visible in this region, covered with minute, brown, pigment dots, like black pepper grains. Sprinkled about each side of the optic disc is a large number of opaque nerve fibres that extend across the fundal field.

The *pecten*, of the usual chocolate-brown color, is rather irregular in shape at its superior extremity. From above downward it looks like a tarred ship's cable, becoming larger as it approaches its union with the papilla. The length and thickness of this organ (compared with the size of the eye and pupil) make it difficult to follow its outlines throughout. The superior end appears to come well into the vitreous cavity and to reach the lens.

STELLER JAY. *Cyanocitta stelleri*. (Figs. 111 and 109; macroscopic view). The ocular *background* of this species exhibits a moderate-sized, though well-marked, single, circular *macular region*. The *foveola* is shown as a dark spot crowned by minute pigment grains that mingle with a similar pigment ring of granules that serve as a boundary for the whole region. There is a small, kidney-shaped space between these two collections of dotted pigment that seems free of color. The centre of the fovea is slightly above and about half a

disc-length from the anterior end of the optic entrance.

The long and wide *pecten* has 54 single convolutions, and in shape resembles the same organ in the Shrike, except that from the center of its crest rises a short spine easily seen in both figures. The optic papilla is almost completely hidden by the mass of the marsupium.

AMERICAN CROW. *Corvus americanus*. (Figs. 108 and 142; macroscopic view). There is in the background of this species an area of acute visual perception represented by a *retinal bar* or band at whose middle point is seen a well defined *fovea*, the center of a macular region formed by a widening of the band itself. The band stretches horizontally across the fundus and is centrally located in the field of view. It is of medium width, outlined by a uniformly dotted line above, but less distinctly below by a string of minute granules that more or less tint the lower half of the band itself. The macular region is formed by a widening of the sensitive band to form an oval-shaped region.

The superior end of the *papilla* is one-half its length from the foveola.

The large *pecten* (three-fourths the length of the retinal band) is formed of about 52 uniformly compressed convolutions joined at their free margins, above, by a shallow, dumb-bell-shaped crest that slopes gradually from behind forwards.

If the major axis of the papilla — obscured by the pectinate mass — were projected to meet the temporal end of the retinal bar it would describe an (infulapapillary) angle of about 60°.

EUROPEAN CARRION CROW. *Corvus corone*. The writer examined in the Laboratory of St. Luke's Hospital, Chicago, an adult male of this species, imported from Germany. He had been in captivity about a year. Both eyes were healthy. He used his nictitating membrane freely on the approach of light to the eye. The pupils varied in diameter from 2 to 4.50 mm. A single drop of 1% solution of atropine sulphate into each eye produced no effect on the size or movements of the pupils during the following

48 hours. The same negative result was obtained by the use of a one-fifth per cent solution of hyoscin and by a mixture of homatropine and cocaine. Skiascopy in the dark room showed, both before and after the use of atropia, a hyperopia of 2D.

By the direct method the *background* appears to be almost uniformly dark red-brown. The *macular region* is seen with difficulty.

The *optic disc* is a long, white oval with the *pecten* a very black, corkscrew-like organ, apparently changing place and shape rapidly under examination.

COMMON BRITISH BLACKBIRD. *Turdus merula*. The ophthalmoscopic picture of this species is reproduced as Plate LVII, page 177. It shows the eyeground as seen in the left eye by the direct method. The *general tint* is a slaty-gray with a uniform sprinkling of tiny, white dots. There is no visible *macular region*, but the whole fundus is covered and its coloring greatly modified by numerous, linear, opaque fibres that arise from the disc margins throughout and run across the entire fundus to the extreme periphery. A few faint, yellow-red choroidal vessels are seen on either side of and parallel to the moderately long and narrow *papilla*. The upper two-thirds of the disc is about half covered by the club-shaped *pecten*, which is apparently composed of very few folds. The massive, chocolate-colored, posterior end of this organ entirely obscures the lower third of the nerve-head, while the upper half of the former has a light brown margin on its nasal aspect, and seems to be only in part attached to the nerve-head beneath it.

RAVEN. *Corvus corax*. The fundus picture (right eye) shown by Plate LVIII, page 177, represents the (similar) appearances in a number of specimens examined with the ophthalmoscope by Mr. Head in the London Zoological Gardens and by the writer in the aviary of the Bronx Park, New York.

The *eyeground* is a light fawn sprinkled with dots about three shades darker than the ground color. Mixed with the dark dots are numerous white ones, seen especially when a strong light is thrown upon the fundus.

About three disc-breadths from the upper end of the disc on the inner side is a well marked, bright reflex of a greenish-blue tinge. It is irregularly oval in shape and seems to be composed of a number of very fine fibres. In the center of the reflex is the *macula*, a small, dark, crater-like depression, brown in color. The disc is chalky white, and gives one the impression that it is composed of many opaque nerve fibres packed closely together. From the disc margins there radiate a number of fine optic nerve fibres that extend across the eyeground. In

the lower part of the fundus, associated with a number of orange-red dots, are a few orange-red choroidal blood-vessels, several of the latter being distributed along either side of the disc.

The *pectens* in all the Ravens examined were of similar shape and of the usual dark-brown color. They were very thin and narrow at the disc but assumed a club-shape as they approached the lens where they were darker in color. The pecten comes well forward and appears at times to press against the posterior capsule of the lens.



CHAPTER X

CLASSIFICATION OF THE OCULAR FUNDI OF BIRDS

THE particolored avian background, as seen by the ophthalmoscope, although of great variety, may be divided into two major categories and each of these into five subdivisions, as follows:

A. The *avascular fundus*, in which there are no visible retinal or choroidal blood-vessels.

This class resolves itself into (a) those avascular eyegrounds in which the predominant color is *light gray or gray-blue*. These fundi are comparatively rare, but examples of them are found in the Varied Bunting (Plate LIV) and the Ipecaha Rail (Plate XIII).

(b) *Dark gray, deep gray-blue or slate-colored avascular fundi* are quite common. The Harlequin Quail (Plate VIII), English Sparrow (Plate LIII), Derby Tyrant (Plate XLIX), Brush Turkey (Plate VII), Yarrell's Curassow (Plate VI), Sulphur-crested Cockatoo (Plate XLI), and the European Bittern (Plate XXI) are samples. The fundi of the Crested Coot (Plate XII) and of the Black Hornbill (Plate XLIII) belong to this subdivision but they also show a greenish tinge.

(c) *Yellow, orange and orange-red bloodless fundi* belong almost exclusively to Night Birds, or to those that use their eyes for both diurnal and nocturnal visualization. Such fundi are seen in the Apteryx (Plate IV), Gannet (Plate XXIX), and the Black-footed Penguin (Plate XIV). The corresponding class of *vascular fundi* is a much larger one.

(d) *Fundi of a brownish or russet color, showing no vascular supply*, are rather common. Examples are seen in the Amazon Golden Parrot (Plate XXXIX), South Amer-

ican Ostrich (Plate II) and the Cassowary (Plate III).

(e) *Bicolored or multicolored fundi devoid of visible blood-vessels* are but infrequently encountered. The fundus of the Nubian Ostrich (Plate I) is mostly of a light chocolate shading to red; also the Bluebird (Plate LI) exhibits a background mostly light gray-blue but has also a small red-brown area or zone dotted with black.

B. The *vascular fundus oculi* is one in which the *choroidal capillaries show more or less distinctly*. In some instances the blood-vessels are barely visible; in others they cover the whole background and are the most conspicuous objects in it. The vascular fundus is subdivided like the avascular background.

(a) *Light gray or gray-blue fundi*, more common than A (a), are found in the Wheat-ear (Plate LII), the Cormorant (Plate XXVIII), and the Glossy Ibis (Plate XXIII).

(b) *Dark gray, deep gray-blue or slate-colored vascular fundi* constitute the commonest examples of colored fundi so far seen by the writer. They are found, among others, in the European Cuckoo (Plate XLV), the Wonga Wonga Dove (Plate IX), the Puffin (Plate XV), Sulphur-breasted Toucan (Plate XLVI), Spoonbill (Plate XXV), Great Spotted Woodpecker (Plate XLVIII), Blue-crowned Jay, with a greenish tinge (Plate LVI), Common British Blackbird (Plate LVII), the Night Heron (Plate XX), American Jabiru (Plate XXIV), Law Bird of Paradise (Plate LV), Lämmergeier (Plate XXXII).

(c) *Yellow, orange or vermilion fundi showing choroidal blood-vessels* are, as in the A(c) class, found almost entirely in birds with

nocturnal habits. Among them are the Brazilian Boatbill (Plate XXII), Kakapo (Plate XL), and the Barn Owl (Plate XXXVIII).

(d) *Vascular fundi whose general coloration is brown, brownish or russet* are also fairly common. The White-bellied Sea Eagle (Plate XXXIV), Gila Woodpecker (Plate XLVII), Laughing Kingfisher (Plate XLII), Little Bustard (Plate XXXVI), Raven (Plate LVIII), Stone Plover (Plate XVII), Great Blackbacked Gull (Plate XVI), Blue Snow Goose (Plate XXVII) and the Chimney Swallow (Plate L) are among them.

(e) *Bicolored or multicolored vascular fundi* are commoner than those classed under A (e). The vascular eyeground of the Martineta Tinamou (Plate V) is brownish below and light gray above; its color scheme reminds one of the ocular background (when seen ophthalmoscopically) of some mammalian fundi. The Australian Pelican (Plate XXX) has a fundus oculi which is russet below gradually shading to grayish above. The eyeground of the Kagu (Plate XVIII) is also reminiscent of mammalian color mixtures; the lower half of the background is a well-marked red-brown dotted with black pigment, while

the upper segment is a sky blue. The lower two-thirds of the fundus oculi of the Brazilian Seriema (Plate XIX) is brownish, the upper third slate-blue. The Bald Eagle (Plate XXXIII) has also a mixed fundal coloration; being dull red-brown below and mottled gray above. Finally, the eye of the nocturnal Nightjar (Plate XLIV) mimics to some extent the fundal color distribution in the background of certain of the night-prowling mammalian Carnivores, being dark orange-red below and light orange above.

In the above classification the *colored dots that besprinkle the fundus picture* of practically all Birds (and represent, probably, the colored droplets of the retina) are not considered. However, both directly and by contrast they greatly modify the *color impression* made upon the observer, and especially when they are large and numerous, influence the general chromatic effect. In some instances, their number and distribution are such as to determine the verdict of a first glance, and the observer must be on his guard not to mistake these accessory pigment points for the solid background of color which one finds in all avian fundi.

CHAPTER XI

THE OCULAR FUNDUS OF BIRDS IN ITS RELATION TO A CLASSIFICATION OF AVES

THE writer is well aware of the controversies so easily provoked in that zoological storm centre, the systematic classification of Birds, but he believes that as the fundus appearances in wild species are probably invariable and that, as the evidence so far produced shows, each species exhibits a background picture distinct in one or more particulars from every other species, it is possible to identify many of them by the use of the ophthalmoscope alone; in other words, in the classification of Birds the fundus details, including the varied coloration of the eye-ground, should be considered quite as much as the histology of any organ or division of the body.

The extent to which these taxonomic indications correspond to the *orders* of any particular classification cannot, in the absence of a complete or nearly complete investigation, now be determined. In the opinion of the writer, however, there are certain facts that have arisen in the course of this preliminary research that are worth discussing for the light they throw upon and the aid they may give to a systematic arrangement of avian species.

That the eyegrounds of the *Ratite orders* present peculiarities that distinguish them from the *Carinatae* is evident at a glance. On the other hand there are the usual differences between the *acarine* species. The coloration of the fundi and the characters of the pectens in Rhea (Plate II) and Struthio (Plate I) bear a close resemblance. The ocular fundus of the Cassowary (Plate III) is more closely allied to that of the Kiwi than to the Nandu. The ocular background of the Tinamou is decidedly *acarine* and this fact,

with other taxonomic indications, justify, from the ophthalmoscopic viewpoint, its inclusion in that subclass.

The Apteryx is so decidedly a nocturnal animal — especially in the use of its eyes for distinct vision both in the distance and near — that one is not surprised to see so much yellow in its fundus coloration. There are so few exceptions to the rule of the yellow-colored fundus in Night Birds that one may confidently assert that the amount of this color in avian (one might say in all vertebrate) fundi is in direct ratio to the proportionate use a given species makes of its visual powers after sunset. When a bird and his ancestors (in the evolutionary sense) have used their eyes for distinct visualization largely or exclusively at night the fundus tint is nearly always yellow or orange.

Applying this rule to *carinate* Night Birds we find many consistent and marked examples of it. For instance, all the *Strigiformes* so far examined have a preponderance of yellow in their eyegrounds. Without carrying this assertion too far we note that in semi-nocturnal Owls, like *Strix flammea* (Plate XXXVIII), the red tints overpower the yellow and a shade of orange results.

Still more suggestive are the fundal conditions seen in the Owl Parrot, *Stringops habroptilus* (Plate XL). Compare the fundus, especially its yellow color and the position of the (temporal) *area centralis*, first with that of any Owl and then with *Psitticus amazona*; undoubtedly, so far as the eyes are concerned, they belong to the former.

Another observation of avian fundi seems to show that an admixture of yellow (in the

form of an orange-red coloration) may be present to indicate not so much recent as former, i. e. atavistic, night habits long since abandoned by the species.

This almost universal occurrence of yellow or orange-tinted fundi in Night Birds leads one to speculate as to the cause of a different coloration in species that, during historic times at least, have used their eyes largely or exclusively after dark. At least some of the Ardeiformes furnish such examples. The fundal coloring of *Nycticorax nycticorax* (Plate XX) has no yellow in it; nor has the Boatbill (*Cancroma cochlearia*), although both fundi are evidently so closely allied that one might well believe that they are both Herons. Probably the Night Herons have adopted an

exclusively nocturnal life at such a recent geologic period that the evolutionary tissue changes necessary to produce the yellow fundus tints have not yet been brought about. The same remark is applicable to the Bittern (Plate XXI).

So far as examined, the decidedly nocturnal Caprimulgidæ also have yellow or orange fundi. The eyeground of the European Nightjar (Plate XLIV) is a conspicuous and typical example of the colored fundus of a true Night-feeding bird.

The arrangement of the centres of distinct vision, the fundus tints and the pectinate tissues of the larger *Acciptriformes* present a decided ophthalmoscopic resemblance in all the species so far examined by the writer.

CHAPTER XII

RELATIONS OF REPTILIAN TO AVIAN FUNDI

THE colored illustrations of three eyegrounds of reptiles are published by the aid of Mr. Head and through the courtesy of Mr. Lindsay Johnson. In this text are also included, for purposes of comparison, two black-and-white drawings of mammalian fundi. One of these, the Common Hedge-Hog (Fig. 143)

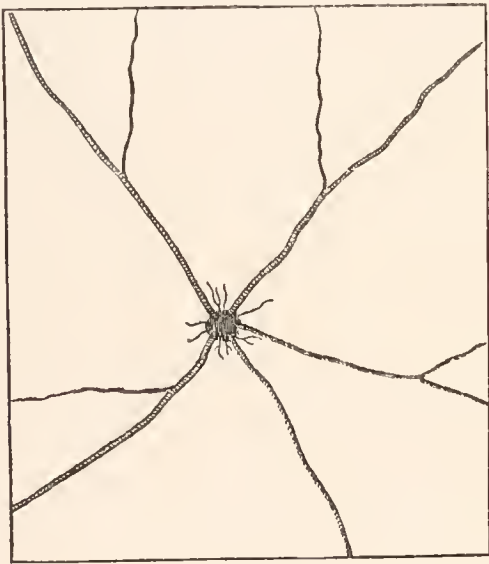


Fig. 143

Fundus Oculi of the Common Hedgehog.
(After Lindsay Johnson.)

reminds one of the Indian Cobra (Plate LXI), while the fundus view (Fig. 144) of the Virginian Opossum suggests the background of the Horned Toad (Plate LX). In other words, these two reptilian fundi have more marked affinities with other vertebrate classes than with Birds. On the other hand, were it not for the absent macular region and the greater prominence of the radiant, retinal nerve fibres, the ocular fundus of that nocturnal lizard, *Hemidactylus turcicus* (Plate LIX) might be regarded as an avian form, rather

closely related, for example, to the Kiwi (Plate IV).

A reference to the probable evolutionary connection between Birds and certain suborders of Reptiles, as indicated by their ophthalmoscopic pictures, has already been made. It may eventually transpire, as indicated by this "straw" of evidence, that the *Geckotidæ* are comparatively near relatives of the primitive Bird, while other lacertilian suborders and the *Ophidia* are as far removed from them as the Marsupials.

A detailed description of the three reptilian eyegrounds, represented in the Atlas by colored reproductions, now follows.



Fig. 144

Fundus Oculi of the Virginian Opossum
(After Lindsay Johnson.)

Reptilia

TURKISH GECKO. *Hemidactylus turcicus*. Erect image; left eye. The fundus appearances (Plate LIX) of this nocturnal lizard remind one of the Kiwi (Plate IV). The orange-red background is uniformly dotted with dark spots, while the circular papilla is completely obscured by a chocolate-brown

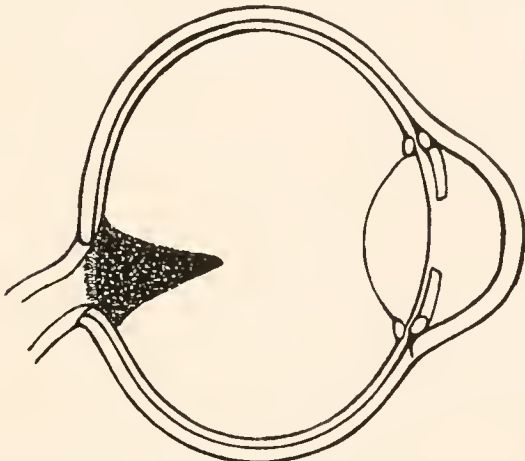


Fig. 145

Pecten of a Turkish Gecko (*Hemidactylus turcicus*).

pecten, whose pointed free end projects a medium distance into the vitreous. There are no signs of retinal or choroidal vessels. Clearly defined, white lines (opaque nerve fibres) radiate from the disc margins, giving the effect of a halo about the central zone of the picture.

A lateral view of the Gecko pecten is seen in Fig. 145; it is suggestive of a similar view of the Apteryx pecten (Fig. 27).

HORNED TOAD. *Phrynosoma cornutum*. Plate LX. Left eye. Erect image. The color of the fundus oculi is a dark slate, irregularly strewn with minute, whitish dots of various sizes. There is an ill-defined *macular region*.

The pear-shaped, grayish *papilla* has a white margin, from which short fibres of unequal length radiate towards the periphery. A single central (?) artery seems to originate from the nervehead and with its six branches — two on one side of the disc, four on the other — is supplied mostly to the lower half of the eyeground. Above, a small branch anastomoses with a twig that runs from the periphery of the field.

INDIAN COBRA. *Naja tripudians*. Plate LXI. Left eye. Erect image. The general *coloration* of the fundus of this Snake is light gray-blue, sparsely dotted with pigment of a similar but deeper color. The whole background is regularly covered with opaque nerve fibres whose radiate disposition reminds one of *Merula* (Plate LVII). From the button-like *optic disc* arise three vessels, apparently two arteries of small size and one (larger) vein. The centre of the papilla shows the remains or the undeveloped tissues of a pecten.

CHAPTER XIII

COLORED DRAWINGS OF THE FUNDUS OCULI OF BIRDS

EFFORTS to duplicate exactly the paintings made by Mr. A. W. Head for this Atlas have been attended by difficulties that have arisen chiefly from the fact that *precise* duplication of minute details and shades of color (of minor importance in the usual forms of color reproduction) were regarded as essential in this investigation. However, these impediments were, after many trials and the exercise of much patience on the part of the publisher's officials, finally removed and the writer now believes that the following plates faithfully represent not only the varied and beautiful coloration but the complex tissue formations revealed by the ophthalmoscope in the ocular background of the avian and reptilian species herein depicted.

For the convenience of the reader a brief description of each fundus drawing has been placed on the page opposite each plate, a more complete description of the ophthalmoscopic appearances, as well as their relations to other fundus views, being given in Chapters IX and XII.

RATITÆ

Struthioniformes

NUBIAN OSTRICH. *Struthio camelus*. Plate I.

The general color of the eyeground is dull red, besprinkled with lighter-red, round dots and gray granules. The lower half of the fundus appears somewhat grayer in tone than the upper sectors. This appearance is probably due to the numerous opaque nerve-fibres that extend from all sides of the papilla as a centre across the fundus to the periphery of the ocular background. The red coloration of the fundus is seen to be more intense towards the upper half of the eyeground. The optic nerve entrance is very broad and oval in shape. The margins of the nerve head are very white and it is possible with the mirror to see all around the pecten. The centre of the disc, including the parts near the root of the pecten, are stippled with minute brown pigment dots, like black pepper grains. The pecten presents the appearance of a number of dull, dark, sepia-brown tubercles. It does not project far forward into the vitreous cavity, while its outlines and contour may be distinguished both above and below the disc. The pectinate margins are formed of round, ovoid projections. The macula is not very striking in appearance, and takes the form of a crescentic arrangement of minute, gray dots. It is seen towards the nasal side of the disc near its upper end.

Rheiformes

AMERICAN OSTRICH. *Rhea americana*. Plate II.

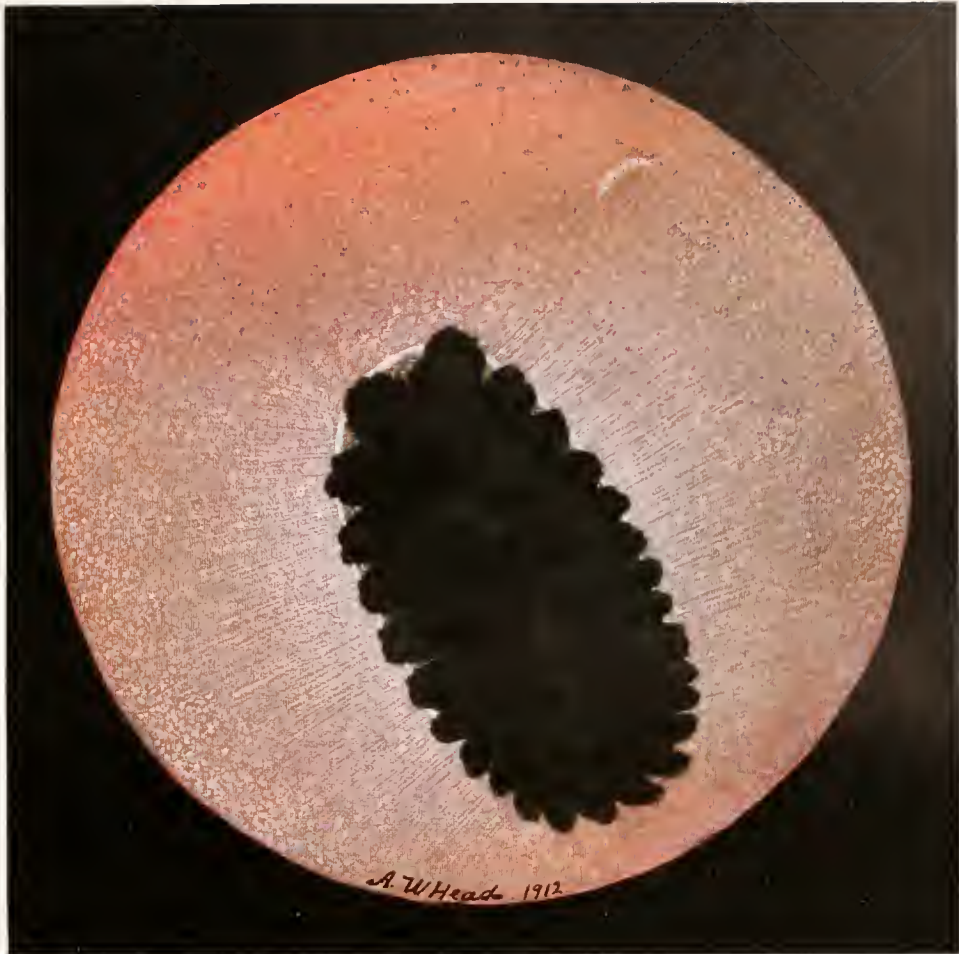The coloration of the fundus as a whole is buff, merging into dull red at the periphery. It is stippled all over with minute dots of a lighter tint.

The optic disc is made up of white and coarse nerve bundles that exhibit a faintly defined, fringe-like border all around its margins. Radiating for a distance of about two disc-breadths across the fundus are a few, dull-gray, opaque nerve fibres that finally disappear into the background.

The macula is situated slightly above and to the nasal side of the optic papilla. It is somewhat grayer than the surrounding eyeground; above (towards the outer side) and below the fovea are a few pale, bright green reflex lines.

The pecten is a massive organ with saw-like margins, the serrations being of a lighter brown than the central body. The lower part of the pecten is somewhat club-shaped, and comes well forward toward the posterior capsule of the lens. Between the projecting teeth of the pectinate serrations may be seen a slight stippling of pigment-like black pepper grains.

RATITÆ



Struthioniformes

PLATE I

Struthio camelus



Rheiformes

PLATE II

Rhea americana

RATITÆ

Casuariiformes

WESTERMAN CASSOWARY. *Casuarus occipitalis*. Plate III.

The fawn-colored eyeground is covered with a minute, silver-gray stipple, in the form of fine, short lines with their long axes running in a vertical direction. As these dotted lines approach the macular region they become more and more convergent until they form a brilliant cluster at the fovea. There is no visible line of demarcation or reflex ring separating this area from the general fundus area. There are no visible choroidal vessels or opaque nerve fibres.

The optic disc is long and boat-shaped, with a reddish, apparently concave centre. It is uniformly sprinkled with darker red dots, which, as they approach the margin of the papilla, are more closely packed, and give the appearance of a shadow cast all about the inner edge of the disc. The margins of the nerve-head are distinctly white, but they have not the "fibrous" appearance seen in most avian backgrounds.

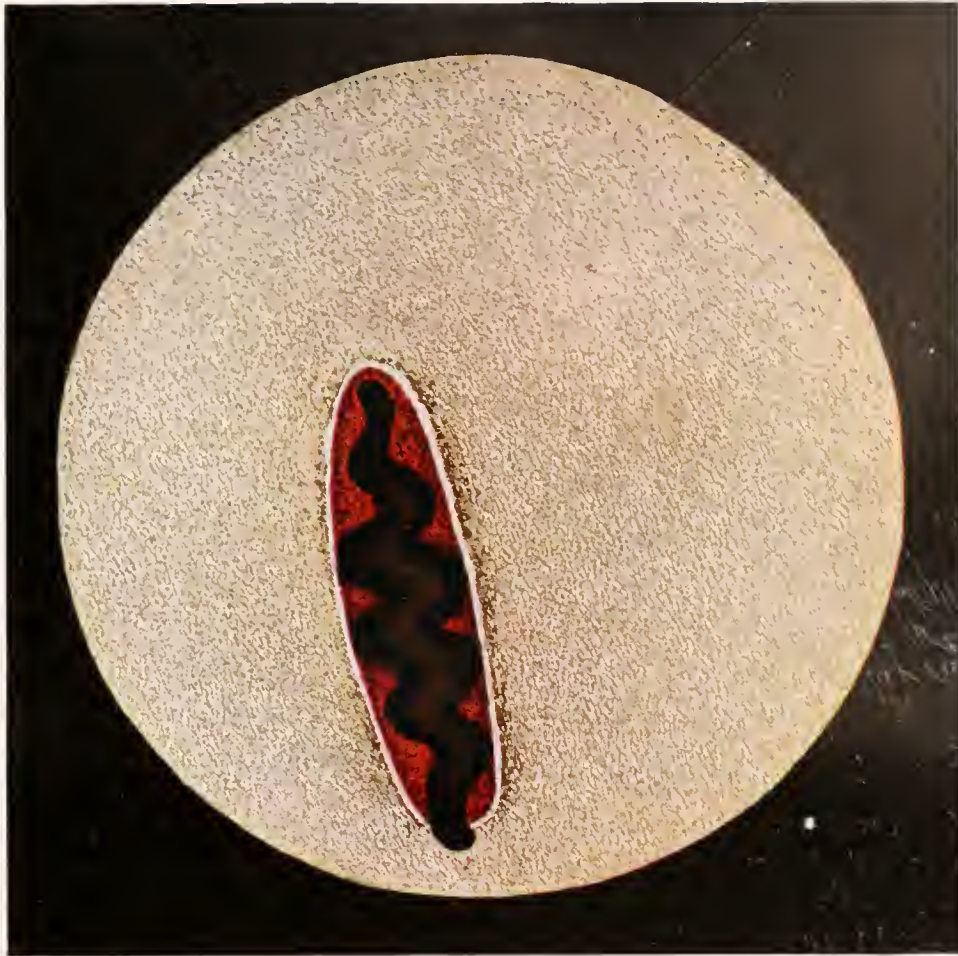The chocolate-brown pecten, much broader at its base than at the apex, resembles a corkscrew, its lateral elevation being not unlike a cockscomb, with its six serrations rounded off at the apex. Two central serrations come well forward towards the lens.

Apterygiformes

MANTELL APTERYX. *Apteryx mantelli*. Plate IV.

The ocular background is uniformly orange-red, somewhat mottled with brown. The brilliant, white, round disc is surrounded by short, opaque nerve-fibre layers not entirely covered by the fenestrated base of the long, large, and conical pecten, whose pointed end reaches almost to the lens. There are no signs of choroidal blood-vessels.

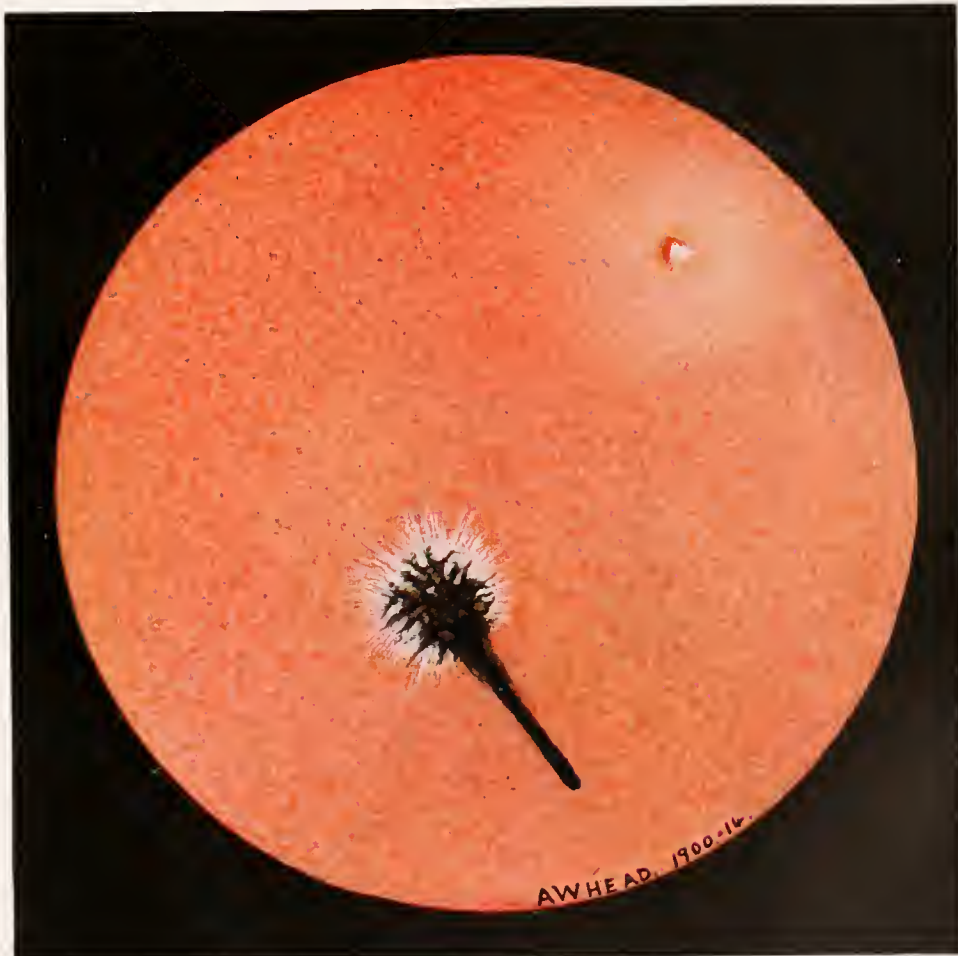RATITÆ



Casuariiformes

PLATE III

Casuarius occipitalis



Apterygiformes

PLATE IV

Apteryx mantelli

AWHEAD, 1900-14

RATITÆ

Tinamiformes

MARTINETA TINAMOU. *Calodroma elegans*. Plate V.

The background coloration is, in the main, a deep gray, the lower half merging into dull orange. The whole of the fundi is covered by a collection of tiny dots packed closely together. In the upper half of the field they are white, but from the region of the disc and downwards they become a dull orange colour. Crossing the fundus and running vertically on either side of the papilla are several orange-red choroidal vessels.

The macula appears as a dull-gray area, with a brilliant white central spot surrounded by a small, and a pale-green, streaked, reflex ring. It is plainly visible on the nasal side of the pecten. The optic nerve is oval in shape and exceptionally broad.

The mass of the pecten almost completely covers the optic papilla, which is quite white and looks like a mass of coarse opaque nerve fibres. The optic margins are bordered with gray pigment, from which spring a few short opaque nerve fibres. The pecten is chocolate brown, and in addition to its massive appearance is much shorter than the same organ in most of the birds examined. It is easy to see that it is fringed all round with pointed tabs, that the central portion or ridge is serrated and that it comes well forward towards the lens.

CARINATÆ

Galliformes


YARRELL CURASSOW. *Crax globosa*. Plate VI.

The eyeground is a dull, leaden gray, covered with tiny, white dots. There are no visible choroidal vessels.

The papilla appears as a long oval, whose central zone is dull orange mingled with minute, dark-brown dots. It also presents a marginal fringe of white. A few opaque nerve fibres extend on either side of the disc across the fundus, but for a short distance only.

The pecten, of spiral form, is colored dark chocolate-brown. It seems to taper quite decidedly where it joins the disc, and looks like the roots of a tree at its distal end, where the rootlets bury themselves in the disc. Just above the disc, some little distance to the nasal side of the pecten, is a round, grey, softly outlined area near which is seen a well marked reflex of a pale blue-green tone.

RATITÆ

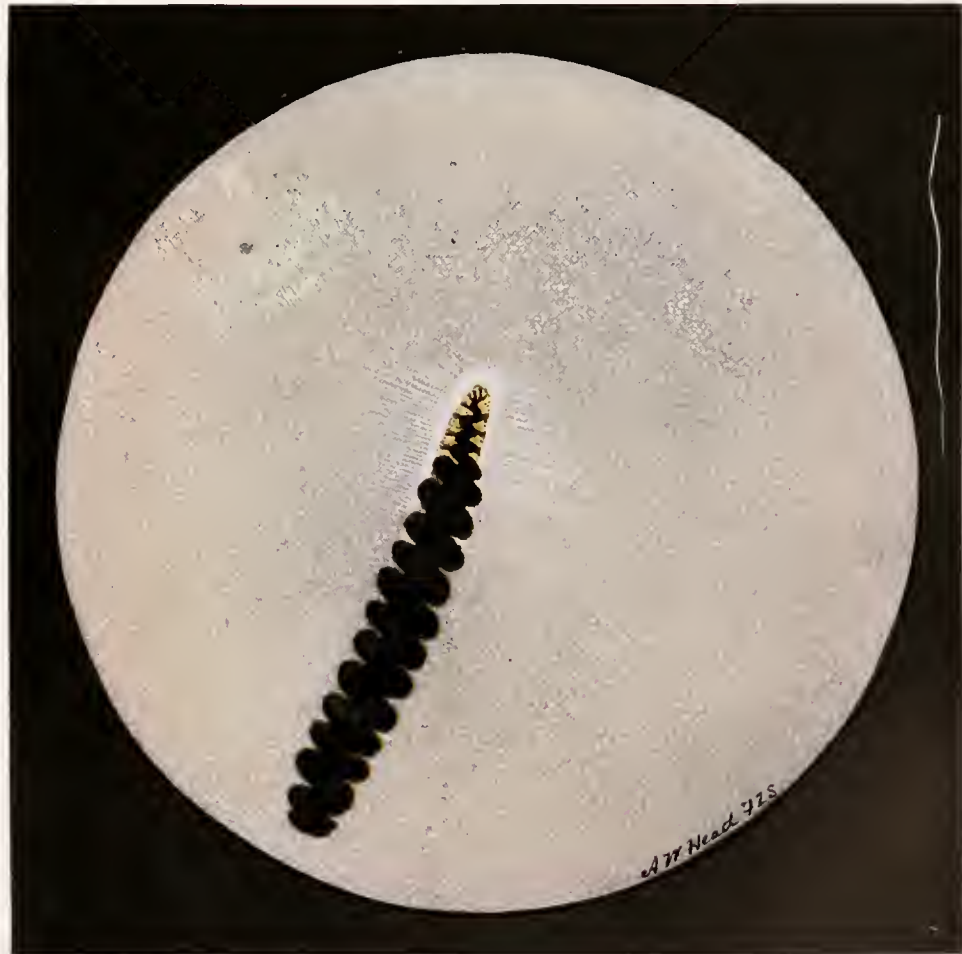

Tinamiformes

PLATE V

Calodroma elegans

CARINATÆ



Galliformes

PLATE VI

Crax globosa

CARINATÆ

Galliformes

BRUSH TURKEY. *Cathartus lathamii*. Plate VII.

The eyeground is dull, slaty gray, underlying numbers of fine, light-gray dots. These dots are uniformly scattered over the fundus except towards the nasal side. Here, on a level with the superior end of the optic nerve and in the direction of the macular area, they are of a more brilliant white, are closely packed together, and are devoid of a reflex-ring.

Extending from either side of the optic disc and running at right angles to that organ are a few, rather fine, semitranslucent nerve fibres, which are lost towards the periphery.

The optic disc, whose upper end is shaped like the sharp bow of a boat, appears to be composed of a mass of brilliant, white, opaque nerve fibres.

The pecten, of the usual chocolate brown color, is massive and somewhat club-shaped. It extends well forward towards the lens and tapers rapidly as it approaches the superior end of the nerve.


HARLEQUIN QUAIL. *Coturnix histrionica*. Plate VIII.

The ocular background is light gray sprinkled with minute granules, which give it the appearance of a rough surface.

The optic nerve head gives one the visual impression that it is formed of brilliant, white, short, coarse, opaque fibres. Its shape is unusual, being long and narrow, with a rather striking resemblance to the projecting, serrated jaws of the Sword Fish. Extending along each side of the optic disc, at right angles to it, are a few rather pale, thin, opaque nerve fibres.

The pecten is lighter brown in color than usual, and is very narrow at its junction with the papilla. On either side of it are a few minute dots of brown pigment. The inferior segment of the pecten forms a corrugated, bulky mass which, however, extends well forward into the vitreous cavity to the posterior surface of the lens.

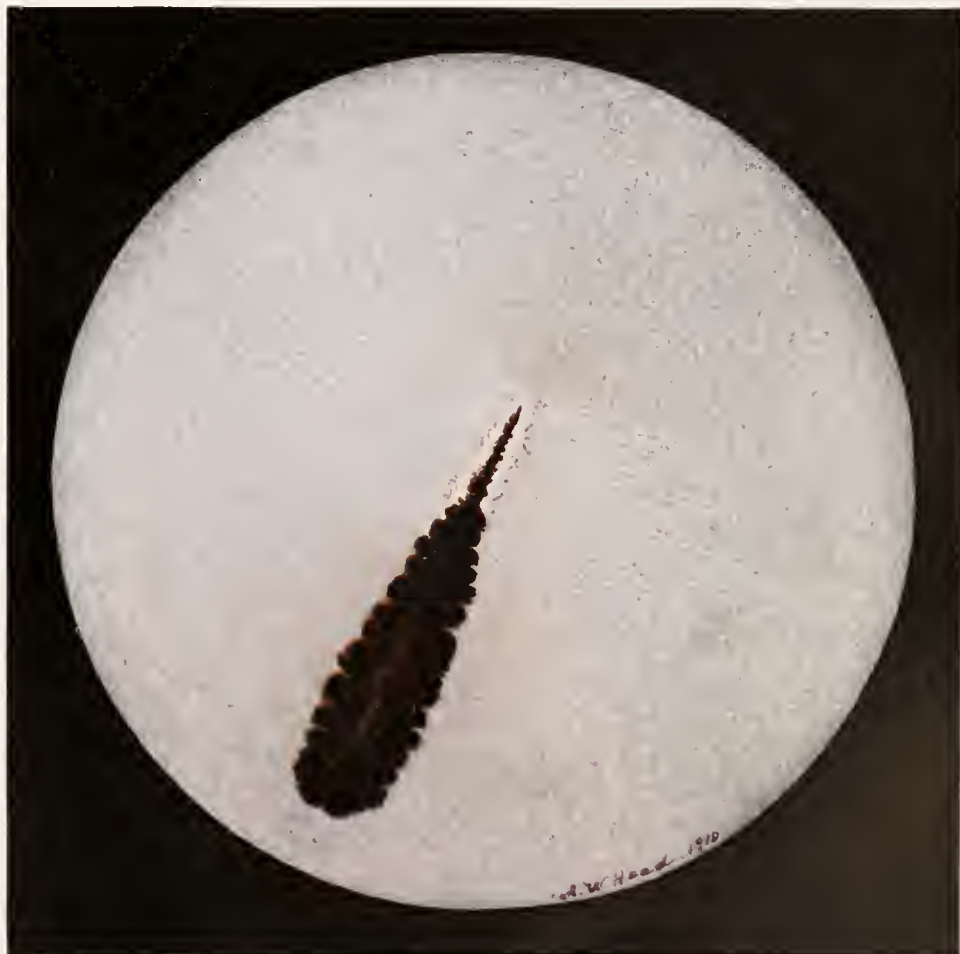CARINATÆ



Galliformes

PLATE VII

Cathartus lathami



Galliformes

PLATE VIII

Coturnix histrionica

CARINATÆ

Columbiformes

WONGA WONGA DOVE. *Leucosarcia picata*. Plate IX.

The ocular background is of a uniformly gray tint. White dots, lighting up the fundus, are scattered over the entire field. A few choroidal vessels are to be seen.

The optic disc forms a long oval; it appears as if it were composed of a collection of white fibres, and these seem bunched together for about one-half the length of the pecten. Opaque nerve fibres radiate from the circumference of the papilla, while several orange-red (choroidal) capillaries, interspersed with pigment dots, run on either side of it.

The pecten appears as an exceptionally long, corrugated, dark-brown mass. Seen through the mirror from above it has the appearance of a piece of tarred rope. The single macular area is seen to the inner side of the disc and a little above its upper end. The sheen of the pale green reflex that plays about it when illuminated by the light of the ophthalmoscope looks like watered silk. The fovea has the appearance of a small green flare, something like that from a bull's eye lantern seen close at hand.

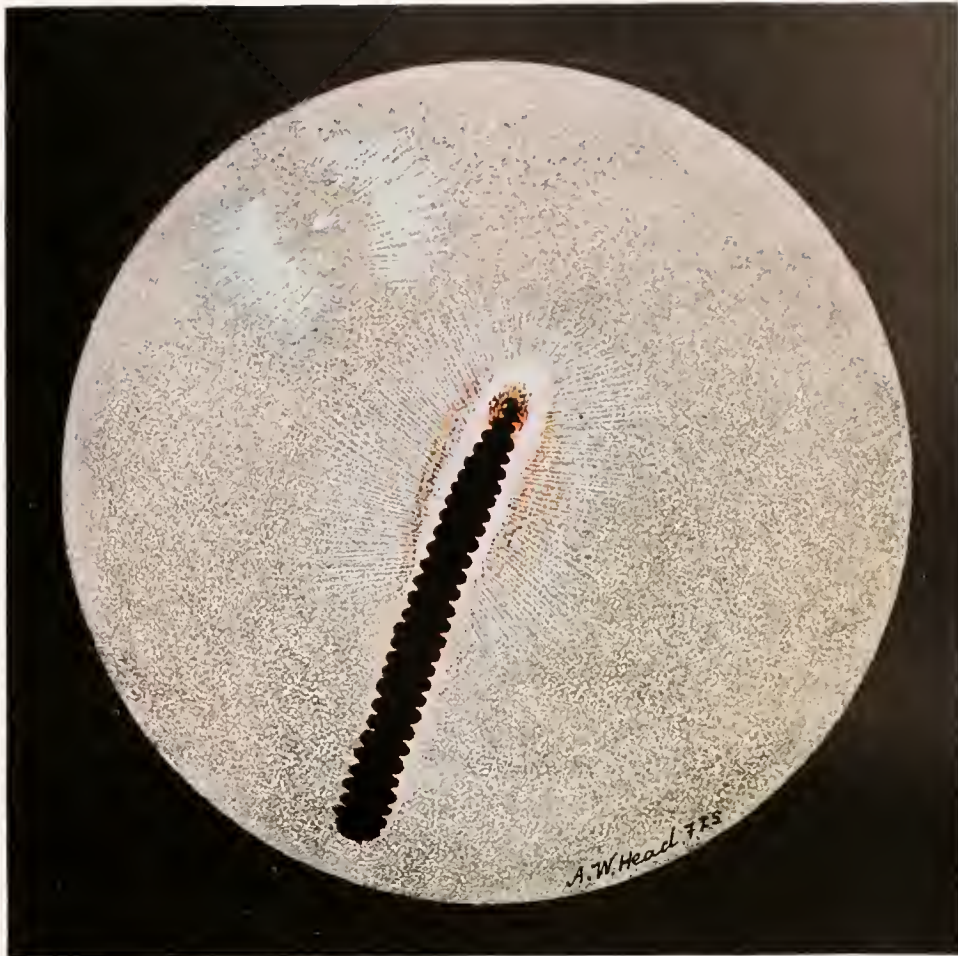EUROPEAN WOOD PIGEON. *Columba palumbus*. Plate X.

The tint of the ocular background is pale slate-gray. The eye-ground is covered with very small, dull-white dots, so that the whole fundus presents a lighter shade of gray than it otherwise would. On the lower half and each side of the optic disc are seen several orange-colored choroidal vessels, which become more numerous as one approaches the periphery. Extending at right angles to the papillary margin are a few opaque nerve fibres.

A little above the superior end of the optic nerve head and towards the nasal side, is a small, round, apparently somewhat depressed macular area of a dull-gray tone. From its margins run a double row of fine, blue-green, translucent lines which form about it a broken or irregular reflex ring. The bird becomes unusually restless when the light from the ophthalmoscopic mirror is focused on this part of the fundus. The optic disc appears of a dead white color, and seems to have a fringe of short fibres of the same color all about its edges. At the junction of the pecten with the nerve-head, i. e., along the central area of the latter, one sees numerous brown pigment dots that appear like small rootlets or capillaries and give a reticulate appearance to the papilla.

The pecten itself has a dark chocolate-brown color and a corkscrew contour; it is unusually long and narrow, and its lower segment appears to come well forward towards the lens.

CARINATÆ



Columbiformes

PLATE IX

Leucosarcia picata



Columbiformes

PLATE X

Columba palumbus

CARINATÆ

Columbiformes

VICTORIA CROWNED PIGEON. *Goura victoria*. Plate XI.

This fundus oculi is of the gray color, seen generally in pigeons and doves, and covered with minute white dots. On the upper and nasal side of the fundus is the macula, a small dull-gray area surrounded by a gray and green reflex of small lines. The optic disc is long, narrow, boat-shaped and somewhat rounded at the upper end. It looks as it were rather hollow and gray in the centre with a white rim all around. A network of small, brown, pigment dots is disposed along the centre on either side of the pecten; and some opaque nerve fibres extend across the fundus on all sides of the nerve.

The pecten is of the usual dark chocolate tint. It is corkscrew-like in appearance, but one end is rather club-shaped and looks as if it were covered with small brown nodules. This segment comes more prominently forward towards the lens.

Ralliformes

CRESTED COOT. *Fulica cristata*. Plate XII.

The predominant color of the eyeground is dull gray, everywhere sprinkled with minute, white dots that are more clearly seen above the superior termination of the optic nerve and to the nasal side of the pecten.

The long optic disc is white, with a few tiny pigment dots about its margins. The pecten is lighter brown than in the majority of birds; it is very large, almost hiding the disc from view. Many opaque nerve fibres radiate from the papillary circumference and extend several disc breadths across the fundus.


CARINATÆ



Columbiformes

PLATE XI

Goura victoria



Ralliformes

PLATE XII

Fulica cristata

CARINATÆ

Ralliformes

IPECAHA RAIL. *Aramides ipecaha*. Plate XIII.

The eyeground is a very pale uniform gray stippled with darker gray and white dots, thus giving the whole field a granular appearance. The horizontally oval macular area (on the nasal aspect near the upper end of the disc) assumes a pinkish tone. At its centre is a small pit with a brilliant, white central dot. Around the macular region is a pale, blue-gray reflex which loses itself in the general tone of the fundus, but appears quite sharp on the inner side of the oval macular region. The disc is a narrow, white oval, whose length is about one-third the height of the pecten. A number of opaque nerve fibres run across the background at right angles to the papilla and fade into the general gray of the fundus. The pecten arises from the upper part of the disc, spreads out on it like the root of a tree and gradually disappears into the papillary substance. From this root a long, slender, spiral form projects into the vitreous. It is brown in color, is of uniform width, looks like a corkscrew and extends forwards and outwards as far as the eye can see, looking as if it were pressed against the lower part of the lens. The anterior end of the pecten is much darker in color than its posterior half.


Sphenisciformes

BLACK-FOOTED (CAPE) PENGUIN. *Spheniscus demersus*. Plate XIV.

The dominant color of the fundus is bright red shading to crimson. It is stippled with minute, dark-red and orange dots, much like grains of sand. About a disc-length from the upper end of the optic disc these dots become grayish-white; indeed, the fundal coloration is distinctly gray towards the upper half of the eyeground. In a region the same distance towards the temporal aspect of the background may be seen a cluster of pinpoint, brilliant, white dots in the macular area. Penguins use the nictating membrane very frequently when light is thrown on this part of the eyeground. The optic disc exhibits enamel-white edges; it is hollowed out in the centre, like a sewing-machine shuttle. Running across this concavity and at right angles to the margin of the disc one sees a large number of gray fibres.

The pecten lies along the centre of the nerve, where it is orange-red in color and mottled with minute, brown pigment dots. The pecten has the usual dark chocolate-brown shade. It is of spiral form, like a corkscrew laid on its side. A few slender opaque nerve fibres are visible on each side of and at right angles to the disc.

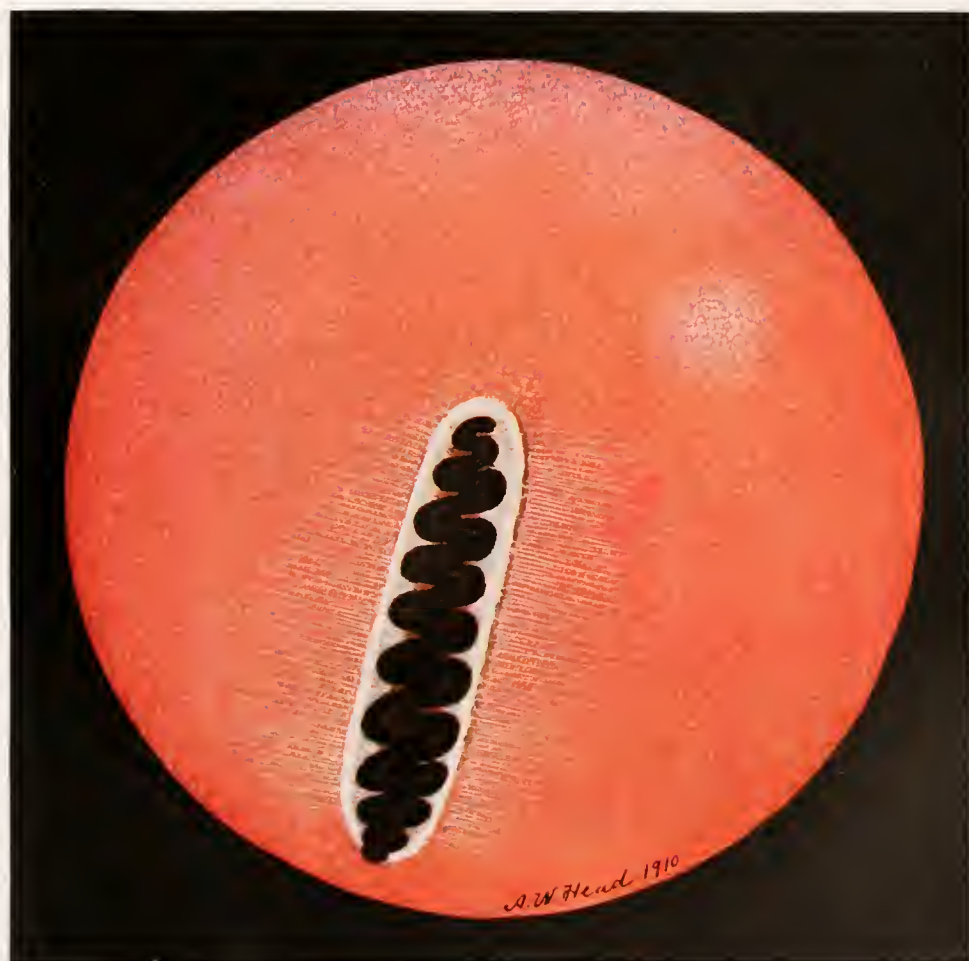CARINATÆ



Ralliformes

PLATE XIII

Aramides ipecaha



Sphenisciformes

PLATE XIV

Spheniscus demersus

CARINATÆ

Alciformes

PUFFIN. *Fratercula arctica*. Plate XV.

The eyeground is red and rather uniformly stippled with small, mixed light-red and dark-gray dots. Above the upper end of the optic disc and towards the temporal side is a small, round, red area surrounded by a pale, light-gray film, shot with bright lines on the outer and inner margins — doubtless the macular region with its central fovea. Head noticed that not only this area but most of the upper half of the fundus is very sensitive to light. The optic papilla, oblong, narrow and with a rounded upper extremity, lies low down in the eyeground, while the pecten extends well forward and behind the lower margin of the pupil. A view of the nervehead is much obscured by the body of the massive pecten which almost covers it when seen, as with the mirror, from above downward. The small segment visible with the ophthalmoscope appears not brilliant white but rather a bluish-white, the margins of the pecten being covered with black pigment.

Extending at right angles to the disc on both sides are a few very fine, gray opaque nerve fibres that finally disappear in the fundal periphery. The pecten is of the usual chocolate-brown color and comes well forward towards the lens, especially in its inferior aspect.

Lariformes

GREAT BLACK-BACKED GULL. *Larus marinus*. Plate XVI.

The general coloration of the eyeground varies from a dull gray to a dull brown — mostly the latter — traversing which are many reddish choroidal vessels running more or less in a vertical direction. It is the number and visibility of these capillaries that give the red tone to an eye-ground essentially gray.

The optic disc is a long, narrow oval, quite white, with a quantity of fine gray lines radiating in all directions from the papillary margin. On the inner aspect of the eyeground the macula is seen. It is situated about one disc-length from the upper extremity of the pecten and half a disc-length above the end of the same organ on the inner side. The macula resembles a blue-green flake of iridescent glass. It is of oval shape with a reddish-brown center, which, however, is unprovided with a reflex ring.

The pecten appears to be in folds; the lower, or broader portion extends well forward towards the lens and turns towards the nasal side of the bird's head. The inner quadrants of the fundus are more easily seen with the ophthalmoscope than the outer half but, so far as the latter area is visible, there is no sign of a second macula on the outer part of the eyeground.

CARINATÆ



Alciformes

PLATE XV

Fratercula arctica



Lariformes

PLATE XVI

Larus marinus

CARINATÆ

Charadriiformes

STONE PLOVER. *Ædicnemus scolopax*. Plate XVII.

The eyeground is reddish-brown, rather deeply pigmented near the periphery and covered with orange-red dots that are very densely packed on the upper half of the fundus. Below the optic entrance are numerous choroidal vessels running parallel with and on either side of the papilla. The macula is not clearly defined. It is situated above the superior end of the disc on its inner or nasal side, and about half the apparent length of the pecten from the upper end.

The fundus coloring is slightly darker in the macular area, which is surrounded by a reflex ring, pale gray in color, in the form of very minute lines radiating from its margins. There are, also, a few radiations near the fovea centralis. The papilla is white, oval in shape, fringed all round with dense black pigment, and a few gray, opaque nerve fibres are seen on either side of it. The pecten is very large and projects well into the vitreous. It is of unusual shape, rather narrow, but when examined from above looks as if it had been compressed and flattened on both sides, with a narrow edge above.

Gruiformes

KAGU. *Rhinochetus jubatus*. Plate XVIII.

The background is covered with a mass of minute dots that are gray in the upper half of the fundus and orange below. The lower sectors of the fundus are stippled with pigment. Choroidal vessels are numerous and run in rather straight, vertical lines on both sides of the optic disc. They are dull orange in color. The fovea is shown towards the anterior or nasal half of the retina, and appears as a round hole or crater-like depression, brown in color, which reflects a grayish sheen from its centre. A narrow gray circle or reflex ring surrounds this pit.

The optic disc has its central portion apparently stippled with bright orange-red dots, while its margin is fringed with coarse, white fibres, that are also studded with brown pigment dots, especially near the outer border.

* The pecten is of the usual, deep chocolate-brown color, rather narrow where it joins the disc but becoming much thicker and more massive as it projects into the vitreous towards the lens.

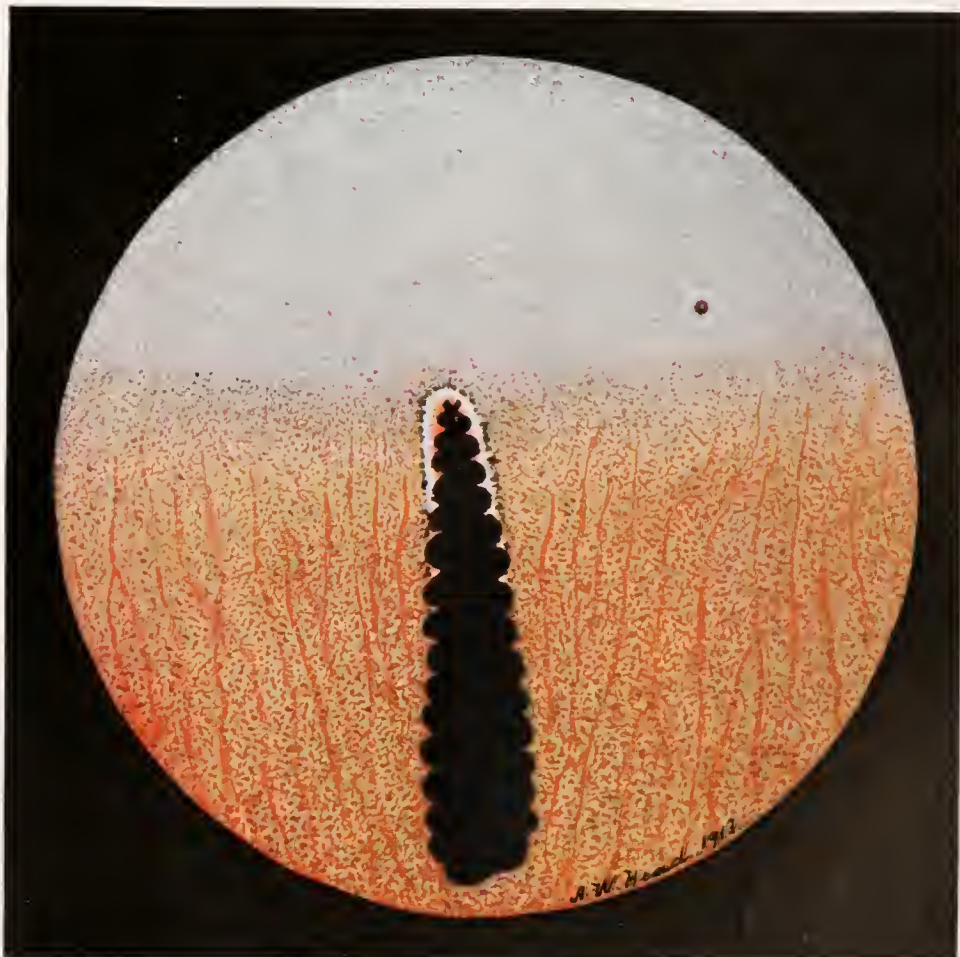
CARINATÆ



Charadriiformes

PLATE XVII

Edicnemus scolopax



Gruiformes

PLATE XVIII

Rhinochetus jubatus

CARINATÆ

Gruiformes

BRAZILIAN SERIEMA. *Cariama cristata*. Plate XIX.

The dominant color of the fundus oculi is a dull-drab. Over the lower quadrants of the eyeground run rather straight, dull-red, choroidal capillaries that fade away as they reach the upper half of the field. This region is also shot with a greenish-blue, muslin-like film, which is probably a reflection by the retina of light rays from the ophthalmoscopic mirror. Above the end of the disc is a small, round depression, quite clear of any reflex. To the inner or beak side of the eye is the circular macula, whose diameter is about three times that of the cavity at the end of the disc. The centre of the larger circle is quite clear, with the exception of a bright shimmer, such as is sometimes seen about the human fovea. The circumference of this circle is sharply defined, and has a bright ring around it of glistening white. The optic disc appears as a long white oval, with irregular margins. The black-brown corrugated pecten is very large and long; it extends into the vitreous and almost touches the lens with its club-shaped terminal. Very fine opaque nerve fibres radiate at regular intervals from the whole papillary circumference.

Ardeiformes

EUROPEAN NIGHT HERON. *Nycticorax nycticorax*. Plate XX.

The eyeground is dull gray and covered with grayish-white dots. The lower part of the fundus exhibits a number of dull-red choroidal vessels, that run in a vertical direction.

The optic disc is long and of medium width, with both extremities rounded. Its centre is orange-red and covered with minute, brown pigment dots. The pecten is deep brown and its outlines are well defined the whole length of the papilla. Linear, grayish radiations extend from the upper two-thirds of the optic entrance.

The macula is situated quite close to and towards the upper-nasal aspect of the disc. It is surrounded by an outer ring of whitish lines, towards whose centre is a zone that closely resembles the surrounding retina. In its exact centre, again, is a small fovea composed of gray-white striæ.

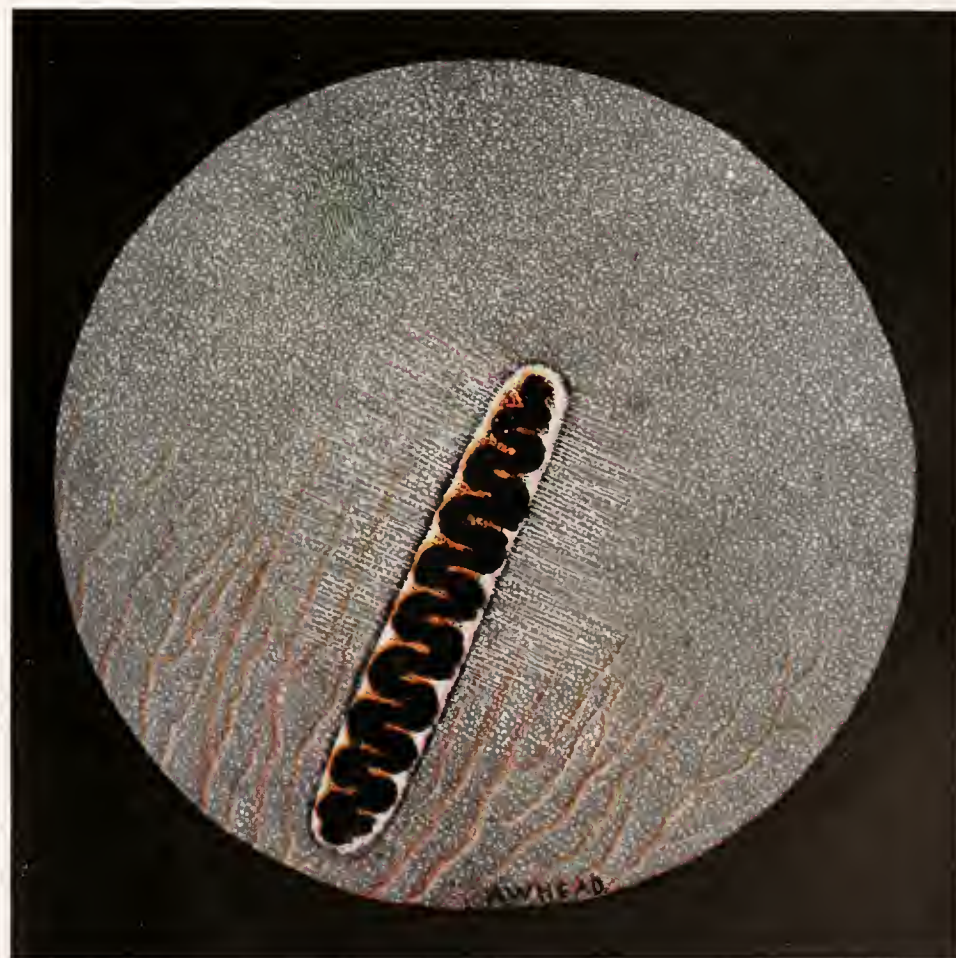CARINATÆ



Gruiformes

PLATE XIX

Cariama cristata



Ardeiformes

PLATE XX

Nycticorax nycticorax

CARINATÆ

Ardeiformes

EUROPEAN BITTERN. *Botaurus stellaris*. Plate XXI.

The eyeground, mostly mouse-colored shading to yellow, is sprinkled with small, dull-white dots. Almost immediately above the upper end of the optic nerve entrance and towards the nasal side of the disc is the macular area. The fundal dots at this point are much duller in tone and incline towards a dull buff color. The region of the macula, enclosed by two circles, one within the other, is also characterized by the presence of very short, bright, bluish-green lines radiating from the centre of the fovea.

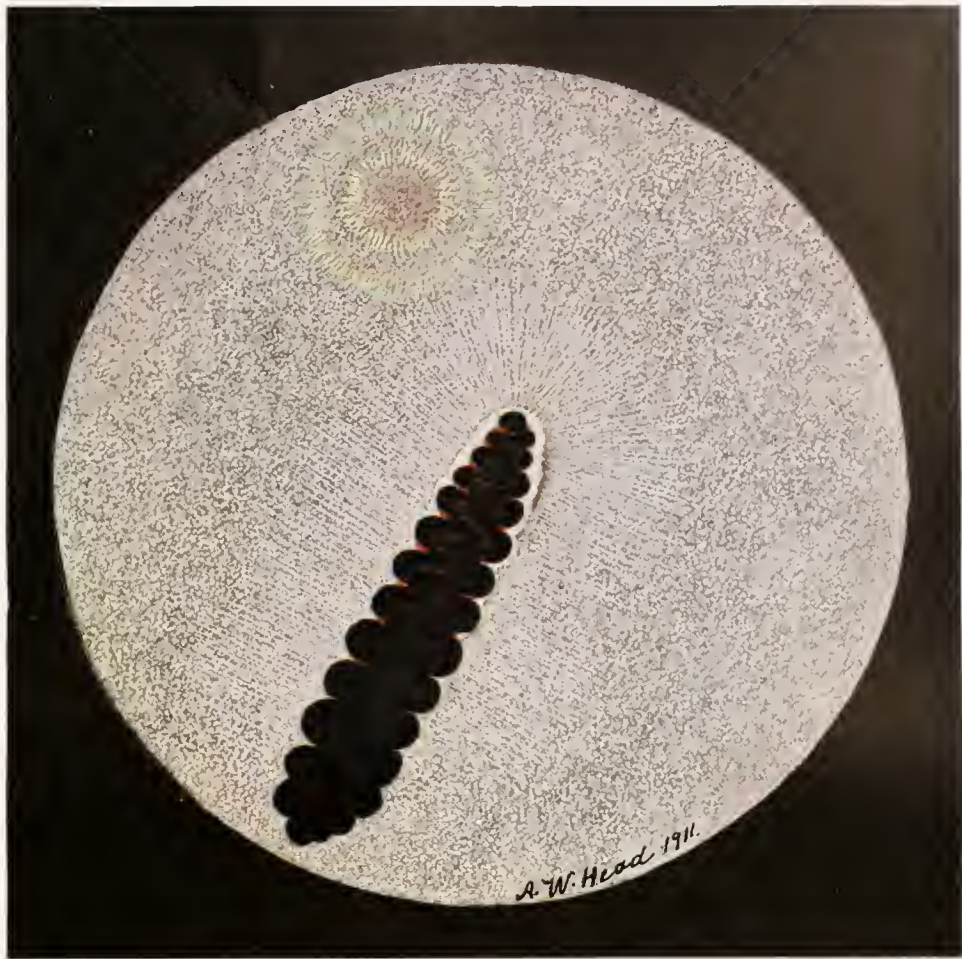
The optic disc is ovoid, blunt at its upper extremity, and appears as if its longer margins describe a series of small curves corresponding to the folds of the pecten. The disc on either side of the root of the pecten is dull-brown; near by are small, orange-red choroidal capillaries. The papillary margins are quite white and, in contrast with the shadow cast upon the neighboring field by the dark pecten, the disc stands out in sharp contour. Extending a short distance over the fundi and about the optic disc are a few opaque nerve fibres. The pecten, convoluted, with serrated margins, and of the usual chocolate-brown color, extends below the lower end of the optic disc.

BOAT-BILLED NIGHT HERON. *Cacromya cochlearia*. Plate XXII.

The eyeground is dull-red and covered with orange-red dots. These punctate deposits are intermixed on the upper half of the fundus with smaller and brighter dots of a grayer tone. On the lower half and on each side of the optic nerve are a few orange-red choroidal vessels, that run in a vertical direction, parallel to the long axis of the disc. The macula is situated towards the nasal side of the nerve head. This sensitive area is rather brighter in color than the surrounding field, and several white dots are included in it. These small dots, however, are noticeable only when the light of the mirror is reflected on the region in certain directions. Rather a bright, irregular and linear reflex surrounds the macular region, which is very sensitive to light. There is a long, narrow papilla with rounded extremities. It appears as if it were composed of short, white fibres, surrounding an orange-red centre covered with minute, dark-brown pigment grains that form a network over the whole red area. Extending from each side of the disc across the retina are a few dull-gray, opaque nerve fibres.

The pecten can be traced the whole length of the disc; it is dark brown in color and grooved spirally like a corkscrew. It does not appear to come far forward towards the lens, and its union with the nerve head can readily be traced.

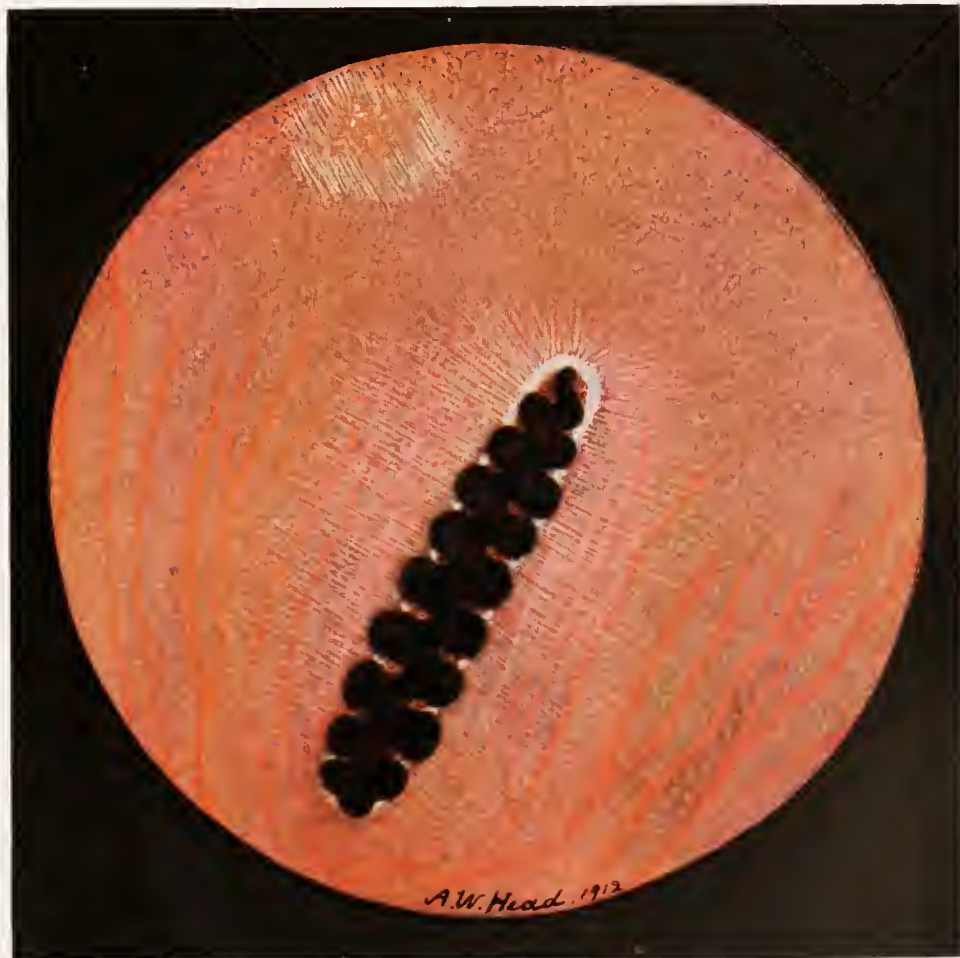CARINATÆ



Ardeiformes

PLATE XXI

Botaurus stellaris



Ardeiformes

PLATE XXII

Canceroma cochlearia

CARINATÆ

Ardeiformes

GLOSSY IBIS. *Plegadis falcinellus*. Plate XXIII.

The general color of the eyeground is blue-gray. It is covered by a mass of minute, grayish dots, that probably furnishes the light but brilliant gray tone that appears when the rays reflected by the ophthalmoscope are thrown on it. The inferior quadrants of the fundus, including both margins of the optic disc, exhibit a large number of orange-red choroidal capillaries. They are very numerous below the nerve-head, and suffuse the whole fundus near the periphery with an orange-pink glow.

Apparently there is but one macular area, situated above the disc and on its nasal side. In the centre of this region is a small, white, round dot, surrounded by a brilliant blue-green reflex. There are, also, fine fibres radiating from the centre of the fovea.

The papilla seems to be formed of a mass of coarse, white fibres. It can be traced for about half its length only, the lower part being obscured by the massive, club-shaped pecten. The latter organ, of the usual chocolate-brown color, projects well forward towards the posterior aspect of the lens. The disc is bordered with black pigment which resembles a shadow cast on the eyeground. A large number of semi-translucent nerve fibres originate at the edges of the optic nerve on all sides, extend across the choroidal vessels and eventually disappear.

AMERICAN JABIRU. *Mycteria americana*. Plate XXIV.

The general color of the fundus is a slate-gray, the whole eyeground being quite uniformly sprinkled with small, but variously sized white dots. In the upper and nasal quadrant of the picture is the small, single macula, an area darker than the surrounding parts, whose exact centre is occupied by the fovea. In the lower two-thirds of the field are seen numerous, plainly marked choroidal vessels that extend the whole length of the pecten, converging somewhat towards the posterior aspect of its base. About two-thirds of the long and rather broad nerve-head is plainly visible, except the central portion, which is partly obscured by the pecten. This large, black-brown organ, divided into 15 large and several much smaller double folds, terminates above in a thin, dark rod. The disc is fringed by dark pigment grains and from its lateral margins project a number of short, faint, whitish lines.

CARINATÆ



Ardeiformes

PLATE XXIII

Plegadis falcinellus



Ardeiformes

PLATE XXIV

Mycteria americana

CARINATÆ

Ardeiformes

SPOONBILL. *Platalea leucorodia*. Plate XXV.

The color of the eyeground is decidedly gray, becoming brownish towards the periphery. The entire fundus is covered with minute, irregularly shaped, gray-white dots, that appear more distinct about the macular region. At the fovea, where they are brilliant white, they are still more closely packed. The foveal region appears to be sunken below its surroundings and to be enclosed in a pale, greenish (reflex) ring that is of oval shape, with its long axis horizontal. The optic disc is a long, narrow oval, and presents a brilliant white appearance. Near its upper end are several choroidal vessels of a pale, golden-yellow color. Parallel to the long axis of the nerve-head is another elongated mass of white fibres (almost like a second optic disc) having its centre stippled with fine pigment dots, and extending across the eyeground. Radiating from the margins of the papilla one sees a number of faint, translucent fibres crossing the small white area on the nasal side of the nerve.

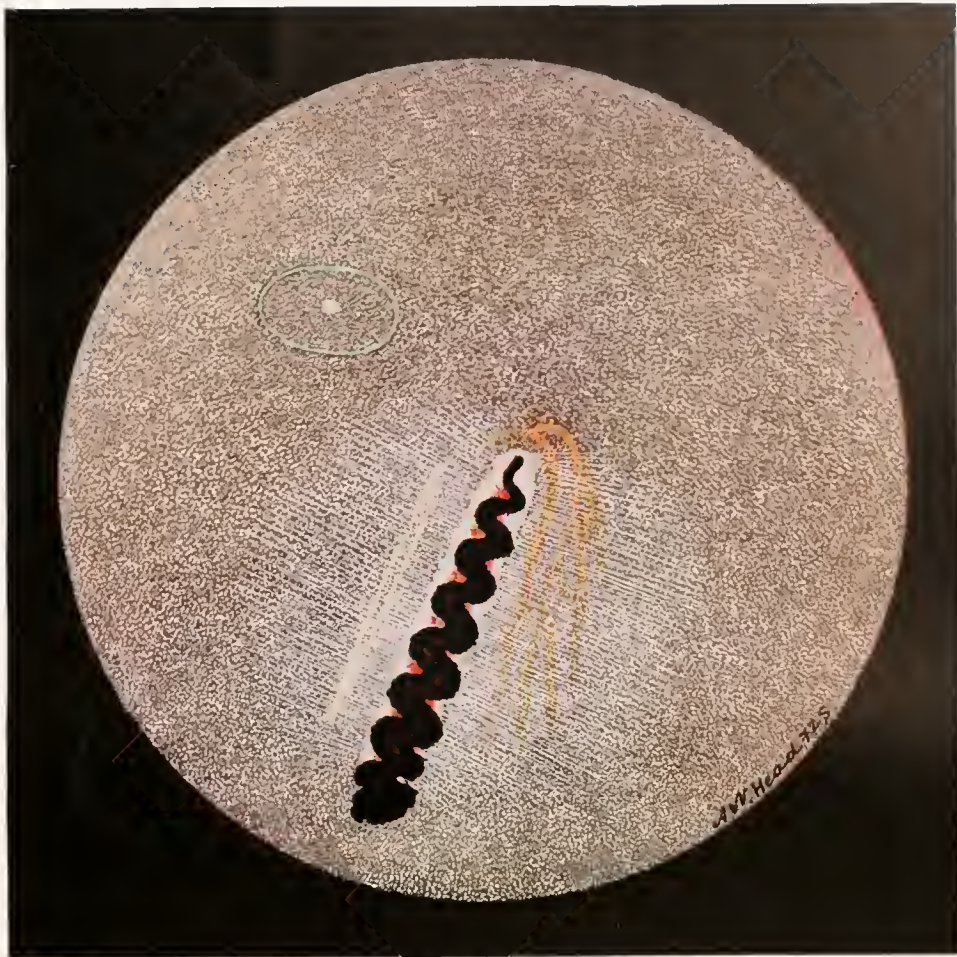
The pecten does not extend very far forward; it is dark gray-brown and appears to be completely covered with a number of warty protuberances. It appears to be attached to the whole length of the centre of the disc, that is stippled with fine red dots.

Anseriformes

BLACK-BELLIED TREE DUCK. *Dendrocygna autumnalis*. Plate XXVI.

The eyeground is colored a light fawn besprinkled with minute, white dots, that glisten when a strong light from the mirror is thrown upon them. On each side of the papilla is seen a number of choroidal vessels, bright orange in color and rather straight. The disc is also orange-red along its major axis, this central zone being stippled all over with a network of fine black dots. The circumference of the disc is fringed with white fibres. The dark-brown pecten arises, as usual, from the whole length of the disc. Viewed from above it seems very thin and twisted like a corkscrew. A few opaque nerve fibres extend for a short distance and at right angles to the disc on either side. The upper part of the fundus is almost obscured by numerous minute, brilliant, white dots.


CARINATÆ



Ardeiformes

PLATE XXV

Platalea leucorodia



Anseriformes

PLATE XXVI

Dendrocygna autumnalis

CARINATÆ

Anseriformes

BLUE SNOW-GOOSE. *Chen caerulescens*. Plate XXVII.

The fundal color is a distinct fawn, sprinkled with small, round, orange-pink dots of irregular shape and size. Running vertically past and parallel with the optic papilla, over the lower half of the fundus are numerous, straight orange-red choroidal capillaries.

The fovea is probably indicated by a small, glistening white dot above the end of the disc on the nasal side.

The optic nerve head is boat-shaped, tinted orange along its central zone, and shows a narrow rim of coarse opaque nerve fibres that form a fringe about its circumference. This orange centre is sprinkled with numerous minute, dark-brown or black dots. A few gray opaque nerve fibres arise from the disc margins and cross the fundus horizontally. The pecten, of corkscrew shape, runs the whole length of the disc and comes well into the vitreous.

Pelecaniformes

CORMORANT. *Phalacrocorax carbo*. Plate XXVIII.

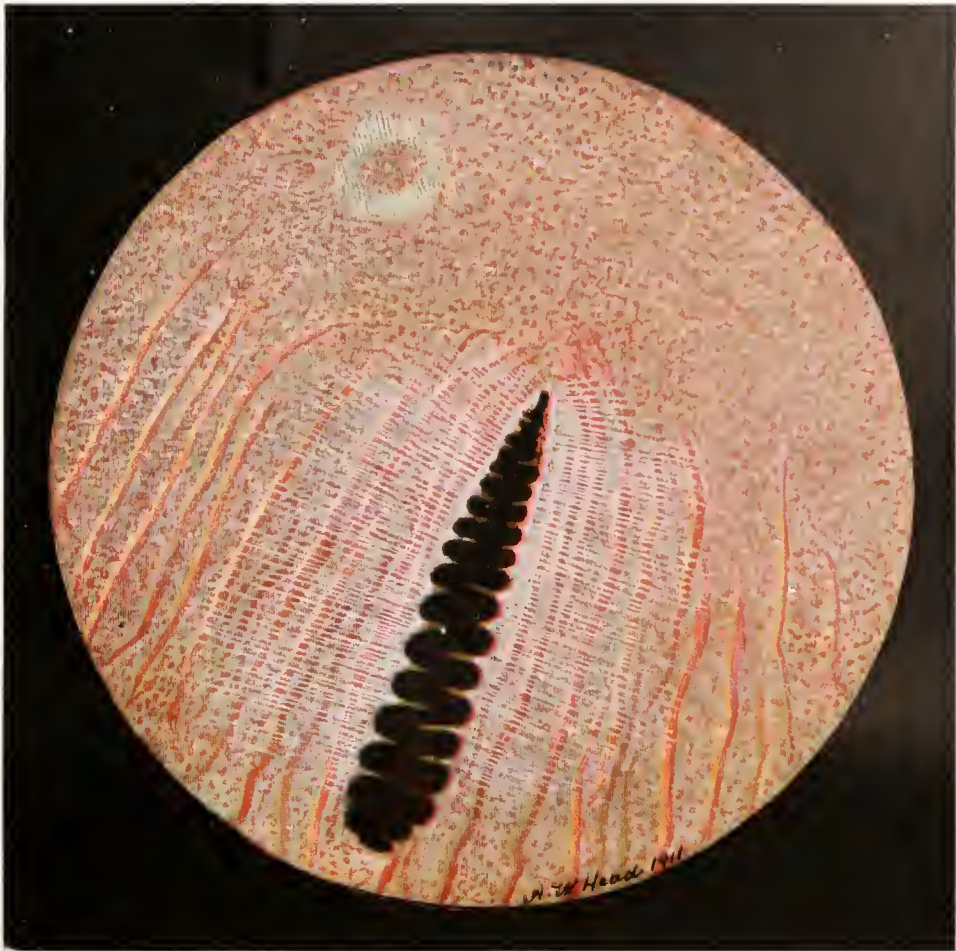The fundus oculi is mostly of a slate-gray color, uniformly sprinkled with numerous, minute white dots, closely packed together. Running chiefly parallel with the long axis of the optic disc are several rather straight, orange-red choroidal capillaries, that extend the whole length of the papilla and beyond its inferior extremity.

The macular area is seen a little above the upper end of the optic disc and on the nasal side of the nerve. The fovea appears as a reflex image of a few short, bright, white lines surrounded by a narrow ring.

The optic disc appears as if it were composed of a mass of very white, cotton-like fibres, disposed as a fringe all about the papillary margin. The central area of the disc, especially on each side of the root of the pecten is orange-red, stippled with minute, brown pigment grains. Perpendicular to the papillary margins are a few short, fine opaque nerve fibres, that run towards and are finally lost in the peripheral eyeground.

The pecten is rather long and of the usual chocolate color; it is much narrower than usual on the upper half of the disc, and comes well forward into the vitreous humor, extending behind the margin of the pupil.

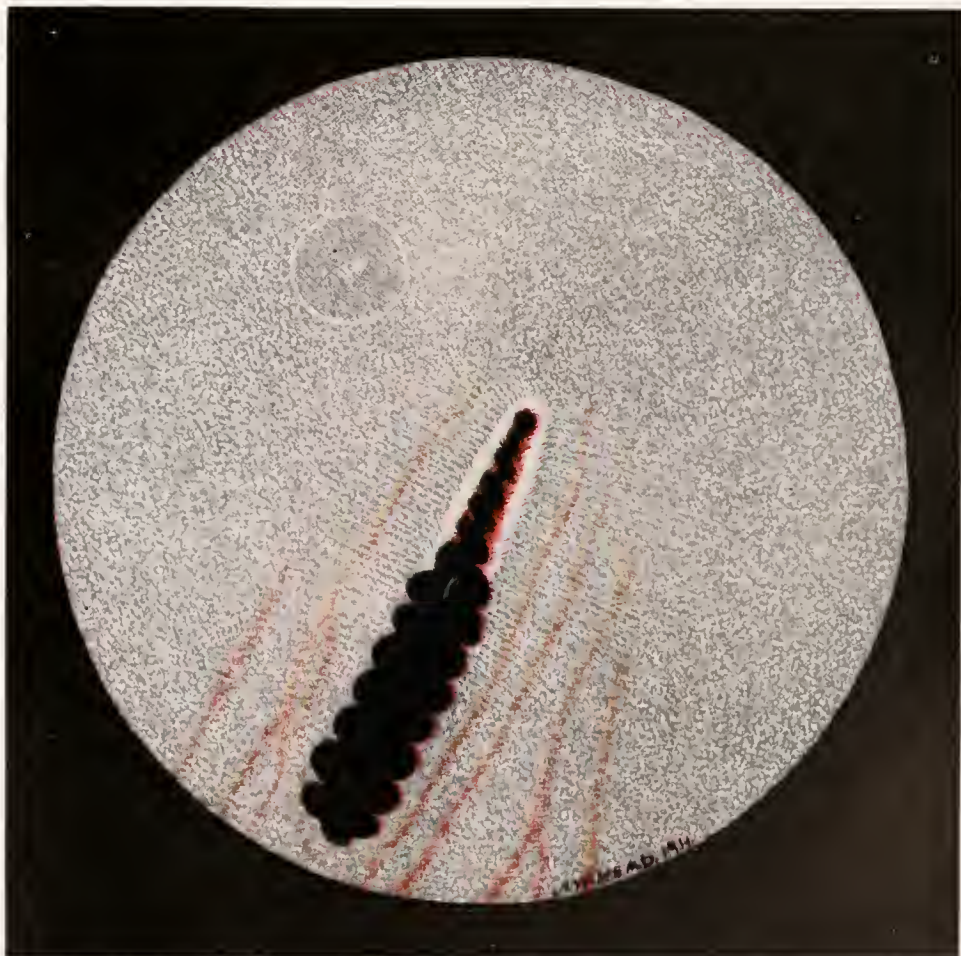
CARINATÆ



Anseriformes

PLATE XXVII

Chen carulescens



Pelecaniformes

PLATE XXVIII

Phalacrocorax carbo

CARINATÆ

Pelecaniformes

GANNET. *Sula bassana*. Plate XXIX.

The general color of the eyeground is dull yellow with a gray tint, everywhere covered with light gray dots, that are most numerous on the upper half of the fundus. Below, and on each side of the optic nerve, are several orange-red choroidal vessels, that are fairly straight and run parallel with the long axis of the disc.

The nerve entrance and pecten are situated rather high up in the field; consequently it is easy to examine the details of the peripapillary background.

Above the upper end of the optic disc and a little towards the nasal side, is a small circular macular area, red in tone but surrounded by a larger circle, like a gray shadow. The margins of the latter gradually fade into the background. The visible margins of the papilla, apparently composed of coarse, white, opaque fibres, are not, as in many species, covered by the pecten. The central part, near the root of the pecten, is orange-red in color.

The pecten itself is evidently attached to the disc for nearly its entire length, and it does not come forward towards the lens.

AUSTRALIAN PELICAN. *Pelecanus conspicillatus*. Plate XXX.

The color of the eyeground is a dull but deep gray, sprinkled generally with irregular dots that are most numerous in the upper part of the fundus. The lower quadrants of the field are covered with a rather faint orange-red, choroidal capillary system, disposed in a vertical direction. The disc is a wide, pointed oval, exhibiting a number of bright-red orange ridges that are uniformly stippled with black pigment dots. The disc margins stand out as a clear white. The pecten, broad and massive, seems to fill the pupillary area. It projects far into the vitreous, reaching, indeed, the posterior surface of the lens. In spite of its large size and intraocular disposition both the free and the attached ends of the pecten can be outlined by the ophthalmoscope. Passing in a radial direction from its circumference is a number of opaque nerve fibres.

The single macula is to be found on the inner side of the fundus. It is surrounded by a narrow, sharply defined, reflex ring of greenish color.

CARINATÆ



Pelecaniformes

PLATE XXIX

Sula bassana



Pelecaniformes

PLATE XXX

Pelecanus conspicillatus

CARINATÆ

Serpentariiformes

SECRETARY BIRD. *Gypogeranus vel Serpentarius serpentarius*.
Plate XXXI.

The general color of the eyeground is dull gray, pitted with mixed light and dark brown pigment grains or dots, the darker being about double the size of the lighter granules. Mixed with these dots is a dense mass of minute, bright points that cover the whole fundus, but they can be observed only when the reflected light of the mirror is thrown on them. These deposits give the background the appearance of a rough surface. A thin layer of translucent nerve fibres surrounds the papilla for a short distance, particularly along the long axis of the nerve-head.

A little above the upper end of the optic disc and towards the nasal side is the *fovea centralis*, a round white dot enclosed by a narrow ring of bright green. On the temporal side of the disc, and above the end of it, is also a long, narrow, sensitive area. This part is enclosed by a shimmering reflex of green light.

The optic disc is long and rather narrow, both ends being rounded off. It is quite white and deeply pigmented at its outer and upper borders.

The pecten is of a lighter brown than usual, is plainly serrated on either side and appears as a narrow band that extends the whole length of the disc. Just before its junction with the optic nerve-head it is stippled with bright, orange-red grains. The central part of the pecten does not project far forward into the vitreous; it appears to be quite narrow while the whole length of its upper edge or crest seems rather wavy.

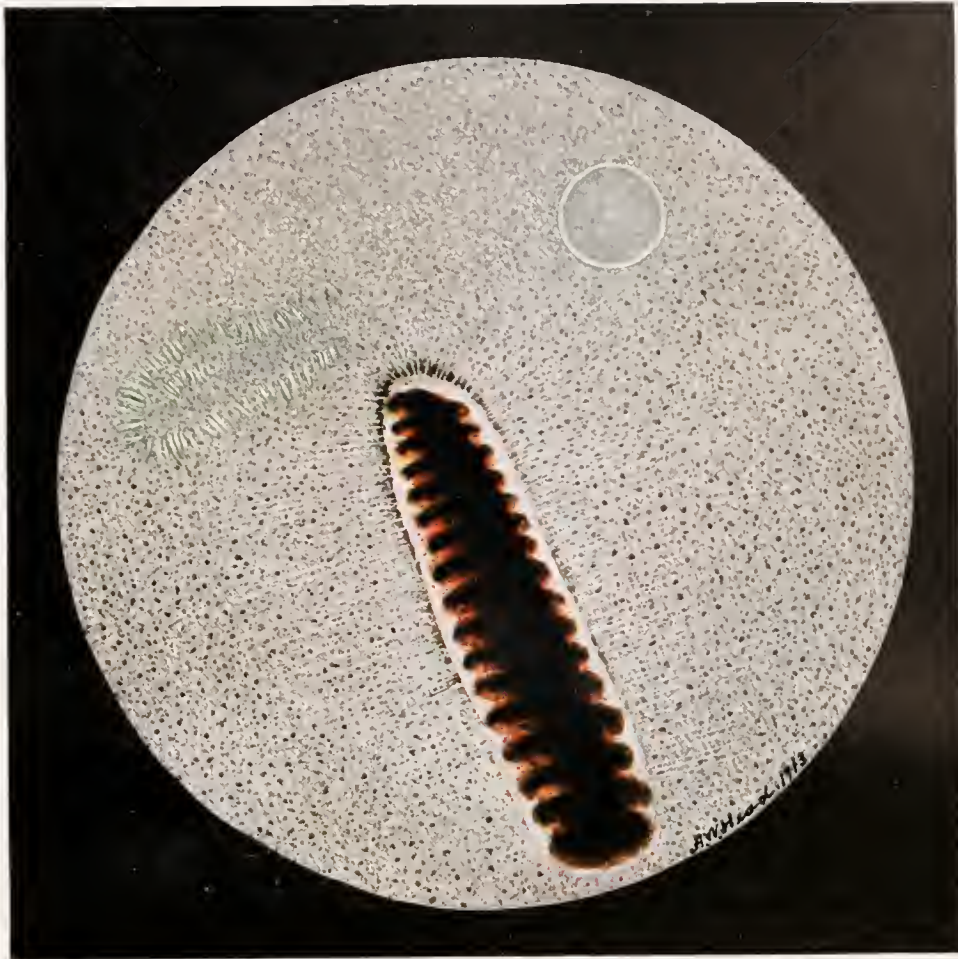Accipitriformes

LÄMMERGEIER. BEARDED VULTURE. *Gypaëtus barbatus*. Plate XXXII.

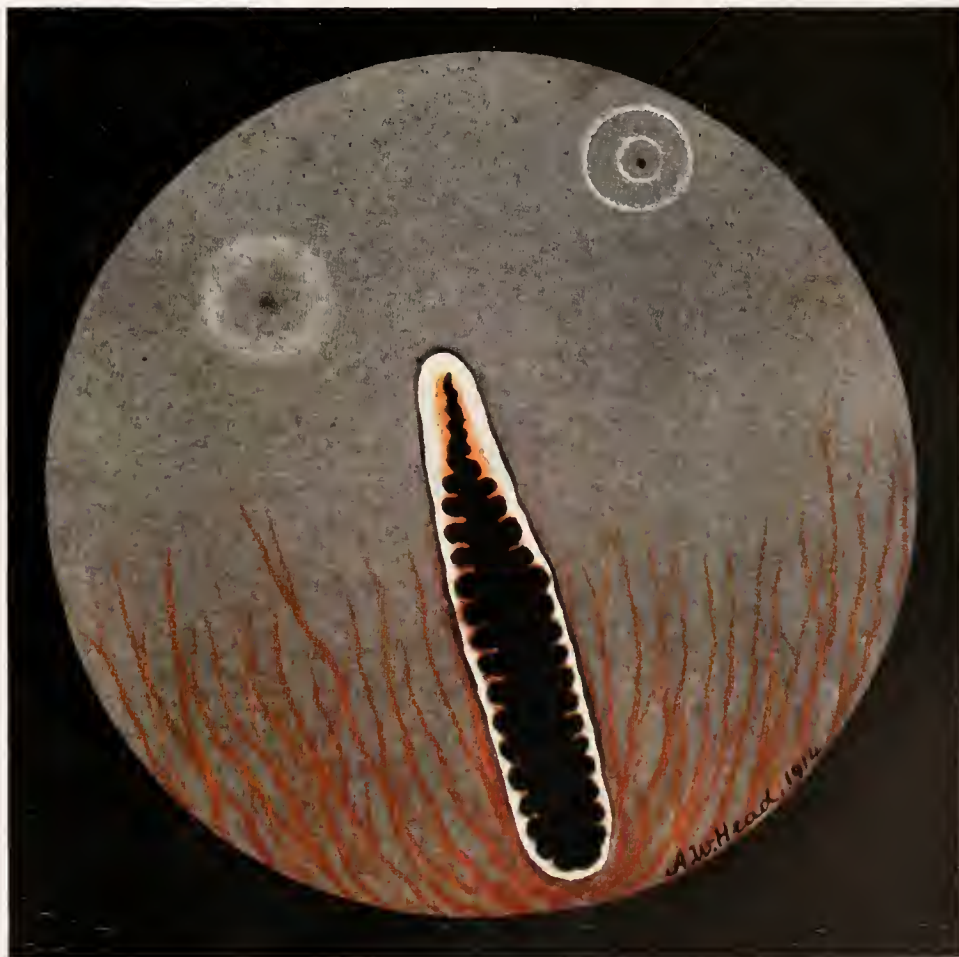The eyeground is slate-gray and presents everywhere a granular appearance. The lower half of the fundus is covered with dull orange-red choroidal vessels that run in a vertical direction, parallel to the sides of the optic disc.

Above the papilla (about two disc breadths from it on the nasal side) is a small, round, dark-brown pigmented pit, surrounded by two distinctly marked, brilliant reflex rings, each having a greenish tint. On the nasal side of the nerve-head, but nearer the latter and much less distinctly outlined than the depression just described, is the second macular region with its fovea. It has a soft, indistinct but dark centre. The optic entrance is pure white with an orange-red central area from which arises the pecten. This body is very narrow and tapers on its upper aspect for about one-fifth of its length. It then becomes much broader and almost covers the outer zone of the disc.

CARINATÆ



Serpentariiformes PLATE XXXI *Gypogeranus* vel *Serpentarius serpentarius*



Accipitriformes

PLATE XXXII

Gypaëtus barbatus

CARINATÆ

Accipitriformes

BALD EAGLE. *Haliaëtus leucocephalus*. Plate XXXIII.

The fundus is mostly a dark reddish-brown, the lower half changing to a dull orange-red. The lower eyeground is covered with choroidal vessels, and is dotted with brown pigment grains, giving it a rough, granular appearance. A gray sheen pervades the upper part of the fundus. On the temporal side and some distance from the upper end of the optic nerve is a brilliant, white, round dot surrounded by a small, light-green reflex ring, which is itself enclosed in a brilliant, narrow, green macular region. On the nasal side of the disc, and on a level with this macula is another area, of a gray color, surrounded by a fan-shaped, luminous reflex.

The optic nerve entrance is distinctly white, and along its centre is strewn a large number of minute pigment dots. The outer margin of the disk is bordered with black pigment, as if a shadow were cast upon it by the pecten.

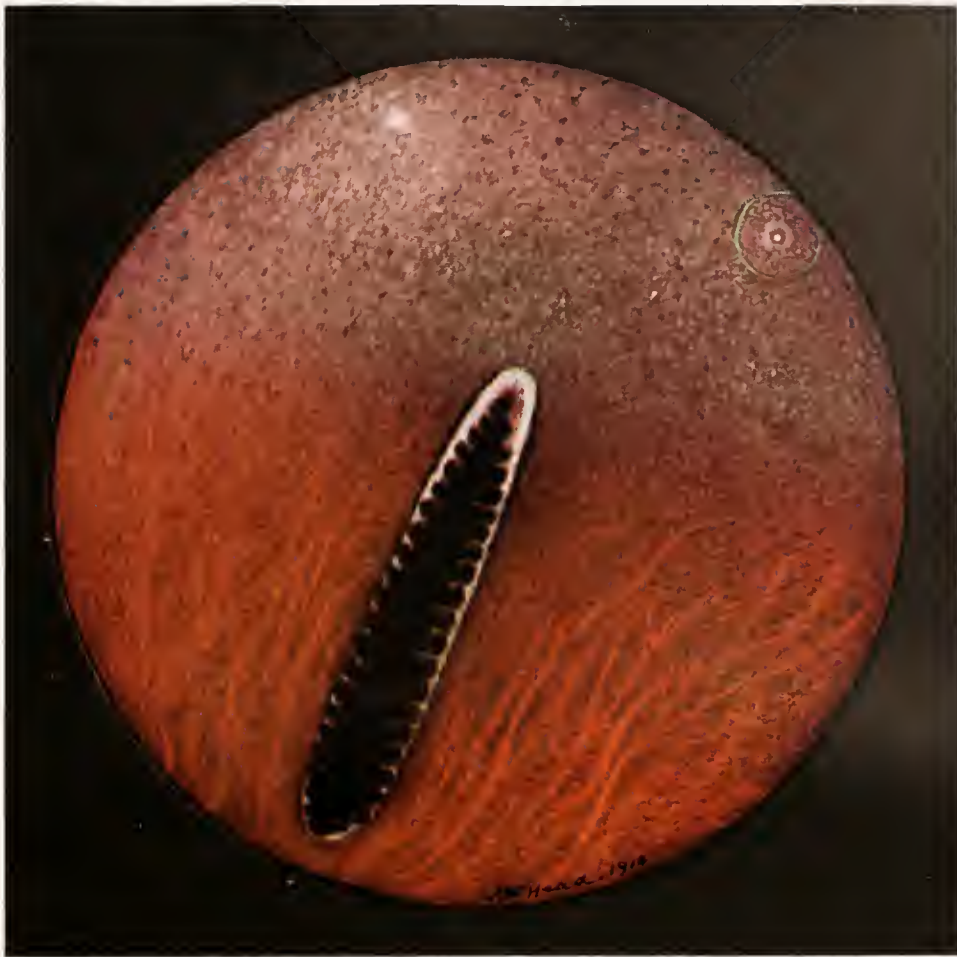WHITE-BELLIED SEA EAGLE. *Haliaëtus leucogaster*. Plate XXXIV.

The coloration of the eyeground is mostly dull-brown, the lower quadrants of the field being covered with dull, orange-red, choroidal blood-vessels. The disc is a long white oval, whose centre is tinted with orange and covered with tiny pigment dots. The papillary margins are white bordered with black pigment.

The upper half of the fundus is covered by a mass of dull gray dots. There is a well defined reflex near both maculæ.

The pecten is very large and comes well forward towards the posterior surface of the lens. Both extremities of the organ are clearly visible through the ophthalmoscope. There are very opaque nerve fibres to be seen in any part of the eyeground.

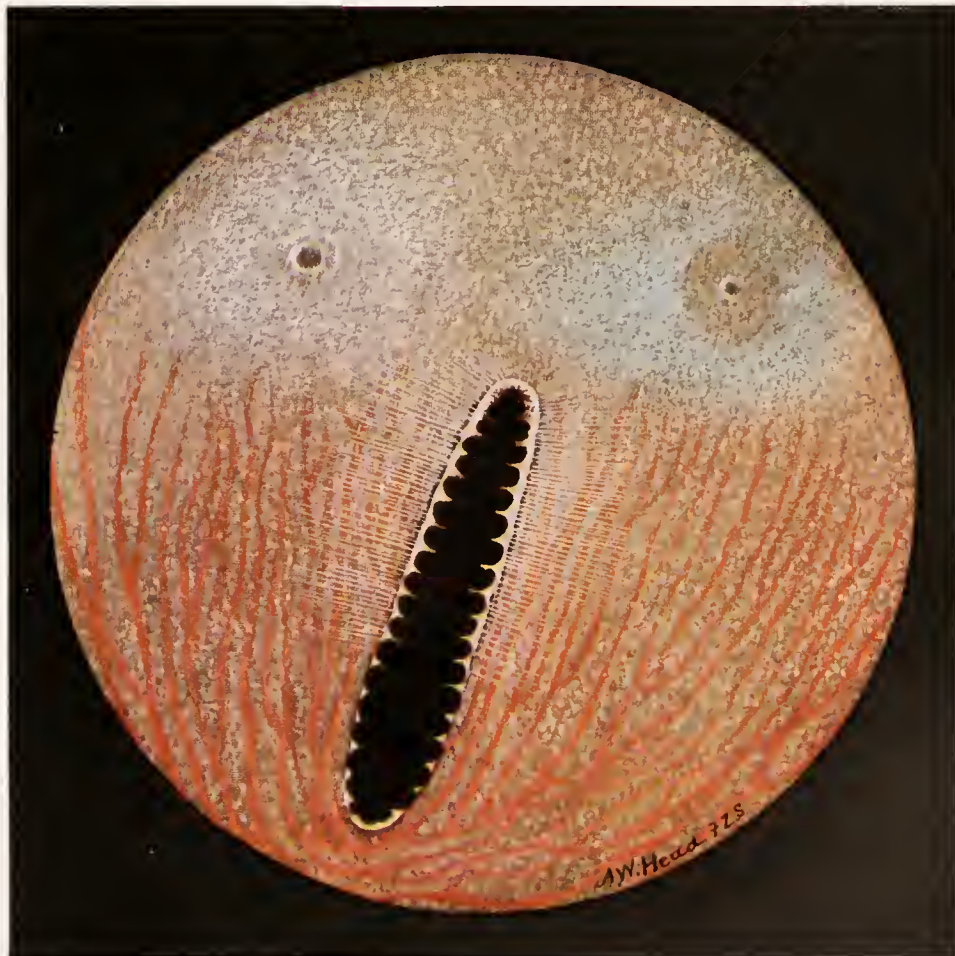CARINATÆ



Accipitriformes

PLATE XXXIII

Haliaëtus leucocephalus



Accipitriformes

PLATE XXXIV

Haliaëtus leucogaster

CARINATÆ

Accipitriformes

EUROPEAN KESTREL. *Tinnunculus alaudarius*. Plate XXXV.

The principal coloration of the fundus is a light brown, or brownish-gray. The lower quadrants are streaked with orange-red, choroidal capillaries that run in a more or less vertical direction, and become more distinct and brighter red as they approach the periphery of the field. The optic disc is a long, white oval, showing its margins well beyond the pigmented and fringed pecten. The central area of the papilla appears to be hollowed out like a canoe and the pecten does not overlap it at any point of its circumference, as is so frequently the case in avian fundi.

The disc extends as far downwards towards the fundal periphery as the observer's eye can reach. At its lower extremity several small choroidal capillaries can be seen.


The pecten has a rounded, pyramidal form, sloping towards the centre of the disc at both ends. It is of a dull brown color, and corrugated like a photographic camera. At the junction of pecten and papilla are scattered numerous brown dots, so disposed as to give the former the appearance of a web. The upper part of the eyeground is quite devoid of choroidal vessels, but is covered with minute white dots. The fundus is much clearer of the retinal shimmer or reflex noticed in most birds. The two macular regions are distinctly visible. The nasal macula is situated just above the upper end of the disc and about half a disc-length on the inner or beak side of the eyeground. It is a dark-brown spot with a pale area all around it. Outside of this region and enclosing it are two distinct, pale green filiform reflex rings, the interior rings being quite free from the white dots. On the outer aspect of the eyeground, about one-third the length of the disc above and two-thirds to the outer side of the disc, is the temporal macular region. At its centre is a light, gray spot surrounded by a dark brown area. Both these areas are in their turn encircled by a small, pale-green, reflex ring about one-fourth the diameter of the corresponding circle about the superior macula. Slender, opaque nerve fibres run out at right angles to the disc on both sides.

LITTLE BUSTARD. *Tetrax tetrax*. Plate XXXVI.

The fundal coloration is mostly a warm gray, covered with small, dull orange-red dots. In the lower half of the field and on each side of the optic nerve entrance is a number of choroidal vessels of a dull orange-red color, running parallel with the disc.

So far as seen the papilla is a dead white; optic fibres form a fringe-like setting about it. The central zone of the disc is covered by a mass of minute, brown, pigment deposits of irregular shape. Opaque nerve fibres extend at right angles to the disc on either side. A little to the temporal side, about one disc-length from the upper end of the optic nerve, is a small, brown spot like a tiny hole. This macular area is surrounded by a brilliant, green reflex ring. The pecten, of a dark chocolate-brown color and shaped like a corkscrew, comes well forward towards the inferior border of the lens.


CARINATÆ



Accipitriformes

PLATE XXXV

Tinnunculus alaudarius



Accipitriformes

PLATE XXXVI

Tetrax tetrax

CARINATÆ

Strigiformes

TAWNY OWL. *Syrnium aluco*. Plate XXXVII.

On the outer aspect of the papilla and about one disc-length from it on a level with the upper margin of the pecten, is a slight depression almost devoid of choroidal vessels. Its centre is a dark red color, and on the margins of the depression and surrounding it is a bright circular reflex. For some distance outside this foveal ring the eyeground is seen as if one were viewing it through a translucent, grayish mist or haze; and the fundus thus seen generally appears to be granular with a few, small choroidal vessels showing here and there. Inside the ring, however, the details are strikingly clear, and the coloration bright red. Above the macula, on the outer side of the disc, is a quantity of dark pigment deposited between the choroidal vessels, by contrast making the latter stand out as of a bright orange color. The inner aspect of the fundus appears yellow; it exhibits numerous choroidal capillaries whose yellow tint is distinctly brighter near the inferior segment of the disc.

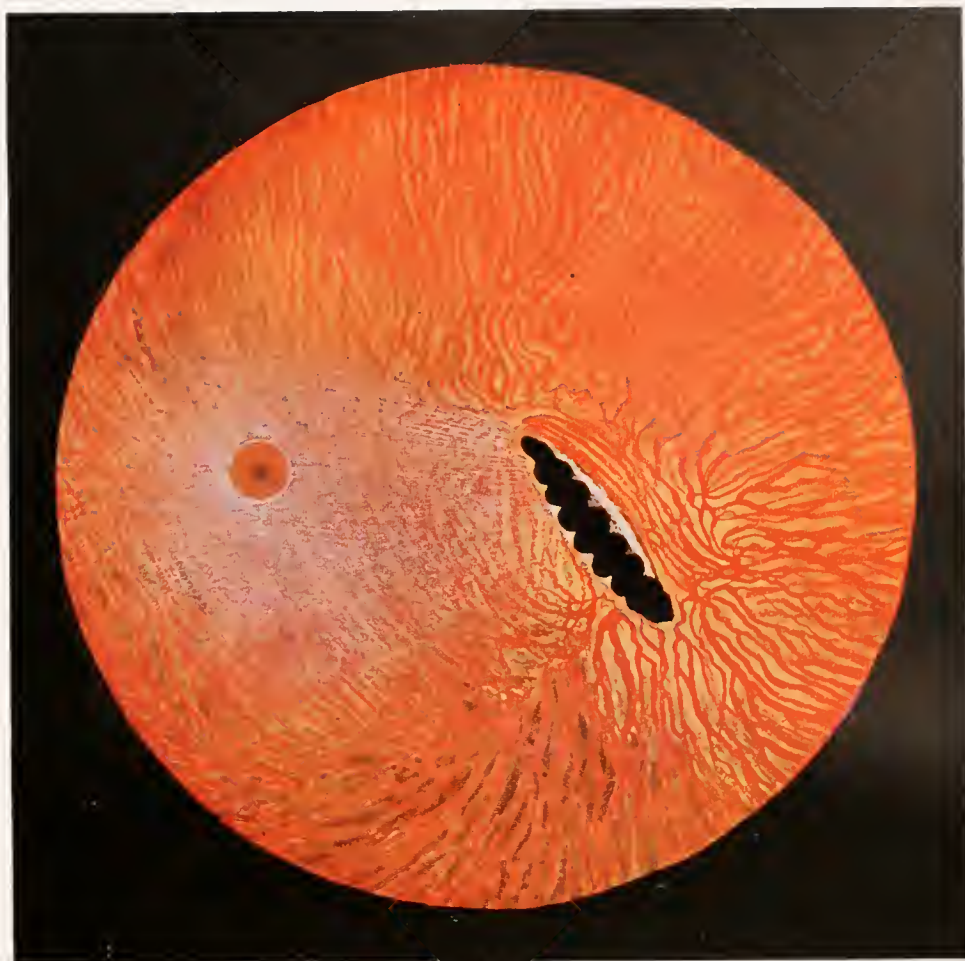COMMON BARN OWL. *Strix flammea*. Plate XXXVIII.

The general tone of the eyeground is dull gray, with bright orange-red choroidal vessels distributed all over the fundus except at the macular region. At this area the tint is much grayer, being, in addition, stippled with small, irregular blotches of orange-red and gray dots. The macula, also suffused with a deep gray reflex, is situated above the upper end of the optic disc and nearly in a line with the long axis of that organ.

The papilla is long and narrow with pointed ends, and apparently made up of coarse white fibre-bundles the central portion of which is covered with minute, brown, pigment grains, that have a distinctly reticulated appearance. These white fibres border the nerve head all around.

The dark-brown, convoluted pecten is large and extends well forward towards the lens. From both sides of the disc radiate a few, dull-gray fibres that stretch a short distance across the fundus and then disappear.

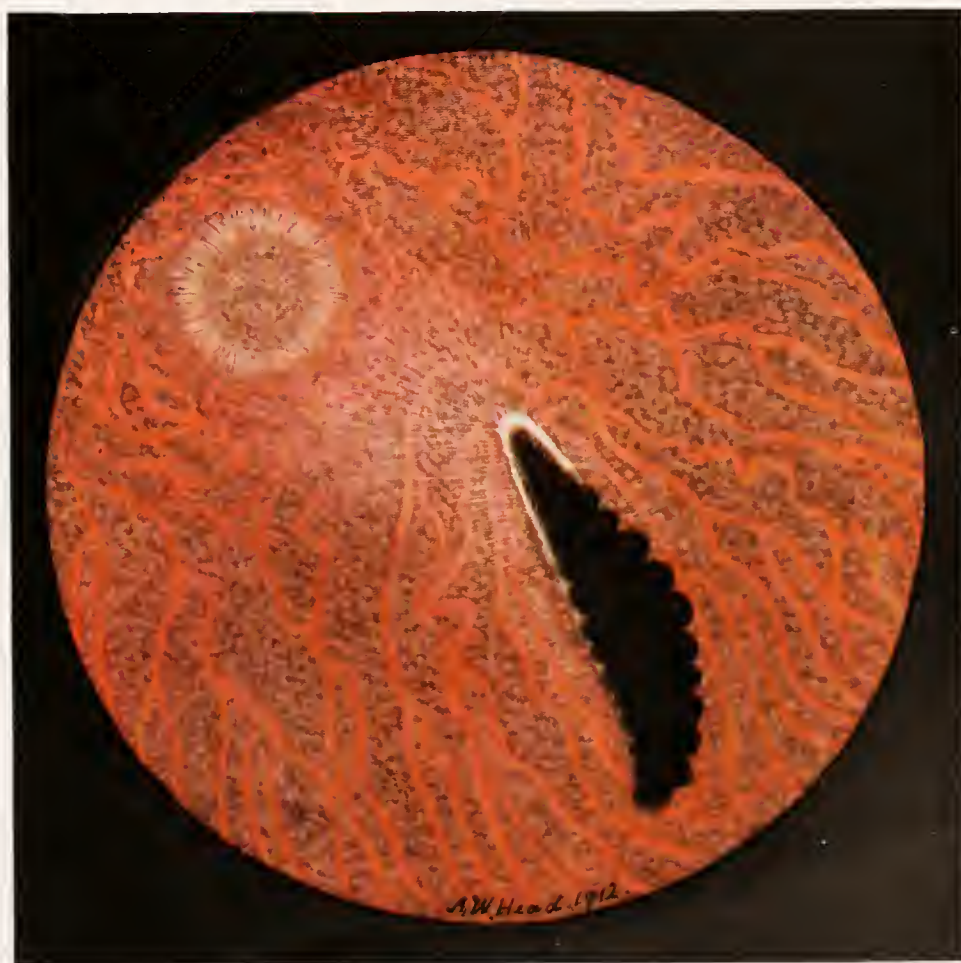CARINATÆ



Strigiformes

PLATE XXXVII

Syrnium aluco



Strigiformes

PLATE XXXVIII

Strix flammea

CARINATÆ

Psittaciformes

ORANGE-WINGED PARROT. *Chrysotis amazona*. Plate XXXIX.

The general color of the eyeground is a deep gray, tinted with buff. The lower sector and the peripheral zone are suffused with pink, the background generally being punctuated with minute, dull-yellow dots. The macular area is situated towards the nasal side of the disc, a little above the end of the pecten. It is slightly depressed and enclosed with a bright but pale green reflex-ring. Extending from the circumference of this circle, slightly above as well as below, are a few translucent fibres, pale green in tone; and at its centre is a dark-gray dot or depression, with a small, faint halo extending from its upper edge.

The optic nerve-head looks as if it were composed of coarse, white, opaque fibres, which form a fringe all around the deeply-colored pecten. The papilla is long and boat-shaped and its outlines can be traced the whole length of the pecten. Many fine, gray, opaque nerve fibres extend from the margin of the papilla, cross the background of the eye and are eventually lost in the fundal tissues.

The deep brown pecten, seen from above, has a spiral form, with a tag or tail-piece at the upper end. A lateral view shows it to be plicated, like a fan. It stands well forward towards the lens, especially its lower half. It has a dark brown color.

KAKAPO. Owl-Parrot. *Stringops habroptilus*. Plate XL.

The eyeground is orange-red stippled all over with lighter orange dots. The lower half of the fundus has a large number of minute dark, reddish-gray depots of pigment intermingled with lighter dots; also, a great many choroidal vessels run in a vertical direction over the field of view on either side of the optic entrance. They become more numerous towards its lower periphery.

The macula is placed, as in Owls generally, on the temporal side of the optic papilla, about one disc-length from its upper end and half that distance to the temporal or outer aspect of the fundus. It is a bright orange-red area surrounded by dark, red-gray pigment, like a shadow. There is no circular sheen around it, such as has been noted about other avian foveæ.

[The optic nervehead is white, and along its centre appears a network of minute, brown pigment dots clustering around the sides of the pecten. A few white opaque nerve fibres extend a short distance on either side and about the upper end of the disc.

The black-brown pecten extends the whole length of the disc. It is rather straight in its upper half but is more convoluted towards the lower part, where it is quite massive and resembles a corkscrew. It comes well more forward towards the lens, so that it more nearly resembles the same organ in the Burrowing Owl than in the Parrot.

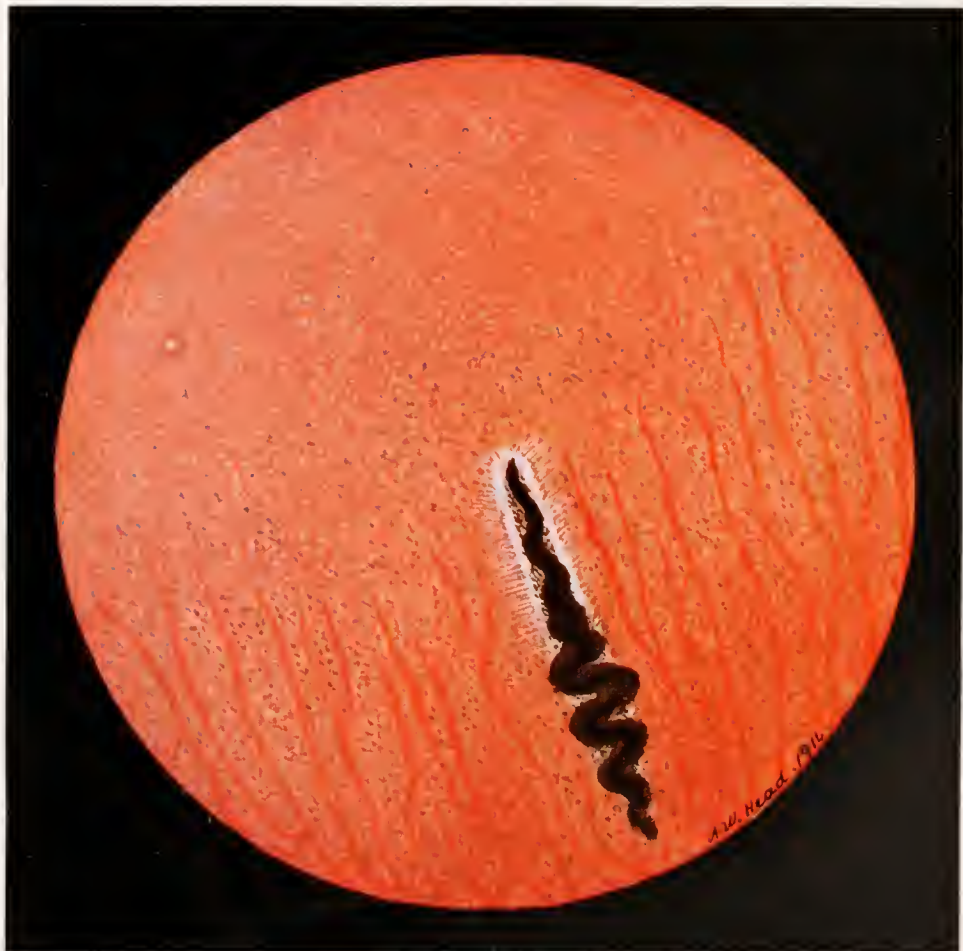CARINATÆ



Psittaciformes

PLATE XXXIX

Chrysotis amazona



Psittaciformes

PLATE XL

Stringops habroptilus

CARINATÆ

Psittaciformes

GREAT SULPHUR-CRESTED COCKATOO. *Cacatua galerita*.

Plate XLI

The background is of a fairly uniform, light, grayish-blue color, sprinkled with minute white dots interspersed with many less numerous but somewhat larger dark gray deposits. The macula, at the upper-inner quadrant, is an irregularly round, light brownish area whose diameter is half the disc length; and whose periphery fades into the surrounding gray of the fundus. The upper sixth of the long, pointed papilla is distinctly visible where it is not covered by the indented pecten, whose twelve double folds have a corkscrew termination above. Portions of the disc borders can be seen from above through the plications, except at its posterior terminal, where the dark-brown mass entirely covers it. Faint, whitish lines of opaque nerve fibres extend from the margins of the upper half of the disc a short distance across the centre of the eyeground.

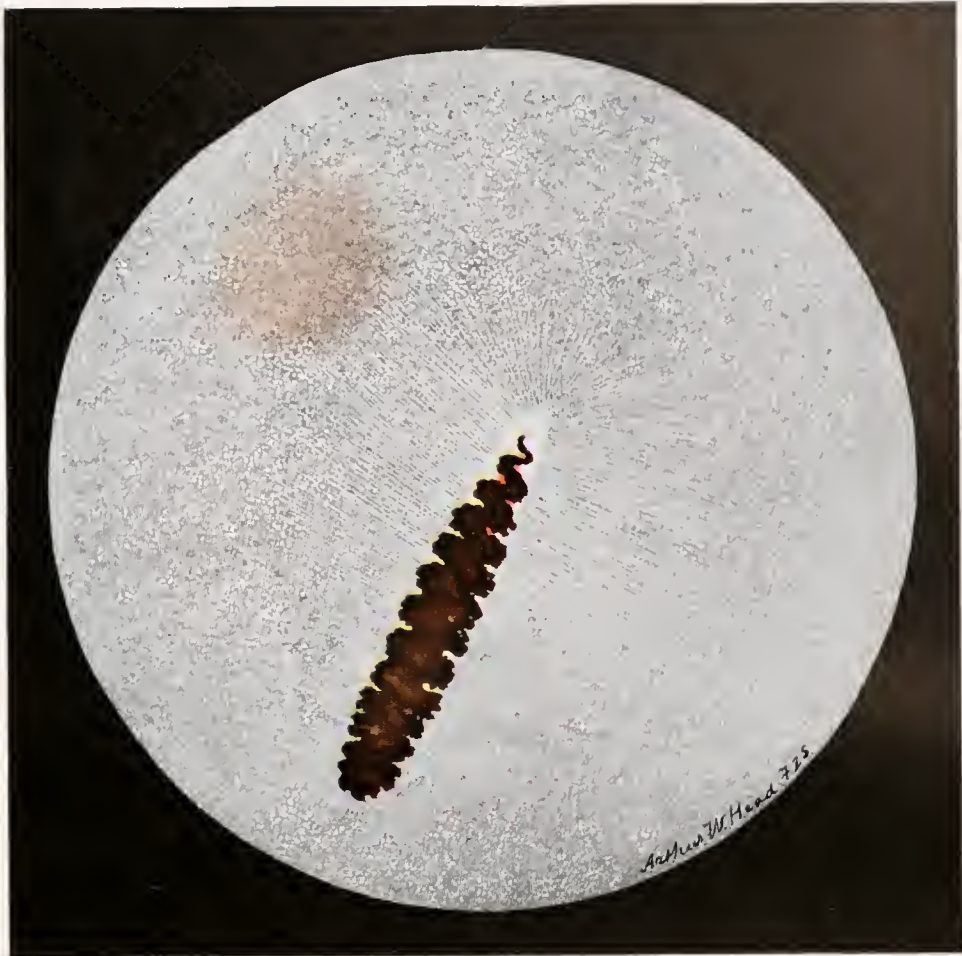
Coraciiformes

LAUGHING KINGFISHER. *Dacelo gigas*. Plate XLII.

The fundus oculi is in general of a light fawn-gray color mingled with irregularly shaped white or gray-white dots, except in the neighborhood of the optic nerve where it is orange-red, like the glow cast on the sky by the setting sun. The optic nerve entrance is long and narrow; it is white except along its central area, which is orange-red striped with brown pigment dots. A large number of opaque nerve fibres run out on each side of the optic nerve and at right angles to it. The pecten is very long and narrow and has the appearance of a brown centipede.

The macula is very conspicuous. About half a disc-length from the upper end of the nerve, towards the nasal side, is a small, round, dark depression, surrounded by a very narrow, bright green ring. This circle encloses a smaller area that is of a darker gray and devoid of the dots seen at other parts of the eyeground. The fovea nasalis always appears directly opposite the pupil; there is no fovea temporalis visible to the ophthalmoscope.

CARINATÆ



Psittaciiformes

PLATE XLI

Cacatua galerita



Coraciiformes

PLATE XLII

Dacelo gigas

CARINATÆ

Coraciiformes

BLACK HORNBILL. *Spagolobus adratus*. Plate XLIII.

The principal color of the eyeground is dull gray, interspersed for some distance about the optic nerve entrance with a mass of fine opaque fibres that extend about a disc-length over the fundus. Beyond the fibres are several dull-colored choroidal capillaries that cross the fundal field in a vertical direction. Near the macular region the fundus is illuminated by a brilliant gray iridescence.

The optic disc is a long, white oval, that extends downward and a little inward towards the inner or beak side of the head. The pecten is very large, the lower segment being carried far forward behind the iris; it presents serrated margins.

The macular region is quite circular and is red-brown in color. An inner circle is dead white, while the foveola is represented by a dark-red central spot. There are two bright rings around the macula of an iridescent, blue-green color, the fundus between the two circlets being a light luminous gray.

EUROPEAN NIGHTJAR. *Caprimulgus europæus*. Plate XLIV.

The eyeground appears orange-red, everywhere stippled with small, red and brown patches of irregular shape. Scattered about are several pigmented areas, such as one sees in the eyes of human subjects with disseminated choroiditis. There are a few choroidal vessels in the lower half of the fundus. These are faintly outlined, but they give to that part of the eyeground a deeper red than the remainder of the background.

The optic papilla is short and broad. The antero-posterior view with the mirror shows it as a dull, grayish-white body largely covered with brown pigment dots. Its margins, where it is not obscured by the mass of the pecten, is much lighter in color. Radiating from the sides of the disc, and extending for a short distance on either side, are a few white, opaque nerve fibres, which are light gray and become less distinct on the outer side of the papilla.

CARINATÆ



Coraciiformes

PLATE XLIII

Spagolobus adratus



Coraciiformes

PLATE XLIV

Caprimulgus europaeus

CARINATÆ

Cuculiformes

EUROPEAN CUCKOO. *Cuculus canorus*. Plate XLV.

The eyeground is gray with a suggestion of fawn, everywhere besprinkled with grayish-white dots. Towards the lower quadrants of the fundus, in particular at the extremity of the pecten, the background is suffused with a dull pink. Near the optic nerve on either side are several, plainly visible, orange-red choroidal vessels.

The macula is seen above the disc towards the nasal side. This area, slightly red in tone, appears depressed below the fundal surface, although no definite fovea is visible with the mirror.

The papilla is almost completely covered by the pecten so that only the outlines of the former can be seen by the anterior-posterior inspection of the ophthalmoscope. Where the papillary margin is visible it shows extremely white.

The pecten also extends well above and below the disc terminals and projects deeply into the vitreous chamber. It appears by the mirror to be a chocolate-brown color. Opaque nerve-fibre radiations are seen to originate at the disc margins, whence they cross the background and finally disappear from view at or near the fundal periphery.

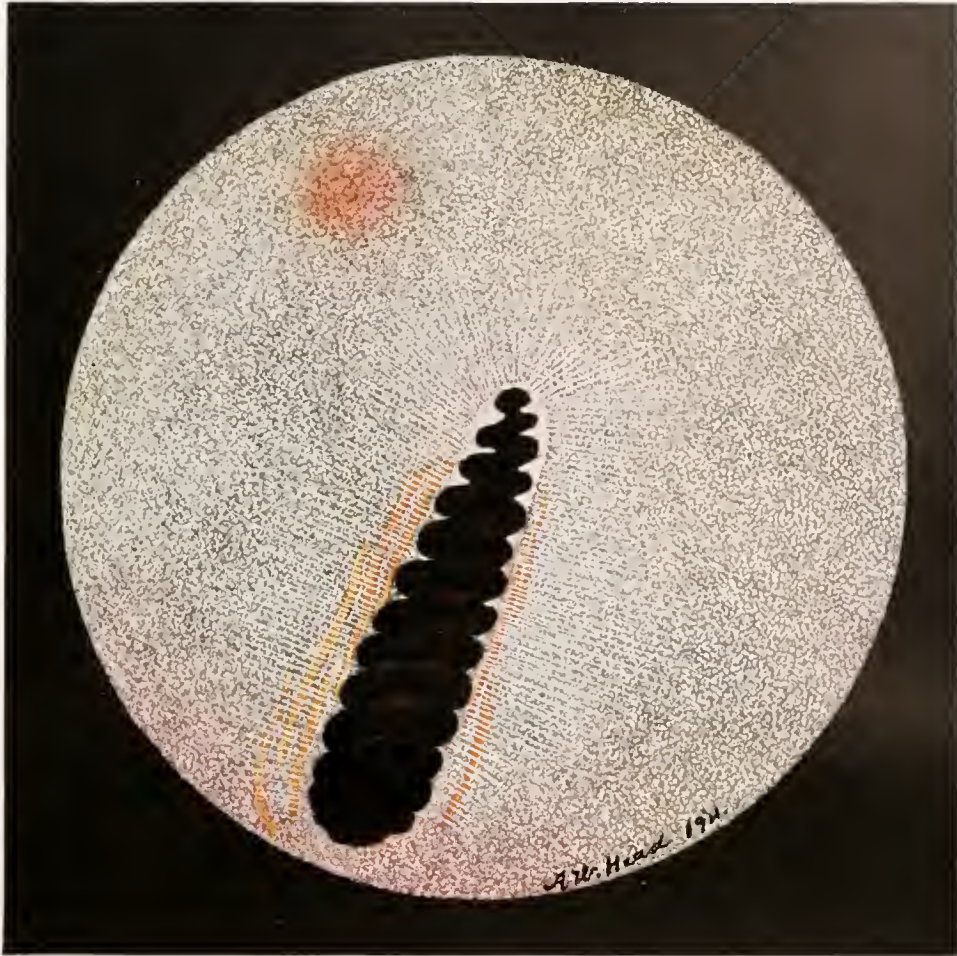
Piciformes

SULPHUR-BREASTED TOUCAN. *Rhamphastus lamatus*. Plate XLVI.

The eyeground is dull gray in color, rather regularly spotted with whitish-gray dots. The optic papilla is apparently composed of short, coarse, white fibres which form a sort of fringe all round its margins. Along each of its sides and parallel to its long diameter a few orange-red, choroidal vessels are seen. Radiating from the papillary circumference are numerous opaque nerve fibres that extend to the fundal periphery across the eyeground on all sides. The pecten is almost black-brown in color.

Above the end of the optic nerve entrance and about half its length to the nasal side are three dark-brown spots, clustered together and surrounded by a small gray reflex.

CARINATÆ



Cuculiformes

PLATE XLV

Cuculus canorus



Piciformes

PLATE XLVI

Rhamphastus lemnatus

CARINATÆ

Piciformes

GILA WOODPECKER. *Centurus uropygialis*. Plate XLVII.

The fundus oculi is dull gray tinted with yellow and nearly uniformly charged with minute, gray dots. At the superior termination of the optic disc (on the nasal side) is a small gray depression, partly surrounding a central, well-marked and glistening white dot. Within this area are also several golden yellow dots.

The outlines of the optic nerve entrance are well defined, and the central area of the papilla at its union with the pecten is dull orange stippled with dark brown pigment. The papilla is fringed with coarse white fibres. A large number of translucent nerve fibres radiate from the edge of the optic disc on all sides; they become fainter and fainter as they approach the fundal periphery and finally disappear.

The pecten, of the usual chocolate brown color, reveals several corkscrew convolutions. It comes well forward towards the lens, and presents a massive, club-shaped appearance.

GREATER SPOTTED WOODPECKER. *Dryobates vel Dendrocopus major*.
Plate XLVIII.

The color of the eyeground is a dull but definite gray, interspersed with a large number of small, gray dots. Below the optic disc and pecten are a few faint, orange-red choroidal vessels. The optic disc is apparently made up of a mass of brilliant, white, nerve fibres, very short and thick. In the form of radiations from the margins of the papilla towards the fundal periphery are many gray opaque nerve fibres that appear to occupy a plane lower than the white elements of the disc. The pecten has three corkscrew convolutions on the disc, while its lower part forms a club-shaped mass of a deep chocolate-brown color that appears to come well forward towards the lens.

There seems to be only one sensitive central area. This single macula is on the nasal side of the pecten and has the appearance of a brilliant, white, round dot, the fundus surrounding it being a little darker than the general color of the eyeground. The surrounding gray area makes the white fovea stand well forward almost as if it were actually situated in the vitreous. No reflex ring can be seen around it.

CARINATÆ



Piciformes

PLATE XLVII

Centurus uropygialis



Piciformes

PLATE XLVIII

Dryobates rel Dendrocopus major

CARINATÆ

Passeriformes. A. MESOMYODI. *Tyrannida*.

DERBY TYRANT. *Pitangus derbianus*. Plate XLIX.

The eyeground is blue-gray, everywhere sprinkled with minute, gray dots. These dots are so closely packed on the upper half of the fundus that they give it a distinct silvery appearance. Running at right angles to either side of the optic papilla are numerous dull-white opaque nerve fibres; they extend well across the eyeground. At right angles to the optic disc towards the nasal side and a little above its superior end is a dense, pale-blue, punctate mass that appears to surround the fovea. A light blue reflex ring also encircles this area.

The optic nerve-entrance is long, narrow and white. Its centre is stippled with a few brown pigment dots and it is bordered all around with symmetrically placed black pigment granules. This pigmented margin varies a little in individuals. The black-brown pecten, long and narrow, extends well behind the edge of the pupil so that a portion of it cannot be seen through the mirror. The upper part is serrated but the lower half is more of the corkscrew type.

Passeriformes. B. ACRYOMODI. *Hirundinida*.

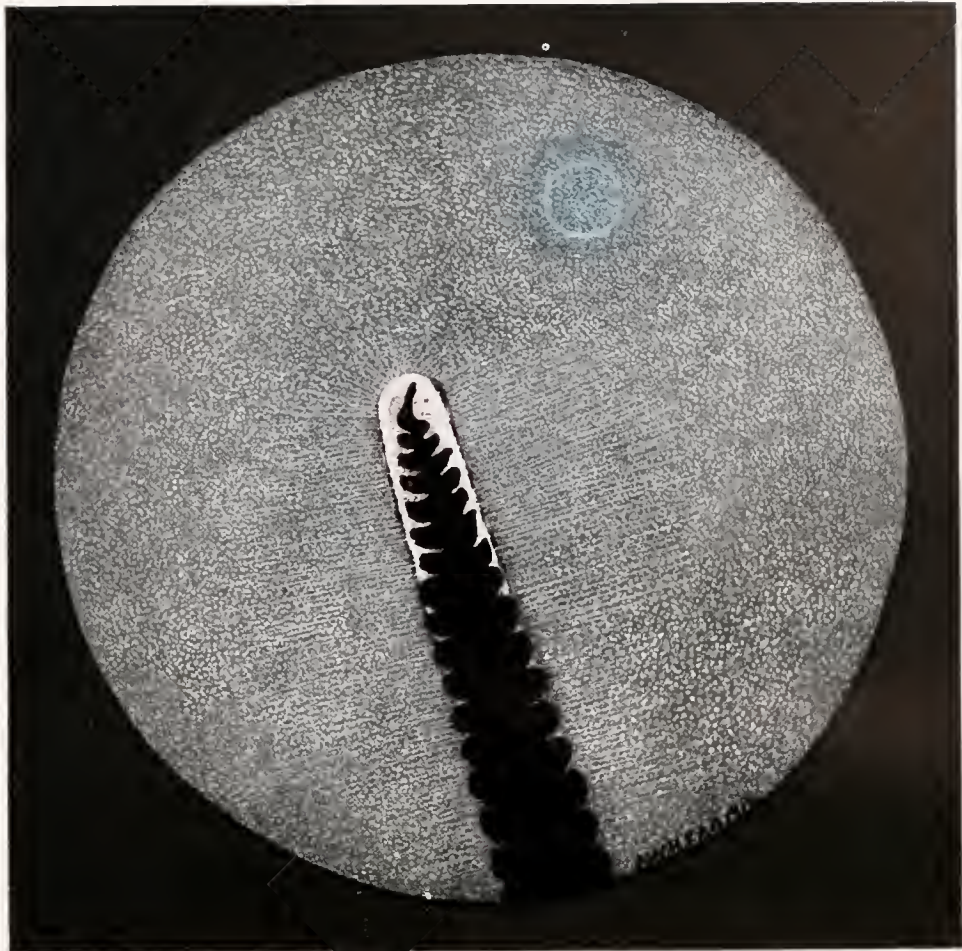
EUROPEAN CHIMNEY SWALLOW. *Hirundo rustica*. Plate L.

The general color of the eyeground is warm gray, tinted slightly with yellow or buff, and covered with minute, dull, yellowish dots. Several pale orange (choroidal) vessels are seen near the upper extremity of the optic nerve-entrance. There are visible two macular regions, one on each side of and above the upper end of the disc. They show as small brown areas or dots in the eyeground. Surrounding the temporal macula is a slight reflex, apparently composed of minute, bright gray dots. The macula on the nasal side is quite devoid of this reflex-ring.

The optic papilla, long and narrow, tapers at its upper end. On either side of the disc, and at right angles to it are a few, fine, dull-gray opaque nerve-fibres.

The chocolate-brown, convoluted pecten is quite narrow at its junction with the optic nerve, but it gradually becomes wider and more massive as it approaches the lens.

CARINATÆ



Passeriformes

PLATE XLIX

Pitangus derbianus



Passeriformes

PLATE L

Hirundo rustica

CARINATÆ

Passeriformes. *B. Turdida*.

BLUEBIRD. *Sialia sialis*. Plate LI.

The general blue-gray coloring of the eyeground is modified by numerous, pin-point dots. The punctate deposits near the periphery assume a more or less dull-golden or orange tint, a condition also noticed just below the pecten. The elongated, ovoid optic disc is white (quite woolly at its margins) and covered almost entirely with the convoluted pecten, which is very large when compared with the size of the eye. It is of the usual dull-brown color and has "frilled" borders. On the inner or nasal side and near the lower part of the optic disc is an orange-red area, containing chiefly choroidal vessels with black pigment grains between them. This red area extends a little to the temporal side of the disc, subsequently merging into the dull orange color below. On either side of the disc and radiating from it, are numerous filiform nerve fibres which cross the background almost to its periphery. In an area a disc-length to the nasal side of the papilla the white dots of the fundus are decidedly fainter and much closer together than elsewhere; in this region, also, there is a reflex plainly marked.


WHEATEAR. *Saxicola arnanthe*. Plate LII.

The fundal coloration is pale gray, with a dense mass of grayish white dots permeating the entire background. Slightly above the upper termination of the optic nerve, and towards the nasal side of the pecten, is a well-defined, round, whitish macular region, much larger than the small spots that cover the whole of the surrounding, duller eyeground. This white area is inclosed by a brilliant, bluish-green circle, which appears more prominent and iridescent in nature than is depicted in the drawing. The optic papilla is almost entirely obscured by the pecten; it is long and narrow, with an irregular outline.

On the nasal side of the nerve-head are a few short, orange-red, choroidal vessels with a few dots of pigment like pepper grains sprinkled between them. Extending from both margins of the optic disc across the fundus to the periphery, are numerous fine, opaque nerve fibres, the upper ones (on the nasal side) terminating at the macular area.

The pecten, red-brown in color, long and narrow, appears to be twisted on itself like a rope or a corkscrew. Its inferior end extends beyond that part of the eyeground shown in the picture, but it probably comes well forward towards the posterior surface of the lens.

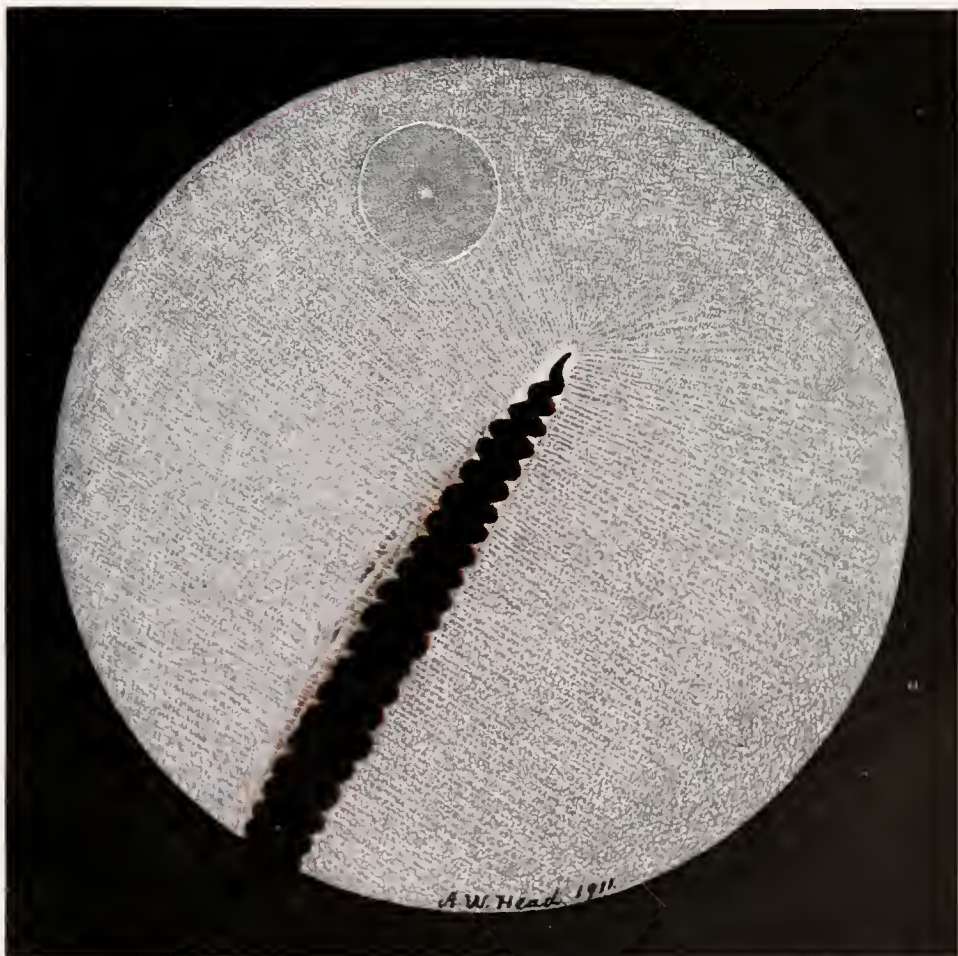CARINATÆ



Passeriformes

PLATE LI

Sialia sialis



Passeriformes

PLATE LII

Saxicola ænanthe

CARINATÆ

Passeriformes. B. *Fringillidæ*.

HOUSE SPARROW. *Passer domesticus*. Plate LIII.

The general color of the fundus is pale-gray covered with very fine white dots, closely packed together at the macular area. They form a lighter zone a little above the upper extremity of the pecten and towards the nasal side of the disc. From the circumference of the optic disc a large number of rather long, opaque nerve fibres run in radial fashion towards the periphery of the fundus. The papilla appears, when visible, to be composed of irregularly shaped, brilliant white bundles; it can barely be outlined with the mirror except at the upper (and narrow) end of the pecten. The pecten has a deep red-brown color, and its free extremity is long, narrow and of the corkscrew type. The lower segment of the organ extends well forward towards the lens and, being large and massive, completely covers the pupil and makes it impossible to obtain a lateral view.

VARIED BUNTING. *Cyanospiza versicolor*. Plate LIV.

The *eyeground* is dull gray shaded to buff and besprinkled with very minute, grayish-white dots. These dots coalesce at the macula, where they form a soft, round area bordered by a light reflex. The single macular region and fovea are situated a little above the upper end of the pecten and towards the nasal side of the optic nerve. The pecten, very large and massive for the size of the eye, is of the usual chocolate-brown colour; it is more or less club-shaped, and extends well forward towards the lens. Where the pecten joins the retina it is very irregular in shape. The pecten, whose outline is quite irregular, covers the papilla entirely so that it appears to spring directly from the retina without showing the white disc margin. From the sides of the apparent root of the pecten a few, whitish, opaque nerve fibres cross the field of view.

CARINATÆ



Passeriformes

PLATE LIII

Passer domesticus



Passeriformes

PLATE LIV

Cyanospiza versicolor

CARINATÆ

Passeriformes. *B. Paradiscida*.

LAW BIRD OF PARADISE. *Parotia lawii*. Plate LV.

The eyeground is yellowish-gray or khaki color, uniformly covered with a dense mass of minute white dots, that are smaller and denser at the macular region. A few dull-red choroidal capillaries are visible on the lower part of the fundus near the periphery. The optic nerve head, dull white, long and narrow, has a rounded upper end. Its entire central area appears as if it were a mass of fine, brown pigment dots. The pecten is exceptionally long, rather narrow, spirally arranged and extends beyond the range of vision through the undilated pupil.

To the nasal side and a little above the end of the disc is the macular region, a dull-brown crater-like depression bounded by a white mass of (reflex) striations. Opaque nerve fibres radiate from both sides of the disc but finally disappear as they approach the boundaries of the fundus.

B. Corrida.


BLUE JAY. *Cyanocitta cristata*. Plate LVI.

The general color of the eyeground is a slate-gray, with a pale-yellow tint in the lower half of the eyeground. The entire field is besprinkled with irregularly shaped, light-gray dots, giving it the appearance of a rough and rather coarse surface, especially near the macular area where the dots are more closely packed in the shape of a bright, circular patch.

The optic nerve-head is quite white and of oblong shape. Several orange-colored, choroidal capillaries are visible in this region, that is covered with minute, brown, pigment dots, like black pepper grains. Extending from each side of the optic disc is a large number of opaque nerve fibres that extend across the fundal field.

The pecten, of the usual chocolate-brown color, is rather irregular in shape at its superior extremity. From above downward it looks like a ship's tarred cable, becoming larger as it approaches its union with the papilla. The superior end appears to come well into the vitreous cavity and to reach the lens.

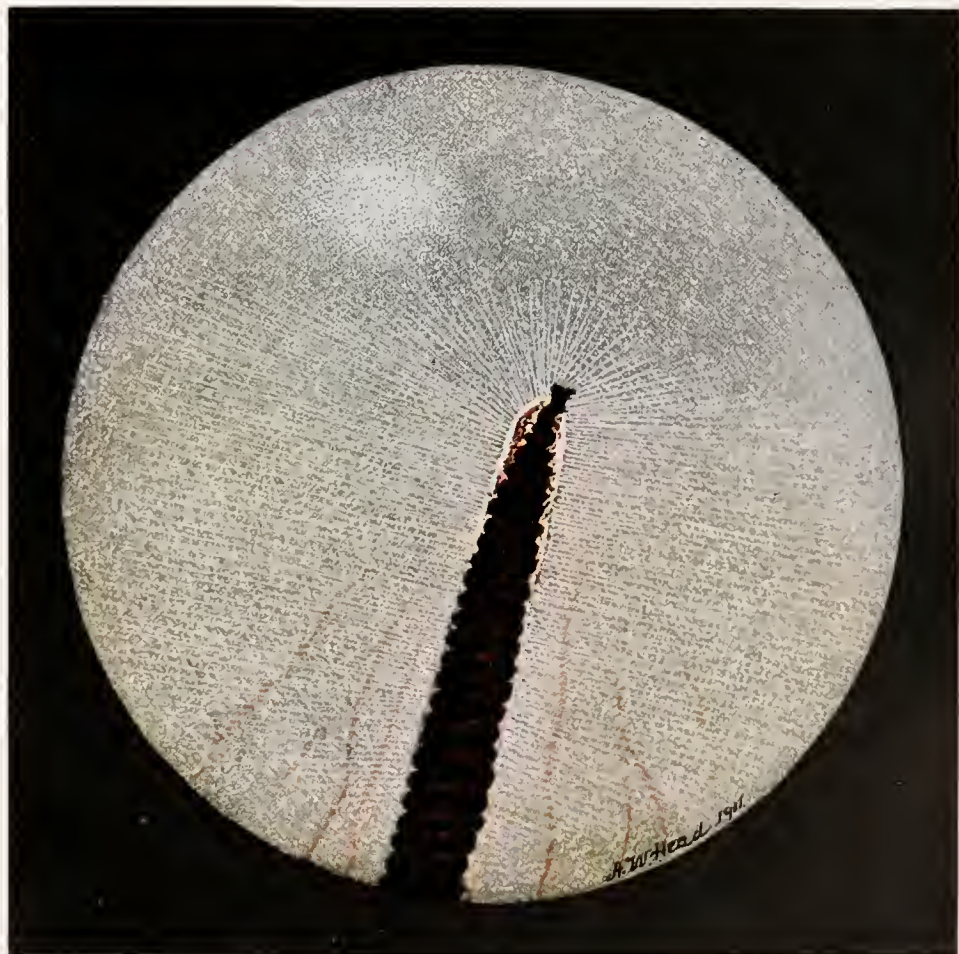
CARINATÆ



Passeriformes

PLATE LV

Parotia larrii



Passeriformes

PLATE LVI

Cyanocitta cristata

CARINATÆ

Passeriformes. *B. Corvidæ.*

COMMON BRITISH BLACKBIRD. *Turdus merula.* Plate LVII.

The general tint of the eyeground is a slaty-gray with a uniform sprinkling of tiny, white dots. There is no visible macular region, but the whole fundus is covered and its coloring greatly modified by numerous linear opaque fibres that arise from the disc margins throughout and run across the entire fundus to the extreme periphery. A few, faint, yellow-red choroidal vessels are seen on either side of and parallel to the moderately long and narrow papilla. The upper two-thirds of the disc is about half covered by the club-shaped pecten, which is composed of very few folds. The massive, chocolate-colored, posterior end of the pecten entirely obscures the lower third of the disc, while the upper half of the former has a light brown margin on its nasal aspect, and seems to be only in part attached to the nerve-head beneath it.

RAVEN. *Corvus corax.* Plate LVIII.

The eyeground is a light fawn sprinkled with dots about three shades darker than the ground color. Mixed with the dark dots are a number of white ones, seen especially when a strong light is thrown upon the fundus. About three disc-breadths from the upper end of the disc on the inner side is a well marked, bright reflex of a greenish-blue tinge. It is irregularly oval in shape and seems to be composed of a number of very fine fibres. In the centre of the reflex is the macula, a small, dark, crater-like depression, brown in color. The disc is chalky white, and gives one the impression that it is composed of many opaque nerve fibres packed closely together. From the disc margins there radiate a number of fine optic nerve fibres that extend across the eyeground. In the lower part of the fundus, associated with a number of orange-red dots, are a few orange-red choroidal blood-vessels, several of the latter being distributed along either side of the disc. The pecten is very thin and narrow at the disc but assumes a club-shape as it approaches the lens, where it is darker in color. It comes well forward and appears at times to press against the posterior capsule of the lens.

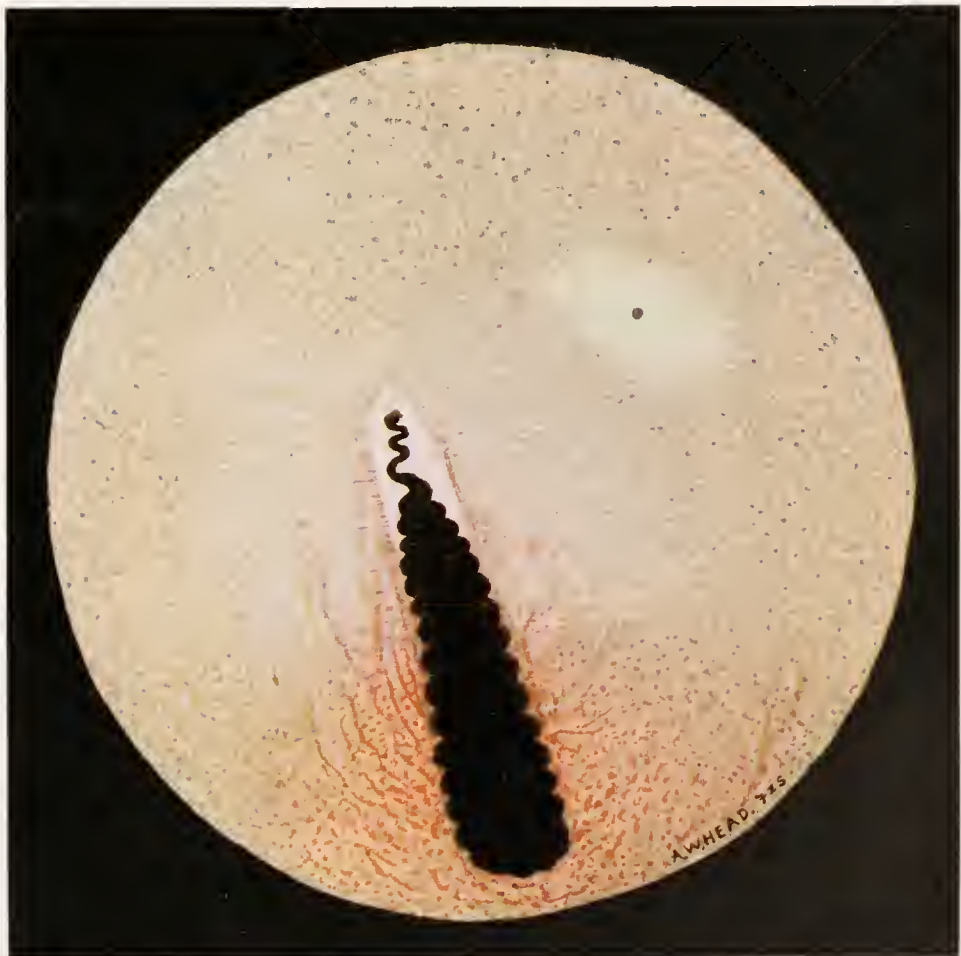CARINATÆ



Passeriformes

PLATE LVII

Turdus merula



Passeriformes

PLATE LVIII

Corvus corax

COLORED DRAWINGS OF THE FUNDUS OCULI OF
REPTILES.

REPTILIA

TURKISH GECKO. *Hemidactylus turcicus*. Plate LIX.

The orange-red fundus is uniformly dotted with dark spots, while the circular papilla is completely obscured by the chocolate-brown pecten, whose pointed free end projects a medium distance into the vitreous. Clearly defined, white linear medullated nerve-fibres radiate from the disc margins, giving the effect of a halo about the central zone of the picture.

HORNED TOAD. *Phrynosoma cornutum*. Plate LX.

The general coloration of the eyeground is a dark slate, irregularly strewn with minute, whitish dots of various sizes. There is an ill-defined macular region. The pear-shaped, grayish papilla has a white margin, from which short fibres of unequal length radiate towards the periphery. A single central (?) artery seems to originate from the nerve-head and with its six branches — two on one side of the disc, four on the other — is supplied mostly to the lower half of the field. A small branch anastomoses above with a twig that runs from the periphery of the fundus.

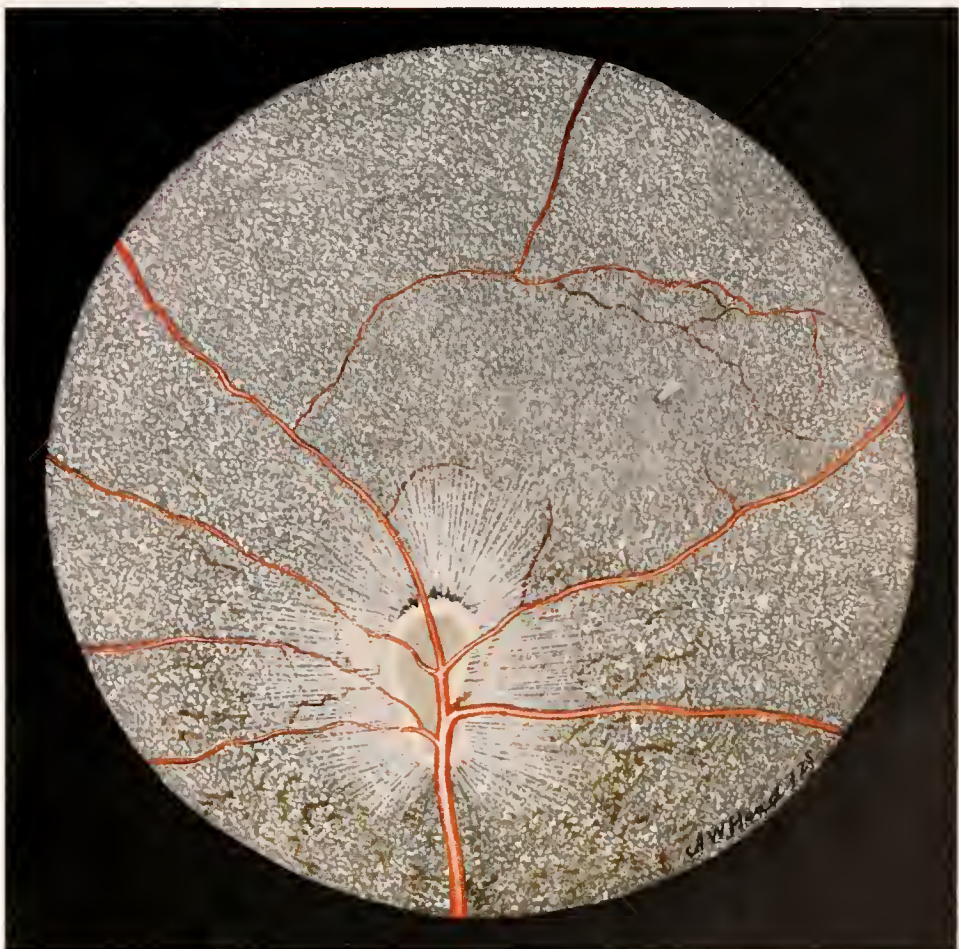REPTILIA



Turkish Gecko

PLATE LIX

Hemidactylus turcicus



Horned Toad

PLATE LX

Phrynosoma cornutum

REPTILIA

INDIAN COBRA. *Naja tripudians*. Plate LXI.

The general coloration of the fundus oculi in this Snake is light gray-blue, sparsely dotted with pigment of a similar but deeper color. The whole background is regularly covered with opaque nerve fibres. From the button-like optic disc arise three vessels, apparently two arteries of small size and one larger vessel — probably a vein. The centre of the papilla shows the remains or the undeveloped tissues of a pecten.

REPTILIA



Indian Cobra

PLATE LXI

Naia tripudians

